

## Accuracy in frozen section diagnosis of thyroid nodules

Thiwaporn Thesawadwong\*

Somboon Keelawat\*

Thesawadwong T, Keelawat S. Accuracy in frozen section diagnosis of thyroid nodules. Chula Med J 2003 Oct; 47(10): 631 - 40

- Background** : *The accuracy of frozen section in the diagnosis of the thyroid nodules varies in different institutes. There has been argument on the usefulness of this procedure in thyroid surgery. At King Chulalongkorn Memorial Hospital, frozen section is routinely used to evaluation thyroid lesions; however, no study on the accuracy of the test has ever been done.*
- Objective** : *To assess the value of frozen section in the diagnosis of thyroid nodules.*
- Setting** : *Department of Pathology, Faculty of Medicine, Chulalongkorn University.*
- Study design** : *Descriptive study (diagnostic test).*
- Subjects** : *One hundred and twenty-eight cases of thyroid pathological specimens submitted for frozen sections at King Chulalongkorn Memorial Hospital during January 2000 to November 2002.*
- Methods** : *Diagnoses of frozen and paraffin section of all 128 patients were studied and pathological reports recorded in the files of the Department of Pathology reviewed. The results were calculated for statistic values.*
- Results** : *Frozen section diagnoses of the thyroid lesions at King Chulalongkorn Memorial Hospital revealed to have 84 % sensitivity; 98.6 % specificity; 95 % accuracy; 95.5 % positive predictive value; 94.8 % negative*

\* Department of Pathology, Faculty of Medicine, Chulalongkorn University.

*predictive value; 1 % false positive and 4 % false negative. The one false positive case was follicular adenoma which was incorrectly diagnosed as follicular carcinoma by frozen section. The four false negative cases included: 3 cases of papillary carcinoma and 1 Hurthle cell carcinoma. All of them were diagnosed of benign by frozen specimens. The deferral rate is 23.4 %. The most frequent deferred lesions were follicular adenoma (43.3 %)*

**Conclusion** : *Frozen sections are useful for the treatment of most thyroid lesions except for follicular neoplasms (solitary encapsulated nodules). Papillary carcinoma is the most common lesions which may result in false negative findings.*

**Keywords** : *Frozen section, Thyroid nodules, Accuracy, Sensitivity, Specificity.*

Reprint request: Thesawadwong T. Department of Pathology, Faculty of Medicine,  
Chulalongkorn University, Bangkok 10330, Thailand.

Received for publication. July 15, 2003.

ทิวาพร เทศสวัสดิ์วงศ์, สมบูรณ์ ศีลาวัฒน์. ความแม่นยำในการวินิจฉัยก้อนในต่อมธัยรอยด์ โดยวิธีดูจากชิ้นเนื้อแช่แข็ง. จุฬาลงกรณ์เวชสาร 2546 ต.ค; 47(10): 631 - 40

- เหตุผลในการศึกษา** : ความแม่นยำของการตรวจวินิจฉัยก้อนในต่อมธัยรอยด์ โดยชิ้นเนื้อแช่แข็งของแต่ละสถาบันมีความแตกต่างกันอย่างค่อนข้างเห็นได้ชัด ได้มีการถกเถียงกันอย่างแพร่หลาย ถึงการตรวจวินิจฉัยโรคโดยวิธีดังกล่าวว่าสามารถนำไปใช้ประโยชน์ในการผ่าตัดรักษาโรคของต่อมธัยรอยด์ได้ดีเพียงใด ในโรงพยาบาลจุฬาลงกรณ์นั้น การส่งตรวจด้วยชิ้นเนื้อแช่แข็งเป็นสิ่งที่มีการปฏิบัติกันเป็นประจำ แต่ยังไม่เคยมีการศึกษาถึงความแม่นยำในการวินิจฉัยโรคของต่อมธัยรอยด์โดยการตรวจด้วยวิธีนี้มาก่อน
- วัตถุประสงค์** : เพื่อประเมินคุณค่าของการตรวจวินิจฉัยรอยโรคของต่อมธัยรอยด์โดยการตรวจด้วยชิ้นเนื้อแช่แข็ง
- สถานที่ทำการศึกษา** : ภาควิชาพยาธิวิทยา คณะแพทยศาสตร์ จุฬาลงกรณ์มหาวิทยาลัย
- รูปแบบการวิจัย** : การศึกษาเชิงพรรณนาเพื่อหาคุณสมบัติเฉพาะของเครื่องมือการตรวจวินิจฉัย
- ตัวอย่างในการศึกษา** : ได้จากชิ้นเนื้อของต่อมธัยรอยด์ที่ส่งตรวจชิ้นเนื้อแช่แข็งในโรงพยาบาลจุฬาลงกรณ์ ในช่วงเวลาดังแต่เดือนมกราคม พ.ศ. 2543 ถึง เดือนพฤศจิกายน พ.ศ. 2545
- วิธีการศึกษา** : ผลการวินิจฉัยโรคทั้งจากชิ้นเนื้อแช่แข็งและจากชิ้นเนื้อในพาราฟินได้จากการค้นข้อมูลจากฐานข้อมูลของภาควิชาพยาธิวิทยา ข้อมูลที่ได้นำมาคำนวณหาค่าทางสถิติ
- ผลการศึกษา** : การวินิจฉัยโรคของต่อมธัยรอยด์ด้วยการตรวจชิ้นเนื้อแช่แข็งในโรงพยาบาลจุฬาลงกรณ์มีความไวร้อยละ 84 ความจำเพาะร้อยละ 98.6, positive predictive value ร้อยละ 95.5, negative predictive value ร้อยละ 94.8 ผลบวกเท็จร้อยละ 1 และผลลบเท็จร้อยละ 4 ในรายที่เป็นผลบวกเท็จนั้น จากการตรวจชิ้นเนื้อแช่แข็งอ่านว่าเป็น follicular carcinoma แต่การวินิจฉัยขั้นสุดท้ายด้วยชิ้นเนื้อพาราฟินได้ผลเป็น follicular adenoma สำหรับผลลบเท็จอีกสี่ราย ได้แก่ papillary carcinoma (3 ราย) และ Hurthle cell carcinoma (1 ราย) ร้อยละ 23.4 ของชิ้นเนื้อที่ส่งตรวจชิ้นเนื้อแช่แข็งไม่มีการวินิจฉัยโรคโดยทันที แต่ให้รอผลวินิจฉัยขั้นสุดท้ายจากชิ้นเนื้อพาราฟิน โดยคนไข้กลุ่มนี้พบ follicular adenoma ในอัตราส่วนสูงที่สุด

การตรวจด้วยชิ้นเนื้อแช่แข็งมีประโยชน์ต่อการรักษาคนไข้ส่วนใหญ่ที่เป็นก้อนของต่อมธัยรอยด์ยกเว้นเนื้องอกชนิด follicular neoplasms

นอกจากนี้ยังพบว่า papillary carcinoma เป็นเนื้องอกที่มีอัตราการเกิดผลลบเท็จมากที่สุดด้วย

คำสำคัญ : ชิ้นเนื้อแช่แข็ง, ก้อนของต่อมธัยรอยด์, ความแม่นยำ, ความไว, ความจำเพาะ

**สรุป** : การตรวจด้วยชิ้นเนื้อแช่แข็งมีประโยชน์ต่อการรักษาคนไข้ส่วนใหญ่ที่เป็นก้อนของต่อมธัยรอยด์ยกเว้นเนื้องอกชนิด follicular neoplasms นอกจากนี้ยังพบว่า papillary carcinoma เป็นเนื้องอกที่มีอัตราการเกิดผลลบเท็จมากที่สุดด้วย

**คำสำคัญ** : ชิ้นเนื้อแช่แข็ง, ก้อนของต่อมธัยรอยด์, ความแม่นยำ, ความไว, ความจำเพาะ

# สถาบันวิทยบริการ จุฬาลงกรณ์มหาวิทยาลัย

Frozen sections have been routinely used in operative management of many forms of thyroid lesions. The accuracy of this test varies widely in different centers.<sup>(1-3)</sup> Recently, several articles have been published stating that almost all frozen section could be eliminated in the presence of reliable fine needle aspiration diagnosis.<sup>(1-4)</sup> For example, Rodriguez et al conducted a study to compare preoperative cytology and intraoperative frozen section biopsy in the diagnosis of thyroid nodules. It was found that, in the benign group, the accuracy of fine needle aspiration cytology and frozen section biopsy were 98 and 97 percent respectively. In those with suspicious cytology, diagnostic accuracy was 12 percent for fine needle aspiration and 96 percent for intraoperative frozen section biopsy. In the cases with malignant cytology, there was 100 percent accuracy for fine needle aspiration and 76 percent for frozen section.<sup>(4)</sup> The result of this study, therefore, indicate that frozen section is beneficial for the lesions with suspicious cytology and gave very little advantage over fine needle aspiration cytology in cases of benign or malignant cytology.

In King Chulalongkorn Memorial Hospital, there has been no documented data on the accuracy of intraoperative frozen section biopsy in the diagnosis of thyroid nodules.

To evaluate the accuracy of frozen sections and its common causes of mistakes in the management of thyroid diseases at King Chulalongkorn Memorial Hospital, we studied 128 cases of thyroid lesions with adequate diagnostic information on both frozen section and paraffin section from the files recorded at Department of Pathology.

## Methods

The pathology reports of all patients who underwent thyroid surgery at King Chulalongkorn Memorial Hospital between January 2000 and November 2002 were reviewed. There were 128 cases of thyroid pathological specimens with complete records on both frozen and permanent sections diagnoses. The results of both frozen and paraffin sections were then reviewed for statistic analysis.

"The sensitivity, specificity, accuracy, positive predictive value (PPV), and negative predictive value (NPV) are defined as sensitivity (true positives/true positives + false negatives), specificity (true negatives/true negatives + false positives), accuracy (true positives + true negatives/true positives + true negatives + false positives + false positives), and NPV (true negatives/true negatives + false negatives)."

The cases whose diagnoses were deferred are not included for statistic calculations.

## Results

There were 128 patients at King Chulalongkorn Memorial Hospital who underwent thyroid surgery and had their tissue examined by frozen section at the Department of Pathology from January 2000 to November 2002. The final diagnoses of every case were confirmed by permanent paraffin sections.

The patients were composed of 22 males and 106 females with the ages ranging from 10 -78 years (mean 42 years).

Of the 128 thyroid specimens submitted for frozen sections, 77 cases were diagnosed benign, 21 cases were reported malignant and 30 cases were deferred.

From 77 cases of benign frozen section diagnoses, 73 cases were confirmed benign by permanent specimens. The final diagnoses were follicular adenoma (18 cases), goiter (47 cases), thyroiditis (3 cases) and miscellaneous (5 cases: namely 1 old hemorrhage and fibrosis; 1 benign thyroid with fibrosis; 1 colloid cyst; 1 organized hematoma and 1 diffuse hyperplasia). There were 4 cases whose final diagnoses were malignant (3 papillary carcinoma, and 1 Hurthle cell carcinoma). (Table 1)

Of twenty-one cases reported as "malignant" in frozen sections, three of them are specified as follicular carcinoma (2 cases) and papillary carcinoma

(1 case). Of the two follicular carcinomas, one case was concluded as follicular adenoma in the final report. The other 18 unspecified malignant lesions are confirmed by paraffin sections as 16 papillary carcinomas, 1 poorly differentiated carcinoma and 1 metastatic squamous cell carcinoma. (Table 1) 30 cases (23.4 %) were unconcluded by frozen sections, the definite diagnoses of which were deferred to paraffin specimens. The final diagnoses of these cases consisted of 25 benign lesions (namely: 13 follicular adenomas, 11 goiter and 1 nodular hyperplasia) and 5 malignant lesions which were included 4 papillary carcinoma and 1 medullary carcinoma. (Table 2)

**Table 1.** Frozen section diagnoses of thyroid lesions.

Frozen sections	Paraffin sections
<i>Benign (77 cases)</i>	<i>Benign (73 cases)</i>
	- Follicular adenoma (18 cases)
	- Goiter (47 cases)
	- Thyroiditis (3 cases)
	- Miscellaneous (5 cases)
	<i>Malignant (4 cases)*</i>
	- Papillary carcinoma (3 cases)
	- Hurthle cell carcinoma (1 case)
<i>Malignant (21 cases)</i>	
- Specified types (3 cases)	
- Follicular carcinoma (2 cases)	- Follicular adenoma (1 case)*
	- Follicular carcinoma (1 case)
- Papillary carcinoma (1 case)	- Papillary carcinoma (1 case)
- Malignant, nonspecified (18 cases)	- Papillary carcinoma (16 cases)
	- Poorly differentiated CA (1 case)
	- Metastatic carcinoma (1 case)

\* Cases misdiagnosed by frozen section.

**Table 2.** Diagnoses of 30 deferred cases.

Frozen sections	Paraffin sections
Deferred (30 cases)	Benign (25 cases)
	- Follicular adenoma (13 cases)
	- Goiter (11 cases)
	- Nodular hyperplasia (1 case)
	Malignant (5 cases)
	- Papillary carcinoma (4 cases)
	- Medullary carcinoma (1 case)

**Table 3.** Statistic analysis of frozen section in thyroid cancer diagnosis.

Sensitivity	83.3 %
Specificity	98.6 %
Accuracy	94.9 %
Positive predictive value	95.2 %
Negative predictive value	94.8 %
False positive	1 %
False negative	4 %

The statistic value of frozen section diagnoses reveals: 83.3 % sensitivity, 98.6 % specificity, 94.9 % accuracy, 95.2 % of positive predictive value, and 94.8 % of negative predictive value. False positive and false negative rates are 1 % and 4 %, respectively. (Table 3)

### Discussion

According to our study, frozen section is generally useful in the treatment of thyroid lesions. The high accuracy in the present study may be partly

due to imprint cytology which, in our department, was done in most cases while performing frozen section. The lesions which have high rate of correct diagnosis include goiter (100 %) and thyroiditis (100 %) followed by papillary carcinoma which was 85 % correctly diagnosed. In only 66.6 % were the follicular neoplasms correctly subclassified (follicular adenoma or carcinoma) by frozen sections.

Most of the errors are false negative (4 cases or 4 %) with only one case (1 %) of false positive. The most frequent false negative lesions in this study are papillary carcinoma (3 cases). The false positive in the present series (1 case) is follicular adenoma which was erroneously called "follicular carcinoma" on frozen section examination.

Misdiagnoses of frozen section examination in thyroid surgery may result from 1. the limitation of the capsule sampling (in follicular neoplasia); 2. suboptimal nuclear or cytologic detail; 3. time constraints; 4. reluctance of pathologists to commit to a definite diagnosis of malignancy prior to the review of all material and consultation with other pathologists.<sup>(5)</sup>

In follicular neoplasms, frozen section diagnosis is limited by adequacy of capsule sampling. Usually, only 2-3 sections are submitted for evaluation which is not sufficient for making a reliable exclusion of capsular or vascular invasion. In order to make a definite diagnosis, extensive sampling of the capsule is required and this is only possible in permanent specimens. Many authors discourage frozen section as a mean to evaluate for follicular lesions.<sup>(6)</sup> For example, Chen *et al.*<sup>(7)</sup> studied 120 cases of follicular lesions and found that 104 cases (87 %) of them were categorized as "follicular lesion, deferred to permanent section" rendering no useful clinical information. In the same study, only 4 patients (3.3 %) had their frozen sections evaluated correctly and modified the operative procedure. Moreover, there were six cases (5 %) of incorrect frozen section, the evaluation of which resulted in four misguided operations. And in the current series, we have found that of all 33 follicular neoplasms, 13 cases were deferred (39.3 %) and two cases (6 %) were misinterpreted which is considerably high rate of

deferral and misinterpretation. Therefore, we also discourage frozen section for follicular lesions.

The lesions which were most frequently misdiagnosed in the current study were papillary carcinoma (3 cases). This could be explained by suboptimal nuclear and cytologic details of malignant cells of specimens on frozen section (Figure 1). The typical nuclear features of papillary carcinoma such as ground-glass nuclei, nuclear grooves and intranuclear pseudoinclusions are not easily seen on frozen tissue.<sup>(8)</sup> The diagnosis of malignancy is primarily based on the detection of papillary structures. Difficulty may arise when one is dealing with follicular variant of papillary carcinoma whose papillary architecture is rarely present.<sup>(1,9)</sup> For instance, in the study of Gibb *et al.*<sup>(1)</sup> 6 of 11 cases of papillary carcinoma, follicular variant were misdiagnosed as follicular neoplasms. Likewise, 2 of 3 cases of papillary carcinoma which were reported benign on frozen sections in our series also lack papillary features.

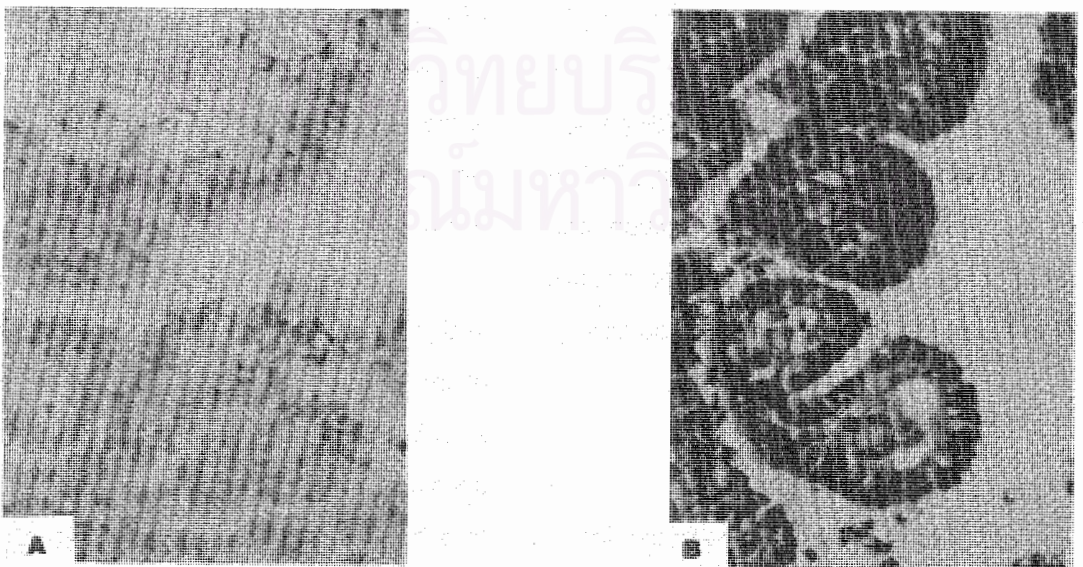


Figure 1. Comparison on nuclear and cytologic details of papillary carcinoma between frozen section (A) and permanent specimen (B).



In this study, deferral rate is quite high (23.4 %). This is understandable since many pathologists are reluctant to commit to definitive diagnosis under time constraint. The lesion which is most frequently deferred is follicular adenoma (43.3 % of deferred cases) followed by goiter (36.6 % of deferred cases). In our study, papillary carcinoma is the third most common deferred lesion (13.3 %).

To avoid errors in frozen section evaluation, imprint cytology is recommended for the interpretation of specimen of frozen section. This is especially helpful for the detection papillary carcinoma. Regarding follicular neoplasms (solitary encapsulated nodule), we do not recommend intraoperative frozen sections since it rarely changes operative management. Pathologists who are consulted for frozen section evaluation in this type of lesion should defer the diagnosis to permanent sections as the chance to miss capsular or vascular invasion in frozen section examination is very high.

Several studies were done to compare the usefulness between frozen section and fine needle aspiration cytology diagnosis.<sup>(1, 4)</sup> It has been documented in the literature that 50-90 % of the lesions with suspicious cytology report will eventually be benign on final paraffin sections.<sup>(1)</sup> In such circumstance, frozen section may be helpful for further management since it may provide additional information other than what is given by fine needle aspiration cytology. In contrast, if fine needle aspiration of thyroid nodules reports malignancy, it is quite certain that the lesions will finally turn out to be malignant and the information from frozen section usually gives very little chance to modify the operative plan. In this situation, total/ near total thyroidectomy

can proceed without any confirmation by frozen section.<sup>(1)</sup>

In summary, our study indicated that frozen section is a useful guide in the management of thyroid lesions. Papillary carcinoma and follicular neoplasms are two major lesions often misdiagnosed. Imprint cytology is recommended to increase the accuracy rate for the diagnosis of papillary carcinoma. And lastly, since frozen section rarely give useful information to alter operative management in follicular neoplasms, we discourage this procedure in the diagnosis of solitary encapsulated thyroid lesions.

#### References

1. Gibb GK, Pasiaka JL. Assessing the need for frozen sections: still a valuable tool in thyroid surgery. *Surgery* 1995 Dec;118(6): 1005 - 10
2. Iris JC, van Nostrand AW, Asa SL, Gullane P, Rotstein L. Accuracy of pathologic diagnosis in thyroid lesions. *Arch Otolaryngol Head Neck Surg* 1992 Sep; 118(9): 918 - 22
3. Kopald KH, Layfield LJ, Mohrmann R, Forshag LJ, Giuliano AE. Clarifying the role of fine-needle aspiration cytologic evaluation and frozen section examination in the operative management of thyroid cancer. *Arch Surg* 1989 Oct; 124(10): 1201 - 5
4. Rodriguez JM, Parrilla P, Sola J, Bas A, Aguilar J, Moreno A, Soria T. Comparison between preoperative cytology and intraoperative frozen section biopsy in the diagnosis of thyroid nodules. *Br J Surg* 1994 Aug; 81(8): 1151 - 4
5. McHenry CR, Rosen IB, Walfish PG, Bedard Y. Influence of fine-needle aspiration biopsy

- and frozen section examination on the management of thyroid cancer. *Am J Surg* 1993 Oct; 166(4): 353 - 6
6. LiVolsi VA, Baloch ZW. Follicular carcinoma of the thyroid. *Pathology Case Reviews* 2003 Jan-Feb; 8(1): 4 - 15
7. Chen H, Nicol TL, Udelsman R. Follicular lesions of the thyroid: does frozen section evaluation alter operative management ? *Ann Surg* 1995 Jul; 222(1): 101 - 6
8. Cotran RS, Kumar V, Collins T. *Robbins Pathologic Basis of Disease*. 6<sup>th</sup> ed. Philadelphia: W.B. Saunders, 1999: 1130 - 47
9. Tielens ET, Sherman SI, Hruban RH, Ladenson PW. Follicular variant of papillary thyroid carcinoma. A clinicopathologic Study. *Cancer* 1994 Jan; 73(2): 424 - 31



สถาบันวิทยบริการ  
จุฬาลงกรณ์มหาวิทยาลัย