

Primary acinic cell carcinoma of the lung: The first case report in Thailand

Yavarace Vongsivavilas*

Chaiwut Yottasurodom** Saowanee Yenrudi***

**Vongsivavilas Y, Yottasurodom C, Yenrudi S. Primary acinic cell carcinoma of the lung:
The first case report in Thailand. Chula Med J 2005 Mar; 49(3): 157 - 63**

Primary acinic cell carcinoma (ACC) of the lung is a malignant tumor and arises from serous acinar cells of the bronchial gland, analogous to ACC of the parotid gland. It is an extremely rare tumor. Only 12 cases have previously been reported. We report the first case of primary pulmonary ACC in Thailand, presenting with an incidental mass on the chest radiograph a year prior to the referral for surgery. The diagnosis of primary pulmonary ACC is made by histopathologic examination of the lobectomy specimen and the exclusion of other possible primaries. Stability of findings on plain-film radiographs over a year does not exclude malignancy, especially when dealing with a low-grade malignant tumor like ACC.

Keywords: Acinic cell carcinoma, Primary lung cancer, Carcinoma of bronchial gland type, Lung cancer, Carcinoma.

Reprint request: Department of Pathology, Chest Disease Institute, Department of Medical Services, Ministry of Public Health, Nonthaburi, Thailand

Received for publication. October 15, 2004.

* Department of Pathology, Chest Disease Institute, Department of Medical Services, Ministry of Public Health, Nonthaburi, Thailand

** Department of Surgery, Chest Disease Institute, Department of Medical Services, Ministry of Public Health, Nonthaburi, Thailand

***Department of Pathology, Faculty of Medicine, Chulalongkorn University

เยาวเรศ วงศ์ศิวัชวิลาส, ชัยวุฒิ ยศธาสุโรดม, เสาวณีย์ เอ็นฤดี. มะเร็งปฐมภูมิของปอด
เอ็กซินิก: รายงานผู้ป่วยรายแรกของประเทศไทย. จุฬาลงกรณ์เวชสาร 2548 มี.ค; 49(3):
157 - 63

มะเร็งปฐมภูมิของปอดที่ชื่อ Acinic เป็นโรคมะเร็งที่เกิดมาจากเซลล์ Serous ของต่อมใน
หลอดลม ซึ่งเป็นแบบเดียวกับเซลล์มะเร็งของต่อมน้ำลาย Parotid มะเร็งชนิดนี้พบได้น้อยมาก
เหลือเกิน ในอดีตเคยมีรายงานไว้แล้วเพียง 12 รายเท่านั้น คณะผู้เขียนกำลังรายงานผู้ป่วยด้วยโรค
มะเร็งชนิดนี้เป็นครั้งแรกในประเทศไทย ผู้ป่วยรายนี้มีก้อนที่ปอดซึ่งพบโดยบังเอิญ จากการตรวจ
เอ็กซเรย์ปอดเมื่อ 1 ปีก่อนหน้าที่ผู้ป่วยจะถูกส่งตัวมารับการรักษาด้วยการผ่าตัดที่สถาบันแห่งนี้ ผู้ป่วย
รายนี้ได้รับการตรวจวินิจฉัยทางพยาธิวิทยาจากกลีบปอดที่ถูกผ่าตัดออกมา และจากการตรวจวินิจฉัย
ทางคลินิกก็ปรากฏว่าไม่พบมะเร็งต้นตอชนิดเดียวกันนี้ในอวัยวะอื่น ๆ การตรวจภาพถ่ายจากเอ็กซเรย์
ปอดแล้วพบว่าไม่มีการเปลี่ยนแปลงของก้อนในปอดเมื่อเปรียบเทียบกับรูปภาพเอ็กซเรย์ปอดที่ถ่ายไว้
เมื่อ 1 ปีก่อนนั้น ไม่ได้หมายความว่าก้อนในปอดที่พบไม่ใช่มะเร็ง โดยเฉพาะอย่างยิ่งมะเร็งชนิด
Acinic ซึ่งเป็นมะเร็งชนิดรุนแรงน้อย

คำสำคัญ : มะเร็งเอ็กซินิก, มะเร็งปฐมภูมิของปอด, มะเร็งชนิดต่อมหลอดลม, มะเร็งปอด, มะเร็ง

Primary acinic cell carcinoma (ACC) of the lung is a malignant tumor of the lung. This primary pulmonary tumor arises from serous acinar cells of the bronchial gland, analogous to ACC of the parotid gland.⁽¹⁻¹⁰⁾ It is an extremely rare tumor. The first case of primary ACC was reported by Fechner et al in 1972.⁽¹⁾ Since then, only 11 additional primary ACC of the lung and 5 cases of the trachea have been published in the literatures.^(2-8, 11, 12) This tumor has also been termed 'Fechner tumor' after its discoverer.^(5, 9, 13) Accurate diagnosis of this tumor is very important in order to offer a possible curative treatment for the patient. However, this is sometimes difficult. Due to its indolent nature and benign appearance on radiographs, gross, and light microscopy, it can be mistaken for being a benign lesion and treated as such. Familiarity with its clinical and histopathologic features will help establishing the correct diagnosis. We therefore report the first case of primary pulmonary ACC in Thailand, discuss diagnostic points and thoroughly review the literatures. Due to its rarity, information acquired from this case report would serve as a data profile in the medical literatures.

Case report

A 37-year-old single woman presented with the history of a right upper lobe (RUL) mass found incidentally on a routine chest X-rays one year prior to this referral. At another hospital, she was given anti-tuberculous drugs for a presumptive diagnosis of Tuberculosis. A year later, a repeat chest radiograph revealed the same size of RUL mass, (Figure 1). Being concerned about the possibility of malignancy, she was then referred to this hospital. She had had no

symptoms of hemoptysis, weight loss, or productive cough. She denied history of drinking, smoking, previous surgery or a previous salivary gland tumor. She was currently on no medication. Her physical examination was unremarkable. Her complete blood count, urinalysis, chemistry profile and electrocardiogram were within normal limits. High resolution computed tomographic (HRCT) scan of the chest confirmed a well-defined RUL mass of 3.0 centimeter in diameter and without radiographic hilar or mediastinal lymphadenopathy, (Figure 2). HRCT of the abdomen showed no abnormalities and no mass in the pancreas, kidneys, liver or adrenal glands was detected. She underwent the RUL lobectomy and lymph node staging. Her post-operative course was great and she was discharge on day 7.

The surgical specimen consisted of a RUL and a peribronchial lymph node. Cut sections of the RUL specimen revealed a well-circumscribed, pink, firm, parenchymal mass, measuring 3.3 X 3.0 X 2.6 cm. There was no connection of the mass to the bronchial mucosa. The remaining lung and bronchi were grossly unremarkable. The bronchial resected margin was grossly free of tumor. Microscopic examination disclosed a completely encapsulated mass with a pushing border, (Figure 3). The tumor mass was composed of predominantly solid sheets of cohesive granular cells with few foci of acinar pattern. These bland appearing cells were large, polygonal, and contained abundant eosinophilic cytoplasm with variable granularity. They had small, round and hyperchromatic nuclei which were either centrally or eccentrically located, (Figure 4). Mitotic figure, atypia, desmoplastic change, or tumor necrosis was not seen. No vascular, lymphatic or perineural invasion was

detected. The remaining lung parenchyma appeared normal. The peribronchial lymph node was free of

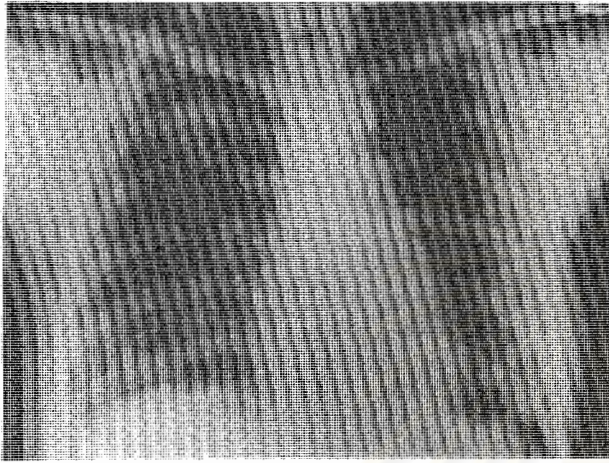


Figure 1. Chest radiograph shows a well-defined homogeneous mass in the right upper lobe.

metastatic tumor. The findings were compatible with ACC.

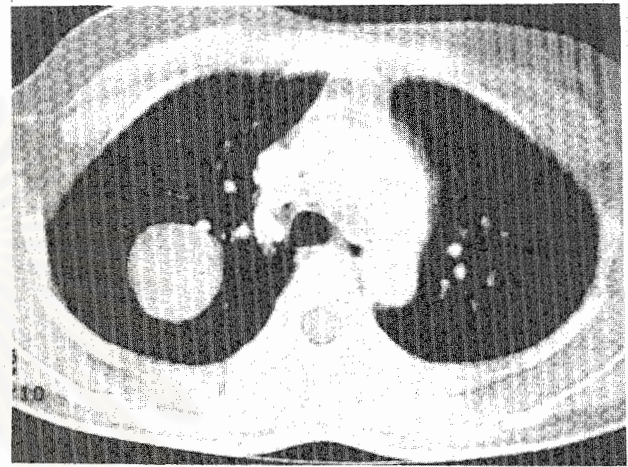

Figure 2. HRCT of the chest confirms a well-circumscribed, round mass in the right upper lobe. The lung parenchyma appears normal.




Figure 3. Section of the right upper lobe mass shows a well-defined tumor covered with a thin fibrous connective tissue capsule. Solid sheets of bland appearing granular cells are seen, (H&E stained section, X 40).

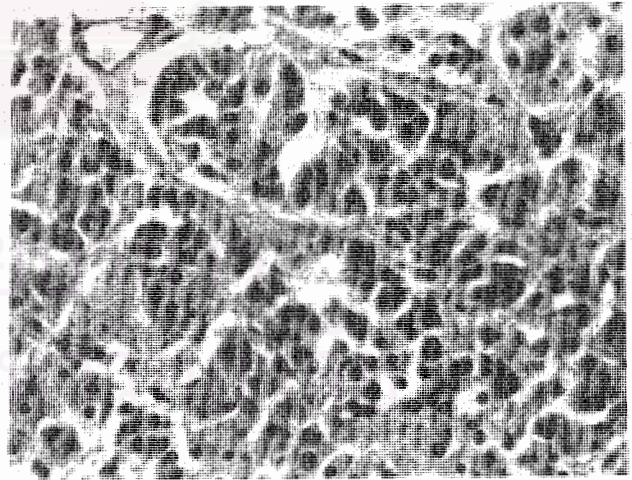


Figure 4. High magnification of the tumor demonstrates the granular cells containing abundant eosinophilic cytoplasm with variable granularity. The nuclei are small, round and hyperchromatic. They are either centrally or eccentrically located, (H&E stained section, X 400).

Discussion

Primary ACC of the lung is an extremely rare tumor. We have found only 12 previous reports of them.⁽¹⁻⁸⁾ We presently report the 13th case of this extremely rare tumor. Of all reported cases, primary ACC of the lung occurred almost equally in both sexes with male to female ratio of 6 to 7, and age ranged from 12 to 75 years. In most cases, it was an incidental radiographic finding. The right lung was more frequently affected than the left lung with the ratio of 10 to 3. None of the patients had prior head and neck surgery or a previous salivary gland tumor. Two cases presented with recurrent lung infections and another 2 cases presented with persistent cough and hemoptysis. The tumor was detected on bronchoscopy in these 4 cases. Regional lymph node metastases were found in 2 of 8 cases. Lymph node status was not mentioned in the other 5 cases. The patients were alive and well ranged from 1 to 10 years of follow-up.

It is impossible to diagnose ACC on clinical or radiological basis. ACC usually appears as a smooth, well-demarcated nodule on the chest radiographs and HRCT and can easily be mistaken for a benign lesion. Correct diagnosis must be based on histopathologic findings. Our report is a classic case of ACC and composed of predominantly solid sheets of granular cells with few foci of acinar pattern. These cohesive granular cells are typical well-differentiated serous cells. They are the most easily recognized ACC on light microscopy.⁽¹⁴⁾ Some cases of ACC may show vacuolated or clear cells in organoid or trabecular pattern and mimic clear cell 'sugar tumor' or carcinoid or metastatic renal cell carcinoma. Electron microscopy (EM), histochemical (HC) and/or

immunohistochemical (IM) stains may be helpful in excluding those mimicking tumors.

The role of EM and IM is limited in the positive identification and diagnosis of ACC.⁽⁵⁾ EM is an expensive and time-consuming procedure and such facility is available in only few institutions. Moreover, the electron dense granules of zymogen are poorly preserved on the routine osmium tetroxide fixative, thus makes it difficult to interpret. However, this problem may be overcome with the use of aldehydes as the initial fixative for EM.⁽¹⁵⁾ With this fixative, well-defined spherical granules of high electron density can be identified in most serous cells.⁽¹⁵⁾ Detection of amylase enzyme is useless since it is rarely positive in serous cells of ACC on IM stain. By and large, we concur with Moran et al that correct diagnosis of ACC rests on morphology recognition of tumor cells possessing the features of serous acinar cells and accurate histologic interpretation on light microscopic examination.⁽⁵⁾ EM, HC, and/or IM stains are necessary in excluding the imitators.

Primary ACC of the lung generally shows histopathologic features indistinguishable from ACC of the parotid glands, pancreas, or other organs. The diagnosis of primary ACC of the lung rests on the exclusion of primary ACC elsewhere, especially the parotid gland. Although, ACC is an uncommon tumor of the salivary glands, its occurrence in the parotid gland is a lot more common than in the lung. ACC occurs almost exclusively in the parotid gland.^(14, 16) It represents 2.5 % of all primary parotid gland tumors,⁽¹⁷⁾ and ranks third among parotid gland neoplasms. In addition, lung is the most common site of hematogenous spread from primary parotid ACC and followed by bone.^(14, 18) History is helpful in

excluding metastases from salivary gland lesions as lung metastases usually occur after discovery of the primary malignancies. With salivary gland primaries, lung metastases can occur many years later, despite the noninvasive and benign-appearing primary sources.^(19,20) Our reported case, history and clinical investigation exclude parotid gland tumor.

Primary ACC of salivary gland has become a well-established, low-grade malignancy.⁽²¹⁾ However, the growth behavior or natural history of primary pulmonary ACC is not clearly understood as yet. According to the reported cases of primary pulmonary ACC, regional lymph node metastases occurred in 2 cases. It is probably reasonable to consider this tumor a low-grade malignancy rather than essentially benign with occasional unpredictable malignant behavior. While there has been only limited experience to serve as a guide to treatment and prognosis of primary ACC of the lung, we agree with most authors that lobectomy or pneumonectomy with lymph node staging is the treatment of choice.

In conclusion, we report the first case of primary pulmonary ACC in Thailand, diagnosed by histopathologic examination of the lobectomy specimen and exclusion of other possible primaries. Stability of findings on plain-film chest radiographs over a year does not exclude malignancy, especially when dealing with a low-grade malignant tumor like ACC.

References

1. Fechner RE, Bentinck BR, Askew JB Jr. Acinic cell tumor of the lung. A histologic and ultrastructural study. *Cancer* 1972 Feb; 29(2): 501 - 8
2. Katz DR, Bubis JJ. Acinic cell tumor of the bronchus. *Cancer* 1976 Aug; 38(2): 830 - 2
3. Gharpure KJ, Deshpande RK, Vishweshvara RN, Raghu CR, Bhargava MK. Acinic cell tumour of the bronchus (a case report). *Indian J Cancer* 1985 Jun; 22(2): 152 - 6
4. Yoshida K, Koyama I, Matsui T, Tsukiyama M, Mizushima M. Acinic cell tumor of the bronchial gland. *Nippon Geka Gakkai Zasshi* 1989 Oct; 90(10): 1810 - 3
5. Moran CA, Suster S, Koss MN. Acinic cell carcinoma of the lung ("Fechner tumor"). A clinicopathologic, immunohistochemical, and ultrastructural study of five cases. *Am J Surg Pathol* 1992 Nov; 16(11): 1039 - 50
6. Ukoha OO, Quartararo P, Carter D, Kashgarian M, Ponn RB. Acinic cell carcinoma of the lung with metastasis to lymph nodes. *Chest* 1999 Feb; 115(2): 591 - 5
7. Lee HY, Mancer K, Koong HN. Primary acinic cell carcinoma of the lung with lymph node metastasis. *Arch Pathol Lab Med* 2003 Apr; 127(4): e216-9
8. Rodriguez J, Diment J, Lombardi L, Dominoni F, Tench W, Rosai J. Combined typical carcinoid and acinic cell tumor of the lung: a heretofore unreported occurrence. *Hum Pathol* 2003 Oct; 34(10): 1061 - 5
9. Colby TV, Koss MN, Travis WD. Tumors of salivary gland type. In: Colby TV, Koss MN, Travis WD, eds. *Tumors of the Lower Respiratory Tract: Atlas of Tumor Pathology*. 3rd series, fascicle 13. Washington, DC: Armed Forces Institute of Pathology, 1995: 85 - 5, 294 - 309

10. Dail DH. Uncommon tumors. In: Dail DH, Hammer SP, eds. Pulmonary Pathology. 2nd ed. New York: Springer-Verlag, 1994: 1290 - 2
11. Ansari MA, Marchevsky A, Strick L, Mohsenifar Z. Upper airway obstruction secondary to acinic cell carcinoma of the trachea. Use of Nd:YAG laser. Chest 1996 Oct;110(4): 1120 - 2
12. Heard BE, Dewar A, Firmin RK, Lennox SC. One very rare and one new tracheal tumour found by electron microscopy: glomus tumour and acinic cell tumour resembling carcinoid tumours by light microscopy. Thorax 1982 Feb; 37(2): 97 - 103
13. Hasleton PS. Benign lung tumors and their malignant counterparts. In: Hasleton PS, ed. Spencer's Pathology of the Lung. 5th ed. St. Louis: McGraw-Hill, 1996: 889 - 91
14. Lewis JE, Olsen KD, Weiland LH. Acinic cell carcinoma. Clinicopathologic review. Cancer 1991 Jan 1; 67(1): 172 - 9
15. Erlandson RA, Tandler B. Ultrastructure of acinic cell carcinoma of the parotid gland. Arch Pathol 1972 Feb; 93(2): 130 - 40
16. Abrams AM, Cornyn J, Scofield HH, Hansen LS. Acinic cell adenocarcinoma of the major salivary glands: A clinicopathologic study of 77 cases. Cancer 1965 Sep;18:1145 - 62
17. Spiro RH, Huvos AG, Strong EW. Acinic cell carcinoma of salivary origin. A clinicopathologic study of 67 cases. Cancer 1978 Mar; 41(3): 924 - 35
18. Levin JM, Robinson DW, Lin F. Acinic cell carcinoma: collective review, including bilateral cases. Arch Surg 1975 Jan;110(1): 64 - 8
19. Sidhu GS, Forrester EM. Acinic cell carcinoma: long-term survival after pulmonary metastases: light and electron microscopic study. Cancer 1977 Aug;40(2): 756 - 65
20. Eneroth CM, Jakobsson PA, Blanck C. Acinic cell carcinoma of the parotid gland. Cancer 1966 Dec; 19(12): 1761 - 72
21. Ellis GL, Corio RL. Acinic cell adenocarcinoma. A clinicopathologic analysis of 294 cases. Cancer 1983 Aug 1; 52(3): 542 - 9