

## Renal cell carcinoma with sarcomatoid and rhabdoid feature

Wipawee Kittikowit\*

Voranuch Thanakit\*

**Kittikowit W, Thanakit V. Renal cell carcinoma with sarcomatoid and rhabdoid feature.****Chula Med J 2004 Dec; 48(12): 821 - 7**

*A 49-year-old male patient presented with chest pain, back pain and pain in both flanks. Physical examination revealed a mass with smooth surface in the left side of the abdomen. Radiographic investigation revealed a left renal mass, 12.5x10 x 9.7cm with multiple bone destruction. Left radical nephrectomy was done. The renal mass was mainly composed of spindle cells of sarcomatoid part and discohesive cells with rhabdoid feature. Only a small conventional clear cell part was present. The tumor behaved aggressively by invading through the renal capsule and metastasized to multiple bones including the skull. Immunohistochemical studies confirmed the non-myogenic properties, negative for desmin and smooth muscle actin. The weak positivity for pancytokeratin together with strong expression of vimentin was compatible with renal cell carcinoma. The differential diagnoses include rhabdoid tumor that exclusively occurs among children and renal medullary carcinoma which also usually occurs in association with Sick cell hemoglobinopathy. The renal cell carcinoma with either sarcomatoid or rhabdoid component almost always gives rise to the poor outcome and should be reported whenever it presents.*

**Keywords:** Renal cell carcinoma, Rhabdoid, Sarcomatoid.

Reprint request: Kittikowit W. Department of Pathology, Faculty of Medicine, Chulalongkorn University, Bangkok 10330, Thailand. E- mail: [fmedwkt@md.chula.ac.th](mailto:fmedwkt@md.chula.ac.th)

Received for publication: October 8,2004.

วิภาวี กิตติโกวิท, วรนุช ธนากิจ. มะเร็งไตที่มีลักษณะเหมือนมะเร็งเนื้อเยื่ออ่อนและกล้ามเนื้อลาย. จุฬาลงกรณ์เวชสาร 2547 ธ.ค; 48(12): 821 - 7

ผู้ป่วยชายไทยอายุ 49 ปีมาพบแพทย์ด้วยอาการเจ็บหน้าอก ปวดหลัง และปวดบริเวณบั้นเอว ทั้งสองข้างมา 1 เดือน จากการตรวจร่างกายคลำพบก้อนในท้องทางด้านซ้าย มีผิวเรียบ เมื่อตรวจทางรังสีวิทยาพบก้อนที่ไตข้างซ้ายขนาด 12.5 x 10 x 9.7 เซนติเมตร ร่วมกับมีการทำลายของกระดูกสันหลังหลายแห่ง ผู้ป่วยได้รับการผ่าตัดเอาก้อนและไตข้างซ้ายออก พบว่าส่วนใหญ่ของก้อนประกอบด้วยเซลล์รูปกระสวย และเซลล์รูปร่างคล้ายเซลล์อ่อนของกล้ามเนื้อลาย บริเวณที่เป็นเซลล์ใสซึ่งพบบ่อยในมะเร็งไตมีเพียงบริเวณเล็ก ๆ เนื้อเยื่ออื่นแสดงพฤติกรรมร้ายแรงโดยลุกลามผ่านเปลือกหุ้มไตไปยังอวัยวะข้างเคียง และยังกระจายไปที่กระดูกหลายแห่งรวมทั้งกะโหลกศีรษะ การย้อมพิเศษด้วยวิธีทางอิมมูโนฮิสโตเคมีว่าเซลล์มะเร็งไม่มีคุณสมบัติของ เซลล์กล้ามเนื้อ แต่มีคุณสมบัติที่เข้าได้กับมะเร็งที่เกิดจากเซลล์บุท่อไต การวินิจฉัยแยกโรคต้องแยกจากเนื้องอก Rhabdoid ซึ่งมักพบในเด็ก และมะเร็งหลอดฝอยไตส่วนล่าง (renal medullary carcinoma) ซึ่งมักเกิดในผู้ป่วยที่มีโรคโลหิตจางชนิด Sickle cell มะเร็งหลอดฝอยไตที่มีลักษณะ Sarcomatoid และ Rhabdoid นี้ มักจะมีพยากรณ์โรคที่แย่กว่ามะเร็งหลอดฝอยไตทั่วไป และเมื่อพบลักษณะดังกล่าวควรจะต้องระบุไว้ในรายงานทางพยาธิวิทยาเสมอ

คำสำคัญ : มะเร็งไต

Rhabdoid tumor is a malignant neoplasm that has an aggressive behavior found predilectively in childhood. The tumor is characterized by cells morphologically resemble rhabdomyoblasts. These cells exhibit large eccentrically located vesicular nuclei with prominent nucleoli and a unique cytoplasmic globular inclusion body which does not express muscular molecules. The cells with similar cytologic features were found in many tumors of extrarenal sites. Not many cases of renal cell carcinoma with these rhabdoid cells have been reported. All the reported cases were of adulthood. Clear cell type is the major variant that the rhabdoid attribute was found associated with.<sup>(1-3)</sup> The genetic analysis showed suggestive evidence of clonal evolution.

### Case Report

A 49-year-old male patient presented with the chief complaint of chest pain, back pain and pain in both flanks for one month. Physical examination revealed a mass with smooth surface in the left side of the abdomen. Abdominal computed tomography scan showed a left renal mass, 12.5 x 10 x 9.7 cm with multiple bone destruction at T12, L1, L2, L4, L5 and the left 5<sup>th</sup> rib. Computed tomography scan of the brain showed skull metastasis of the right parietal bone.

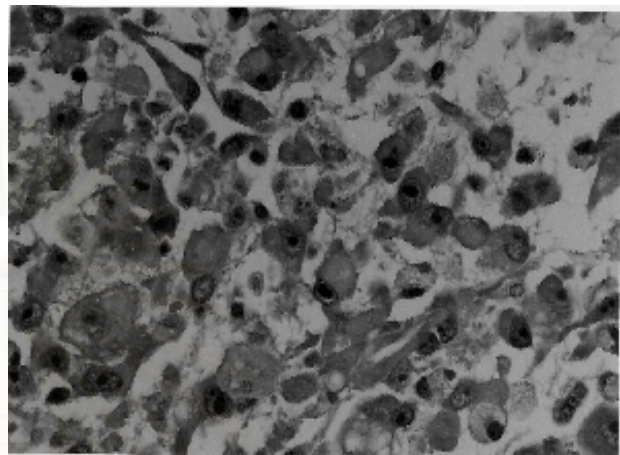
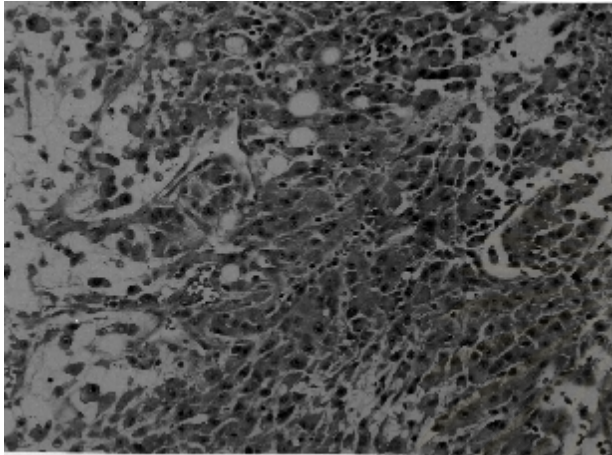
Left radical nephrectomy was performed and revealed an ill-defined mass at the upper pole measuring 10 x 8.5 x 8.0 cm. Cut surface of the tumor exhibited reddish yellow gelatinous and myxoid appearance with focal solid yellow white and hemorrhagic areas. The tumor extended beyond the renal capsule to the perinephric fat. The renal vein and pelvis were unable to be identified.

Microscopically, most of the tumor was composed of eosinophilic round to spindle cells scattered on a myxoid background. The tumor cells closely aggregated surrounding blood vessels. These eosinophilic cells with round to tadpole shape contained moderate to abundant cytoplasm which condensed and formed hyaline globule like structure, no striation was identified. The tumor nuclei were eccentrically placed and displayed high grade appearance, Fuhrman grade IV (Fig.1). A small area of neoplastic cells with clear cytoplasm of the classic clear cell variant was encountered. The clear cells in this area contained nuclei of the lower grade, grade II (Fig.2A). Foci of hemorrhage and tumor necrosis were profuse. Another area exhibited tumor cells with spindle shape and high grade nuclei of sarcomatoid variant which was incorporated to the rhabdoid area (Fig.2B). The clear cell zone and the eosinophilic cells were focally merged with intermingling of both cell variants that possessed high grade nuclei (Fig.3). The renal tubules adjacent to the mass displayed atypical pleomorphic nuclei while tumor cells were found in the intervening interstitium (Fig.4). Numerous blood vessels of capillary size were present in the myxoid area.

Histochemically, the myxoid stroma was stained positively with Alcian Blue. Some eosinophilic cells were partially periodic acid-Schiff (PAS)-positive and sensitive to diastase, but they were negative for intracytoplasmic mucin. Immunohistochemical studies revealed diffuse and strong reactivity with vimentin, weak and focal positivity with pan-cytokeratin (keratin bovine) in the cytoplasm of the rhabdoid cells (Fig.5), and negative reaction for CK7, S-100, desmin and smooth muscle actin.

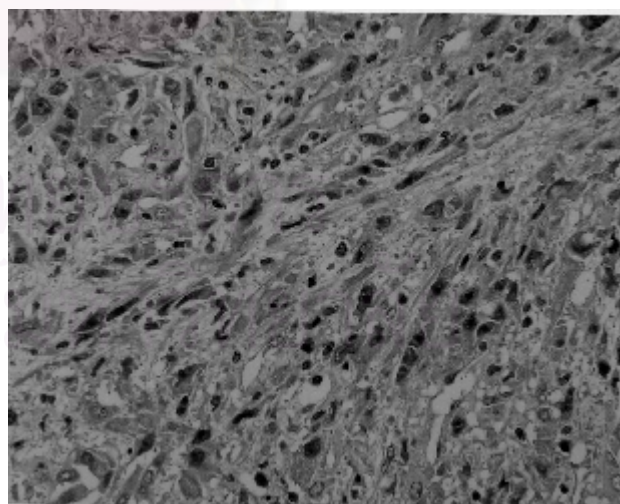
The diagnosis of renal cell carcinoma with sarcomatoid and rhabdoid features was given to this

patient.



**Figure 1A.** Round to oval shaped tumor cells that were discohesive and focally scattered on a myxoid background resemble Rhabdoid tumor (H&E original magnification x 200).


**Figure 1B.** Tumor cells exhibited eccentrically located high graded nuclei with prominent nucleoli and moderate to abundant cytoplasm which condensed and formed hyaline globule like structure (H&E original magnification x 1000).



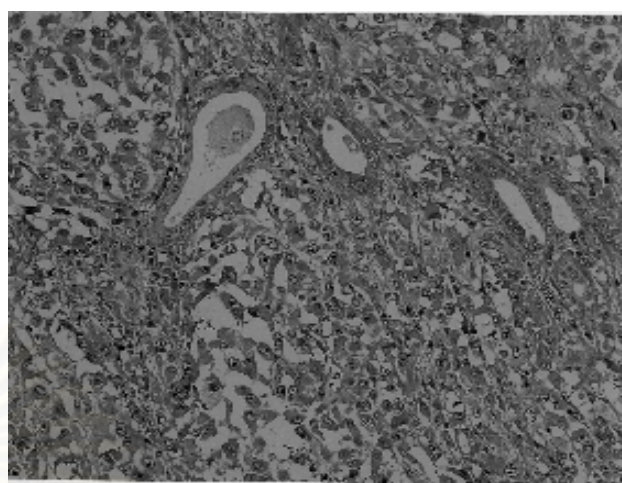
**Figure 2A.** A focus of conventional clear cell renal cell carcinoma exhibited lower nuclear grade (H&E original magnification x 200).

**Figure 2B.** The sarcomatoid part comprised spindle shaped neoplastic cells with high nuclear grade (H&E original magnification x 400).

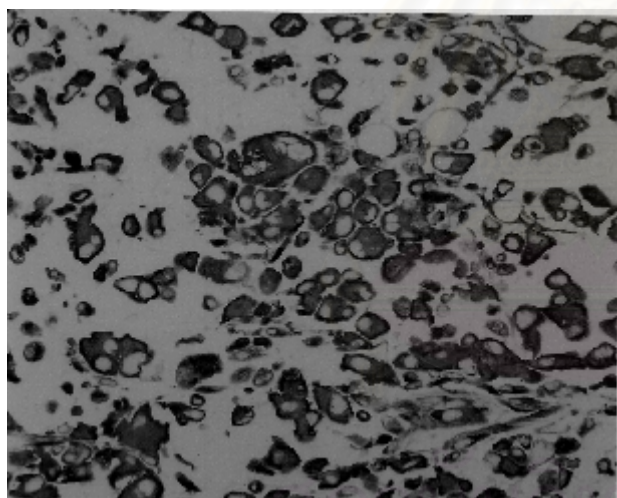




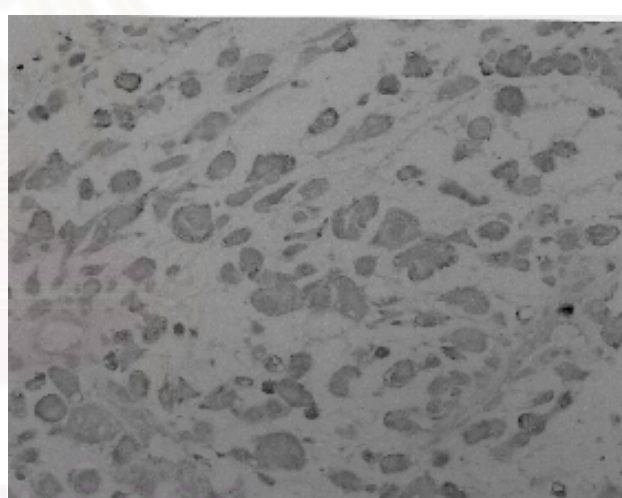
**Figure 3.** The rhabdoid tumor cells mingled with clear cell (H&E original magnification x 400).



**Figure 4.** Benign renal tubules were found admixed with the rhabdoid tumor cells (H&E original magnification x 200).



**Figure 5A.** The rhabdoid tumor cells exhibited strong vimentin reactivity in the cytoplasm.



**Figure 5B.** The tumor cells weakly expressed cytokeratin.

## Discussion

The term renal cell carcinoma with rhabdoid feature was first cited by Gökden *et al.* in 2000.<sup>(1)</sup> Prior to this study, the same feature was described in 1991 by Sano and Weeks *et al.*<sup>(1,4)</sup> Up to now a few cases were in the literature.<sup>(1-5)</sup> The 3 to 5 % incidence

of the total cases of renal cell carcinoma were proclaimed.<sup>(1,3)</sup>

This is the first case of renal cell carcinoma with rhabdoid feature found in our institute. The patient presented with an advanced stage tumor which the primary mass was large with invasion to the adjacent

organs and remote bone metastases, despite the localized symptoms of only flank pain and pain at metastatic sites. The tumor exhibited rhabdoid together with sarcomatoid attributes in majority. Only a small part of clear cell component is observed. The diagnosis of renal cell carcinoma would have been more difficult if the clear cell part was missed. The differential diagnoses for those sarcomatoid and rhabdoid part with extensive myxoid background include adult malignant rhabdoid tumor, pleomorphic rhabdomyosarcoma, and renal medullary carcinoma.<sup>(6,7)</sup> The malignant rhabdoid tumor must not contain any part of renal cell carcinoma of any variant.<sup>(2)</sup> To differentiate from the rhabdomyosarcoma, immunohistochemical staining plays an important role. While the rhabdoid cells in renal cell carcinoma show immunoreaction for both cytokeratin and vimentin, pleomorphic rhabdomyosarcoma would express vimentin, desmin, myogenin, myoD1, and no cytokeratin.

Renal medullary carcinoma is also a recent entity of renal tumor that was first described by Davis *et al.* in 1995. The tumor is characterized by rhabdoid or plasmacytoid cells growing in diffuse and glandular patterns with inflammatory infiltrate.<sup>(8)</sup> The tumor has a high incidence among children to young adults with Sickle cell hemoglobinopathy. The histochemical characteristic of the tumor is negative with Hale's colloidal iron, PAS, and d-PAS (PAS with diastase). Immunohistochemically, the tumor cells are strongly positive for low and high molecular weight cytokeratins, whereas vimentin, and desmin are negative.<sup>(7)</sup>

Cytogenetic studies of the tumor in the literature suggested that the clear cell and rhabdoid

parts were clonal in origin by presence of similar cytogenetic alteration in both areas.<sup>(2)</sup>

To our case, the presence of the clear cell part together with histochemical and immunohistochemical studies supported the diagnosis of renal cell carcinoma of which the rhabdoid and sarcomatoid parts are different phenotypes. Cytogenetic study was not performed in our case; therefore clonality of the different phenotypes could not be disclosed.

According to the series of Kuroiwa *et al.*, two and five of eight patients with this tumor presented with stage III and IV (TNM staging), respectively. Four of the five cases with stage IV tumor that had lymph node and lung metastases at presentation died of disease within eight months after surgery. One patient with stage III tumor developed bone metastasis during follow-up.<sup>(3)</sup> One of three patients with the same disease called composite tumor in the series of Shannon *et al.* also had lymph node metastasis at time of presentation.<sup>(2)</sup> The high incidence of metastasis and extrarenal extension of the tumor was also documented by Gökden *et al.*, 10 and 12 of 23 cases (44 % and 52 %), respectively. Although it was not as aggressive as pure renal rhabdoid tumor exclusively found in young children that had up to 73 % of extrarenal extension, it was more aggressive compared with the contemporary renal cell carcinoma without rhabdoid component, 26 % of extrarenal extension.<sup>(1)</sup>

## Conclusion

In addition to the sarcomatoid pattern, the rhabdoid pattern also represents an aggressive phenotype of renal cell carcinoma. It can be found in coexistence with any variants of the contemporary

renal cell carcinoma that was claimed to be clonal in origin, except the chromophobe variant. The rhabdoid phenotype itself is cytologically high-grade. More than half of the patients those had this kind of tumor came with advance stage that gave rise to the unpleasant prognosis. The finding of this rhabdoid phenotype and its extent should always be stated in the pathological report.

### References

1. Gökden N, Nappi O, Swanson PE, Pfeifer JD, Vollmer RT, Wick MR, Humphrey PA. Renal cell carcinoma with rhabdoid features. *Am J Surg Pathol* 2000 Oct; 24(10): 1329 - 38
2. Shannon B, Stan Wisniewski Z, Bentel J, Cohen RJ. Adult rhabdoid renal cell carcinoma. *Arch Pathol Lab Med* 2002 Dec;126(12):1506 - 10
3. Kuroiwa K, Kinoshita Y, Shiratsuchi H, Oshiro Y, Tamiya S, Oda Y, Naito S, Tsuneyoshi M. Renal cell carcinoma with rhabdoid features: an aggressive neoplasm. *Histopathology* 2002 Dec; 41(6): 538 - 48
4. Weeks DA, Beckwith JB, Mierau GW, Zuppan CW. Renal neoplasms mimicking rhabdoid tumor of the kidney. A report from the National Wilms' Tumor Study Pathology Center. *Am J Surg Pathol* 1991 Nov;15(11): 1042 - 54
5. Lee L, Marsh WL Jr, Wen P. Pathologic quiz case: an 82-year-old woman with a renal mass. Renal cell carcinoma with rhabdoid features. *Arch Pathol Lab Med* 2004 Jan; 128(1): 109 - 16
6. Peng HQ, Stanek AE, Teichberg S, Shepard B, Kahn E. Malignant rhabdoid tumor of the kidney in an adult: a case report and review of the literature. *Arch Pathol Lab Med*. 2003 Sep;127(9): e371 - 3
7. Adsay NV, deRoux SJ, Sakr W, Grignon D. Cancer as a marker of genetic medical disease: an unusual case of medullary carcinoma of the kidney. *Am J Surg Pathol* 1998 Feb; 22(2): 260 - 4
8. Davis CJ Jr, Mostofi FK, Sesterhenn IA. Renal medullary carcinoma. The seventh sickle cell nephropathy. *Am J Surg Pathol* 1995 Jan; 19(1): 1 - 11