

FRACTURE RESISTANCE OF ENDODONTICALLY TREATED PREMOLARS WITH DEEP  
CERVICAL LESION RESTORED WITH AND WITHOUT POST IN DIFFERENT  
RESTORATIONS



Miss Phrohphrim Suebsawadphatthana

จุฬาลงกรณ์มหาวิทยาลัย  
CHULALONGKORN UNIVERSITY

A Thesis Submitted in Partial Fulfillment of the Requirements  
for the Degree of Master of Science in Esthetic Restorative and Implant Dentistry

Common Course

Faculty of Dentistry

Chulalongkorn University

Academic Year 2018

Copyright of Chulalongkorn University

ความต้านทานต่อการแตกหักของฟันกรามน้อยบนที่ผ่านการรักษาคลองรากฟันร่วมกับการ  
สูญเสียเนื้อฟันบริเวณคอฟัน ภายหลังจากการบูรณะด้วยเดือยฟันและการบูรณะวิธีต่างๆ



วิทยานิพนธ์นี้เป็นส่วนหนึ่งของการศึกษาตามหลักสูตรปริญญาวิทยาศาสตรมหาบัณฑิต  
สาขาวิชาทันตกรรมบูรณะเพื่อความสวยงามและทันตกรรมรากเทียม ไม่สังกัดภาควิชา/เทียบเท่า

คณะทันตแพทยศาสตร์ จุฬาลงกรณ์มหาวิทยาลัย

ปีการศึกษา 2561

ลิขสิทธิ์ของจุฬาลงกรณ์มหาวิทยาลัย

Thesis Title	FRACTURE RESISTANCE OF ENDODONTICALLY TREATED PRE MOLARS WITH DEEP CERVICAL LESION RESTORED WITH AND WITHOUT POST IN DIFFERENT RESTORATIONS
By	Miss Phrohphrim Suebsawadphatthana
Field of Study	Esthetic Restorative and Implant Dentistry
Thesis Advisor	Associate Professor Chalernpol Leevailoj

---

Accepted by the Faculty of Dentistry, Chulalongkorn University in Partial Fulfillment of the  
Requirement for the Master of Science

..... Dean of the Faculty of Dentistry  
(Assistant Professor Suchit Poolthong, Ph.D.)

THEESIS COMMITTEE

..... Chairman  
(Associate Professor Atiphan Pimkhaokham, Ph.D.)

..... Thesis Advisor  
(Associate Professor Chalernpol Leevailoj)

..... External Examiner  
(Jaruma Sakdee, D.M.Sc.)



จุฬาลงกรณ์มหาวิทยาลัย  
CHULALONGKORN UNIVERSITY



# # 5875826632 : MAJOR ESTHETIC RESTORATIVE AND IMPLANT DENTISTRY

KEYWORD:

Phrohphrim Suebsawadphatthana :  
 FRACTURE RESISTANCE OF ENDODONTICALLY TREATED PREMOLARS WITH DEEP  
 CERVICAL LESION RESTORED WITH AND WITHOUT POST IN DIFFERENT  
 RESTORATIONS. Advisor: Assoc. Prof. Chalernpol Leevailoj

Objectives: The purpose of this study was to evaluate the effects of fiber posts and different restorations on the fracture resistance of endodontically treated maxillary premolars with cervical cavities. Methods: In forty extracted human first maxillary premolars, cervical cavities were prepared simulating cervical lesions and randomly divided into four groups (n=10): COM-NP, endodontically treated teeth (ETT) restored with resin composite without fiber posts; ON-NP, ETT restored with CAD/CAM ceramic onlays without fiber posts; COM-P, ETT restored with resin composite and fiber posts; and CR-P, ETT restored with CAD/CAM ceramic crowns and fiber posts. After the fiber posts and restorations had been cemented with resin cement, all specimens were loaded onto the long axis in a universal testing machine until fracture at a speed of 0.5 mm/min. Fracture load (N) and fracture modes were evaluated in all specimens. The mode of failure was determined by visual inspection. Data were analyzed with one-way ANOVA and Scheffé's tests ( $p < 0.05$ ). Results: Fracture load for all groups were (N): COM-NP ( $933.48 \pm 242.53$ ); ON-NP ( $1871.45 \pm 313.59$ ); COM-P ( $1510.17 \pm 251.87$ ); and CR-P ( $2189.97 \pm 600.38$ ). COM-NP had the lowest fracture resistance, significantly different from those of the other groups ( $p \leq 0.05$ ). Statistically significant differences were observed among groups ( $p \leq 0.05$ ), except in the ON-NP to COM-P and the ON-NP to CR-P groups ( $p = 0.218$ ,  $p = 0.322$ ). All groups showed the non-restorable fracture mode. Conclusion: Cuspal-coverage restorations significantly enhanced the fracture resistance of endodontically treated maxillary premolars with cervical cavities. Placement of fiber posts improved the fracture resistance of endodontically treated teeth but did not make the failure restorable.

Field of Study: Esthetic Restorative and Student's Signature .....

Implant Dentistry

Academic Year: 2018 Advisor's Signature .....

## ACKNOWLEDGEMENTS

I would first like to thank my enthusiastic thesis advisor, Associate Professor Chalernpol Leevailoj. Not only for his tremendous academic support, but also for helping me out so many ways by steered me in the right the direction whenever he thought I needed it. I am hugely appreciative him for sharing his expertise so willingly and for being so dedicated to his role as my advisor. This accomplishment would not have been possible without him.

I would love to thank my dear friends who have kept me going on my path to success. They assisted me get through my hard times and also cheered me up when I was down. Thank you for being great companion, loved, supported, encouraged, entertained, and helped me get through this agonizing period in the most positive way.

Nobody has been more important to me in this pursuit than the members of my family. Most importantly, I would like to thank my loving mother for her unconditional love, soothing guidance and continuous encouragement throughout my years of study. Moreover, I wish to thank my caring and supportive brother who is my role model and provide unending inspiration. None of this would have been possible without love and patience from them.

Phrohphrim Suebsawadphatthana

## TABLE OF CONTENTS

	Page
ABSTRACT (THAI).....	iii
ABSTRACT (ENGLISH) .....	iv
ACKNOWLEDGEMENTS.....	v
TABLE OF CONTENTS.....	vi
LIST OF FIGURES .....	1
LIST OF TABLES.....	2
CHAPTER I .....	3
INTRODUCTIONS .....	3
Research Objectives .....	6
Hypotheses.....	6
Keywords.....	6
Conceptual framework .....	7
Expected Benefit from the study.....	8
Limitations.....	8
CHAPTER II .....	9
REVIEW OF LITERATURES.....	9
Non-carious cervical lesions.....	11
Abfraction .....	12
Endodontically treated tooth .....	13
Canal configuration .....	13
Cause of weakness of endodontically treated teeth.....	15

Effect of remaining tooth structure on fracture resistance.....	16
Cuspal deflection.....	18
Success and failure of endodontically treated tooth .....	20
Restorative techniques for endodontically treated tooth.....	22
Post Placement.....	23
Resin Composite restoration .....	24
Ceramic onlay.....	25
Ceramic crown .....	27
Digital technology .....	29
CAD/CAM .....	29
e.max CAD .....	30
Compressive fracture resistance test.....	31
Load type.....	31
Load application area .....	31
Load speed .....	32
Load intensity.....	32
Angle of load application .....	32
CHAPTER III .....	34
MATERIALS AND METHOD.....	34
Research Design .....	34
Research Methodology .....	34
Dental Materials.....	35
Tooth preparation and root canal filling .....	36



Post space preparation .....	39
Fiber post luting procedure.....	40
Onlay preparation.....	41
Crown preparation.....	43
Compressive Fracture Resistance Testing .....	44
CHAPTER IV .....	46
RESULTS .....	46
CHAPTER V .....	48
DISCUSSION.....	48
CHAPTER VI .....	54
CONCLUSION.....	54
APPENDIX .....	55
REFERENCES.....	61
VITA .....	73

## LIST OF FIGURES

PAGE

Figure 1 conceptual framework .....	7
Figure 2 Research Methodology .....	34
Figure 3 The division of specimens into groups .....	37
Figure 4 Teeth were placed 3 mm up from cementoenamel junction (CEJ).....	41
Figure 5 specimens were tested using a universal machine .....	44
Figure 6 Mode of failure classification .....	45
Figure 7 Initial films in tooth selection .....	55
Figure 8 Specimens after canal obturation for COM-NP and ON-NP group .....	56
Figure 9 Specimens after try fiber post for COM-P and CR-P .....	56
Figure 10 Restorable specimens .....	57
Figure 11 Unrestorable specimens in COM-NP .....	58
Figure 12 Unrestorable specimens in ON-NP .....	59
Figure 13 Unrestorable specimens in COM-P .....	60
Figure 14 Unrestorable specimens in CR-P .....	60

## LIST OF TABLES

	PAGE
Table 1 Materials used in the study .....	35
Table 2 Equipments used in the study.....	36
Table 3 Mean value of fracture resistance of the tested groups .....	46
Table 4 Fracture modes of the tested groups .....	47



## CHAPTER I

### INTRODUCTIONS

Endodontically treated teeth (ETT) are usually characterized by essential coronal and radicular tooth structure loss as a result of dental caries, previous restorations, and endodontic access preparation that negatively influenced tooth strength.(1, 2) The primary cause of extraction among endodontically treated teeth is tooth fracture related primarily to improper prosthetic restorations.(3, 4) The longevity of endodontically treated teeth depends not only on the use of conservative endodontic procedures but also on appropriate coronal restoration of the tooth.(3, 5, 6) The remaining tooth structure is the most effective parameter in the selection of proper restorations because it is considered significance in resisting the fracture of ETT.(7-10) The greatest preservation of remaining tooth structure showed higher fracture resistance and also increased the survival rates of endodontically treated teeth.(7, 11-14) Among posterior teeth, the highest rate of clinical fractures was in maxillary premolars due to unfavorable anatomic shape, making them more susceptible to cusp fracture.(15, 16) In addition to the tooth structure lost during endodontic treatment, non-carious wedge-shaped cervical lesions are another factor reported to occur significantly in premolars, further

weakening tooth strength.(17-20) The association of these factors probably makes premolar teeth more susceptible to fracture.(19)

Today, different principles and materials can be used to restore endodontically treated teeth, from conservative alternative to progressive approaches. As a conservative concept for endodontic preparation restricted to endodontic access, direct composites can be used as definitive restorations to avoid further tooth preparation, which weakens tooth strength.(8, 10, 14, 21, 22) *In vitro*, a high fracture resistance of ETT restored with resin composite has been reported.(23, 24) However, as a protective concept, posterior ETT should receive a cuspal-coverage crown restoration to protect the teeth from fracture. Several studies have reported that cuspal-coverage restorations significantly improved the success rate and longevity of endodontically treated posterior teeth.(4, 6, 10, 14) Additionally, posts are another option being used to restore ETT.

Posts are normally used only to retain the core material of ETT, but they do not reinforce the root.(4) Moreover, post space preparation can damage residual tooth structure, causing the root to weaken and the mechanical resistance of treated teeth to be decreased. However, several studies reported that posts increased the fracture resistance of endodontically treated teeth.(25) Fiber posts have been suggested as an alternative to metal posts because they have a modulus of elasticity similar to root dentin which improves stress distribution and avoids force concentration at the post-dentin interface.(26-28) One clinical study indicated significantly greater clinical success for

premolars restored with posts compared with teeth that had been restored without posts.(27) However, laboratory studies did not show significantly increased fracture resistance for molars and premolars restored with fiber posts. (12)

Although endodontically treated teeth have been extensively studied, the choice of an optimal restorative method (conservative or protective approach) and material to restore non-vital teeth remains controversial. Based on the author's literature review, there are no publications on the association between endodontically treated premolars and deep cervical lesions. Thus, the purposes of this study were to measure the different modes of restoration after endodontic procedures with deep cervical lesions to assess the resistance to fracture of these teeth under simulated occlusal load.

### Research Objectives

The purpose of this study is to measure the different modes of restoration after endodontic procedures with deep cervical lesions to assess the resistance to fracture and mode of failure of these teeth under simulated occlusal load.

### Hypotheses

The null hypotheses were that the restorations and fiber post have no effect on the fracture resistance of restored endodontically treated maxillary premolars and no effect on fracture modes.

### Keywords

Fracture load, onlay, CAD/CAM, fiber post

Conceptual framework

Population: 40 Human maxillary premolars

Intervention: Four types of restorations: direct composite filling without fiber post,

CAD/CAM onlay without fiber post, direct composite filling with fiber post, CAD/CAM full-coverage crown with fiber post

Outcome measurement: Record the loading force from universal testing machine that appear as a result of specimen fracture and classify fracture mode by evaluate fracture location

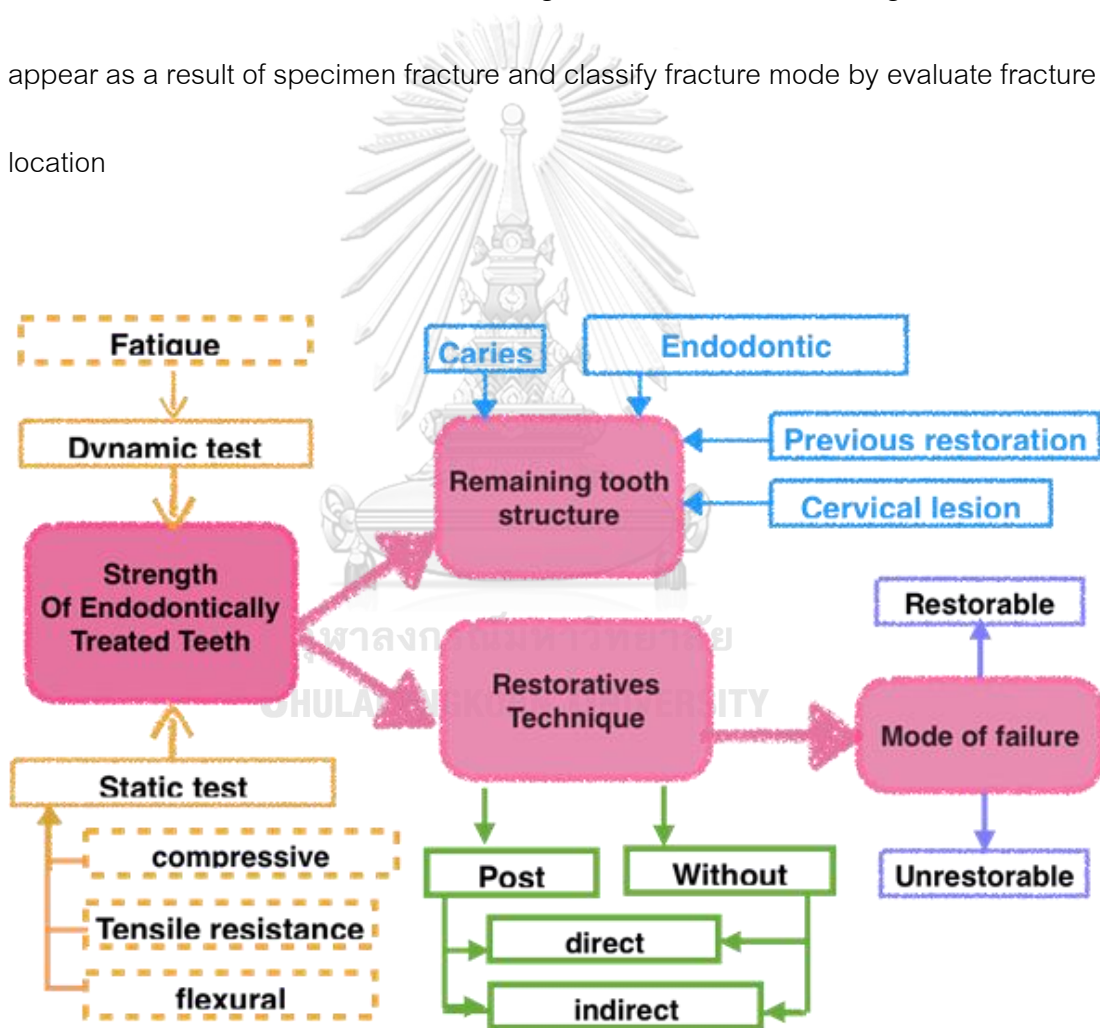


Figure 1 conceptual framework



#### Expected Benefit from the study

The results from this study will assist clinician to make a decision of which restoration should be used after root canal treatment in deep cervical lesion teeth or even be the background for a further clinical study in the same field of interest. Besides, enhance the ability to restore an endodontically treated tooth to its original strength without placement a full coverage crown restoration which provided periodontal and economic benefits to patients.

#### Limitations

1. There are differences in each tooth size which could not be controlled due to natural variations in tooth morphology. However, the randomized process will reduce systemic bias.
2. One brand of post (D. T. Light post) and ceramic system (IPS e-max CAD) will be chosen to represent the conventional fiber post and lithium disilicate ceramics, so the results from this study may not be able to imply with other brands and other types of materials.

## CHAPTER II

### REVIEW OF LITERATURES

- Non-carious cervical lesions
  - Abfraction
- Endodontically treated tooth
  - Canal configuration
  - Cause of weakness of endodontically treated teeth
  - Effect of remaining tooth structure
  - Cuspal deflection
  - Success and failure of endodontically treated tooth
- Restorative techniques for endodontically treated tooth
  - Post placement
  - Type of post
    - Resin composite restoration
    - Ceramic onlay
    - Ceramic crown
- Digital technology
  - CAD/CAM
    - e.max CAD

- Compressive fracture resistance test

Load type

Load application

Load speed

Load intensity

Angle of load application



### Non-carious cervical lesions

The term non-carious cervical lesion (NCCL) are defined as the loss of tooth substance at the cemento-enamel junction.(29) Later, Grippo et al. classified NCCL into four types of tooth wear. First, attrition is the wear away of tooth as a result of tooth to tooth contact during mastication. Second, abrasion is tooth wear from biomechanical frictional processes for example tooth brushing. Third, erosion is the loss of tooth substance by acid dissolution of either an intrinsic or extrinsic origin. Finally, abfraction is the pathologic loss of tooth substance caused by biomechanical loading forces. These lesions were caused by flexure of the tooth during loading leading to fatigue of the enamel and dentine at a location away from the point of loading.(30) Several studies reported the prevalence of cervical lesion were found most frequently at buccal surface of maxillary teeth. The prevalence and severity of lesions have been also related to age.(18, 31) From Tomasik et al. study, they evaluated frequency of cervical lesions with pulp exposure. The study was done in 124 patients, found that very deep defects with pulp exposure were found in 44 teeth. This study also confirmed the relationship between occlusal pathology and cervical lesions.(32) Supporting by Levitch et al. study that also found an incidence of NCCL that involved pulp tissue.(31)

### Abfraction

The word "abfraction" was derived from the Latin "to break away".(30) These lesions have multifactorial etiology combining of occlusal stress, abrasion and erosion.(33, 34) The primary factor that initiates these lesions is tensile stress caused by mastication and malocclusion after that oral habit plays a secondary role in dissolution of the tooth structure to create the lesion.(18, 34) The process starts from excessive forces occurred, the tensile stresses transferred to cervical fulcrum area during bending resulting in disruption of the enamel crystalline structures and underlying dentin leading to cracks, chips and rupture. As a result, the disrupted tooth structure is more susceptible to loss through dissolution, acid and abrasion then results in the development of the typically wedge-shaped lesions. Moreover, this process continues repeatedly over times making the lesion broader if it left untreated.(34, 35) Dental structure loss from cervical lesion was assumed to reduce the resistance of tooth and increasing the possibility of fracture.(19) In addition, the formation of a cervical wedge-shaped lesion also adversely affects the dental biomechanical behavior leading to an alteration in stress and strain distribution pattern when the tooth is loaded.(36) There was a study confirmed that tooth structure loss at cervical area increase the stress concentration at center of NCCLs by Soares et al. (19) The key characteristics to diagnose abfraction are the lesion would be a wedge-shaped morphology with sharp line angles frequents at subgingival location, mostly involving a single tooth, presence of

lateral occlusal force during mastication or parafunctional movements, loss of anterior guidance and the misorientation of the tooth's long axis in relation to occlusal forces.

The size of the lesion would be directly related to the magnitude and frequency of the force.(34, 35, 37) The lesions found more severely affected in maxillary teeth and first premolars were the worst affected teeth. (18, 38) Restoration with resin composite with an appropriate modulus of elasticity with dentine adhesive system can be an effective and non-destructive means of restoring these lesions by prevent further stress concentration which may lead to pulpal exposure or fracture.(18, 19, 35)

#### Endodontically treated tooth

##### Canal configuration

The canal configuration can be classified in many systems. The first categories of root canal configurations presented by Weine *et al.* in 1969 into four types.(39) Later in 1984, Vertucci classified the canal configuration into eight types, which is more delicate and most commonly use as follow:(40, 41)

Type I : A single canal from the pulp chamber to apex.

Type II : Two canals separate from pulp chamber and join to form one canal to apex.

Type III : A single canal from pulp chamber and separate to form two canal at the middle of the root, and merge into one canal at the apex.

Type IV : Two canal separate from the pulp chamber to apex.

Type V : A single canal from pulp chamber and divides into two separate canals to apex.

Type VI : Two canals separate from pulp chamber and join to form one canal at the middle of the root, and divides into two separate canals to apex.

Type VII : A single canal from pulp chamber and divides into two separate canals, and join canal before separate into two short canal again at the apex.

Type VIII : Three canal separate from the pulp chamber to apex.

Although many studies from different nationalities found single root form was most common in maxillary first premolar. (41-43) Recent study found most prevalent root canal frequency was the two roots with two canals.(44, 45) Canal configuration type IV tend to be most prevalent.(41-43)Over the years, many results found the canal configuration varies from Vertucci's classification such as Gulabivala K et al., Sert S and Bayirli GS., Peiris H et al., and Al-Qudah AA.(46-49)All classification had their advantages and limitations. Therefore, new classifications were established by few researchers to create a simple, accurate and practical system to identified. Ahmed H.M.A. in 2016 created a system include tooth number, the number of roots, and the root canal configuration.(49) Rashmi Bansal et al. in 2018 included a nomenclature of tooth, the characteristic of tooth type, anatomic variations, and number of roots and course of canal in each root.(50)There are various techniques to investigate the root canal morphology such as tooth decalcification and dye injection, sectioning of the teeth

and radiographic studies *in vitro*,<sup>(51)</sup> alternative radiographic techniques,<sup>(52)</sup> and radiographic assessment enhanced with contrast media.<sup>(53)</sup> The significance of canal configuration studies in the maxillary first premolar is to acknowledge the complication and difficulty of endodontic treatment. Variation in root canal anatomy is common and it is important for successful endodontic treatment.<sup>(41)</sup> Maxillary first premolar is considered to be the most difficult teeth to be treated endodontically from this following factors; variation of roots, canal configuration, the direction and longitudinal depressions of the roots and various pulp cavity configuration.<sup>(54)</sup> Study of root canal anatomy could dictate the location of the initial entry of access and the size of the first files used which help dentists diagnose precisely and also reduce error of endodontic treatment.<sup>(42, 55)</sup> In the study of Vertucci and Gupta found that maxillary first premolar was the only tooth that found all eight types of root canal configuration.<sup>(41, 55)</sup>



จุฬาลงกรณ์มหาวิทยาลัย  
CHULALONGKORN UNIVERSITY

#### Cause of weakness of endodontically treated teeth

Some previous classic studies believed that dentine in endodontically treated teeth is dramatically different from dentine in normal teeth because it was more brittle resulting from water and collagen loss. Helfer et al. showed endodontically treated teeth contained 9% less moisture compared to vital teeth. <sup>(56)</sup> Later, several studies established evidence contrast to primary study. Huang et al. compared the physical and mechanical properties of dentine specimens from teeth with and without endodontic



treatment. They concluded that both dehydration and endodontic treatment can cause degradation of the physical or mechanical properties of dentine. (57) The tooth strength is reduced in proportion to coronal dental structure lost resulting from either carious lesions or restorative procedures. There is a direct relationship between the amount of remaining tooth structure and the ability to resist occlusal forces mentioned in next topic.(9)

In addition, not only extensive coronal dentine removal but also endodontic procedure such as instrumentation of the root canal, irrigation of the canal with sodium hypochlorite, obturation, post space preparation and final coronal restoration which lead to a loss of tooth structure or may weaken the dentine. (58, 59)

Fracture rate are higher in endodontically-treated posterior teeth. There was a report claimed that nearly one third of endodontically-treated maxillary premolars have been fractured within the first 3 years.(60) Moreover, Fennis et al. showed more than 46,000 patients reported fractures in root canal treatment teeth and concluded a positive correlation between history of endodontic treatment and subgingival fracture location.(61)

#### Effect of remaining tooth structure on fracture resistance

Sound teeth hardly have been fractured under normal function. For endodontically treated teeth, the amount of coronal dentine removal directly increase the potential of

fracture. (9) Therefore many studies have highlighted the essential of preserving remaining coronal tooth structure to maintain the strength of the tooth. (9, 11, 13, 15)

There is study on endodontically treated premolars with only access preparation at occlusal surface with intact marginal ridges showed similar compressive fracture strength to an intact tooth. (22) Similarity to previous study by Reeh et al. revealed that the loss of the marginal ridge integrity resulting in the dramatic loss of stiffness by showing only 5% decrease in stiffness among premolars when only endodontic access preparation. On the contrary, endodontic access cavity preparation with occlusal and MOD preparation decreased tooth stiffness by 20% and 63% respectively (1) Also, these findings are supported by a study performed by Caplan that teeth with two proximal ridges were three times less strength than teeth loss one or no proximal contact. (62) Nissan et al. evaluated fracture resistance of endodontically treated maxillary first premolars by varying degrees of remaining coronal structure and found that remaining coronal structure was the major factor that influenced the fracture resistance. (13) Radicular dentine tissue (RDT) after post preparation is also considered as an important factor because excessive removal of radicular dentine would compromise the root. There is a direct relationship exists between the RDT and the strength of the root.(63)

### Cuspal deflection

The restorative and endodontic procedures can extent of cuspal flexure and has consequences for fracture.(64) Nowadays, composite material has been used widely. The main problem of this material is the polymerization shrinkage during curing as a result found tooth structure and wall of cavity had an internal stress and deformation.(65, 66) This stress can lead bond failure, cuspal deflection, enamel microcracking, pulpal irritation, secondary caries and postoperative sensitivity.(67) Cusp deflection is movement of the cusp tips from polymerization shrinkage of the composite interact with elastic deformation of the cavity wall.(68) With a masticatory load, the isthmus of the preparation weakens the tooth.(69) It showed 10-45  $\mu\text{m}$  of deflection depended on measuring method and instrument, type of tooth and size of cavity.(70) There was a study in premolars of direct and indirect MOD restorations compared to intact teeth and unrestored teeth with an inlay preparation. This study revealed the same result between both direct and indirect (with composite and lithium disilicate) restoration and sound teeth. Therefore, the restoration decrease the cuspal deflection, and improve the cuspal reinforcement than the unrestored teeth.(71) Same results were found in study by Jensen et al and Cötert et al stated that both direct composite and indirect ceramic restorations had resistance similar to intact teeth.(72, 73) When compare the teeth

restored with amalgam and composite, the results showed amalgam has 17% of cuspal deflection while composite resin has 54 to 99%.<sup>(74)</sup> Indirect restorations have better physical properties than direct composite restorations because they are well fabricated under control condition in laboratory.<sup>(75)</sup> Ceramic inlays show biological compatibility, adequate compressive strength, similar thermal conductivity to dental tissues, marginal integrity, color stability and a resistance to fracture similar to other types of restorative materials when used in MOD inlay restorations.<sup>(72)</sup> Furthermore, Zamboni et al. stated that the adhesive is one of the crucial factor that affected to the cuspal reinforcement between inlay restorations and tooth.<sup>(71)</sup> In endodontically treated tooth, if marginal ridges and dentin above the pulp chamber were removed it will increasing occlusal loads, or deeper cavity preparation which can related to a higher cuspal deflection.<sup>(76-78)</sup> The endodontic access increased cuspal deflections 10  $\mu\text{m}$ .<sup>(79)</sup> The study found that glass ionomer significantly reduced tooth strain and marginal leakage. Therefore, a placement of a glass ionomer base are recommended if endodontically treated teeth directly restore with resin composite.<sup>(78)</sup> Temporary filling played an important role of causing hygroscopic expansion and cuspal reflection while root canal treatment was in process. It can leads to cuspal fracture so Eskandarizadeh et al. recommended to use temporary material in short time.<sup>(80)</sup> However, clinical longevity of endodontically treated posterior teeth especially molars and bicuspid is significantly improved with coronal coverage. (4, 6, 14, 79) There are a relation between the type of coronal

reconstruction and the survival rate of endodontically treated teeth. Teeth without full cusp coverage had 5 or 6 times of failure than fully restoration teeth. (3, 6, 81, 82)

Sorensen and Martinoff (4) further investigated the survival rate according to the group of teeth and found that the rate of clinical success was significantly improved with coronal coverage of posterior teeth but not for anterior. In conclusion, the key factor of success is proper select the best technique and material to support remaining tooth structure for optimum strength and suitable for functional demands.

#### Success and failure of endodontically treated tooth

Endodontic treatment reported success rates up to 86–98% (83) and an initial non-surgical endodontic treatment are estimates as 97% .(81) An successful endodontically treated tooth should be frequent follow up clinically and radiographically after treatment.(84) The criteria that describe success of endodontically treated tooth are

- 1)The treated tooth is asymptomatic and functional. 2) Soft tissue appears normal and responds normally to manual examination. 3) Radiograph reveals a normal lamina Dura.(85)

Failure of endodontically treated teeth can be presented with dental pain and lead to tooth extraction. The teeth that failed most frequently were mandibular first molars (86-88)and the teeth that failed least frequently were maxillary third molars.(86)

Vire et al. divided failures after root canal treatment base on etiology into three types; unrestorable tooth fractures, periodontal problems and endodontic failures. These

researchers also found that 59% of failure were prosthetic failure which related with improper final restoration.(3) Failure of posterior endodontically treated teeth without cusp coverage has been reported.(4) The evidence showed 6 times greater rate of failure of uncrown tooth than crown restoration of endodontically treated tooth.(6) The extraction of teeth without full cuspal coverage were explained as loss of tooth structure.(1) Teeth with crown restoration had better success outcome of longevity more than uncrown teeth because crown enhance the resistance of posterior teeth to fracture.(3, 4) Some studies showed that the most common reason for the extraction was from prosthetic reasons. (3, 86, 89)In contrast, a prospective study of Touré in 2011 revealed periodontal disease was the most factor for extraction but 94% of extracted teeth had restoration without full cuspal coverage, followed by endodontic failure, and nonrestorable tooth damage caused by fracture or caries.(87) During endodontic treatment, many factors can initiated a failure, for example, persistence of intra and extra-canal bacteria (intra-canal and extra-canal), inadequate filling of the canal, overextensions of root filling materials, leakage from improper coronal seal (leakage), untreated canals (both major and accessory), iatrogenic procedural errors, complications of instrumentation.(84) The failure of true endodontic origin is less frequent but occurs faster than other problem.(3)

There are many factors described success and failure other than main factors; gender, education, smoking status, as well as tooth type and coronal restoration are

indicated for extraction procedure.(88) On the contrary, gender, educational level, or smoking status did not show any differences when compared with reasons for extraction in Touré's study.(87) Age of patient is one factor of success in endodontic treatment. Younger group patient had failure rate more than elderly because in young patient has large-diameter canals and older patient has the tighter apical foramina, lack of completely patent auxiliary canals and dense periapical bone in older teeth.(90)

#### **Restorative techniques for endodontically treated tooth**

A successful clinical outcome for endodontically-treated teeth depends not only on a successful root canal treatment but also subsequent restorative treatment.(91) Therefore, researcher has been focused on finding the optimal post and core system,(92) luting agent(93)and crown type.(94) Ray et al. established the relationship between the quality of the coronal restoration and root canal filling by examining radiographs of endodontically-treated teeth. They observed a combination of proper restorations and good endodontic treatments resulting in absence of periapical inflammation in 91.4% of the teeth, whereas poor restorations and poor endodontic treatments resulted in periradicular inflammation in 82.9% of the teeth they studied. (95) Several studies advocated different effective coronal reinforcement of tooth structure with bonded restorations in order to increase fracture resistance

### Post Placement

The primary purpose of post placement is to retain a core in a tooth with extensive loss of coronal tooth structure in order to support final restoration.(8, 96-98) Some studies believe that post does not increase fracture resistance of restored teeth and also weaken tooth strength in some degree from removal radicular structure for post space preparation.(97) Placing post to reach its purpose, several contributing factors should be considered: post diameter; post length; canal configuration and post material. Post and core selection should be based on the maximum of tooth structure could be preserved.(13) The placement of posts may increase the chances of root fracture and lead to treatment failure.(99) For reason mention earlier, post was used restrictively only when core retention are required.(28) Endodontic posts have been classified according to fabrication into major two groups: custom-made cast post and cores (laboratory-fabricated) and prefabricated post and cores for direct-placement. The disadvantage of the cast post and core is its rigidity tend to increase chance of root fracture. The ideal post and core material should have modulus of elasticity and coefficient of thermal expansion similar to dentin. Also, the material should bond easily and firmly to dentin to preserve radicular dentin removal so that the entire unit of a post and core resembles the original tooth. Introducing fiber-reinforced post which are fabricated to bond with most resin cements and resin-based composite core materials. From these benefits,



fiber posts tend to decrease occurrence of root fracture.(2, 96) Many studies confirmed that failure when endodontically treated teeth restored with fiber post teeth are more likely to be restorable such as displacement or detachment.(2, 100) In addition, fiber posts can be removed and replaced easily without the risk of perforating the root.(25) In 2015, Parasi et al. conducted a retrospective study that evaluated clinical outcome of fiber post, the results showed no root fracture were found and the success rate were 85% in average 6 years after post placement. The most failure was post debonding and after restored again found that overall survival rate were 98%.(101)

#### Resin Composite restoration

In recent years, there is an increasing trend toward minimal intervention dentistry. Physical properties of composite resin have been improved and the introduction of adhesive systems have offered new potential for the restoration of endodontically treated teeth. Also, resin composites with good bonding ability transmit and distribute functional stresses and hold the potential to reinforce weakened tooth structure. Oliveira et al. concluded that the most important factor influencing the strength of endodontic treated teeth especially premolars was the amount of remaining tooth structure. When tooth is not experienced to fracture or dramatic damage, simple restoration like resin composite is sufficient to restore an endodontic access. Supporting by Reeh et al. evaluated the potential for alternative restorative techniques with non-vital teeth. The

results showed that composite restorations with adhesives had relative mechanical properties close to sound tooth.(77) Likewise, Steele et al. study found that fracture resistance in endodontically treated premolars with canal access only is similar to natural teeth so direct composites restoration associated to bonding agents may succeed when no other structural loss.(22) These materials have been preferred instead of very rigid materials such as full-coverage ceramics crown when restoring non-vital teeth with no extensive loss of structure.(21, 102) The major advantage of resin composite is the ability to bond to tooth structure and fiber posts so it can be the component that was allowed ceramic crown bonded.(28) On the contrary, resin composite showed its disadvantage from shrinkage during polymerization causing gap formation and also undergoes plastic deformation under repeated loads due to water absorption.(103) When there is adequate dentin, resin composite restorations showed better clinical performance in preventing tooth fractures in endodontically treated teeth than amalgam restorations.(60)

#### Ceramic onlay

Indirect full coverage restorations have some disadvantages including: the high cost of the laboratory procedure; the significant amount of sound tooth structure that has to be removed and the considerable treatment time spent on such complex

restorations.(104) Partial coverage restorations conserve more tooth structure than a complete coverage restoration. Only few studies have been published addressing the advantages and disadvantages of partial coverage restorations for teeth. There are several studies compared the differences in the amount of tooth structure removal of partial restoration in comparison with conventional complete coverage restorations.

Edelhoff et al. showed that preparation for onlay could decrease 67.5–72.3% tooth loss resulting from conventional crown preparation to only 5.5–27.2% when onlay preparation were performed.(105) The greater remaining tooth structure remain, the more strength he endodontically treated teeth occupied. (1, 6, 7, 16, 106) In addition, placing margin supragingivally for onlay avoid periodontal irritation, gingival inflammation and easily detected margin.(107, 108) According to Aquilino and colleagues in 2002 stated that other forms of coronal coverage, such as gold, ceramic or resin composite onlays could provide RCT teeth with protection against fracture compared to full coverage crown.(6)

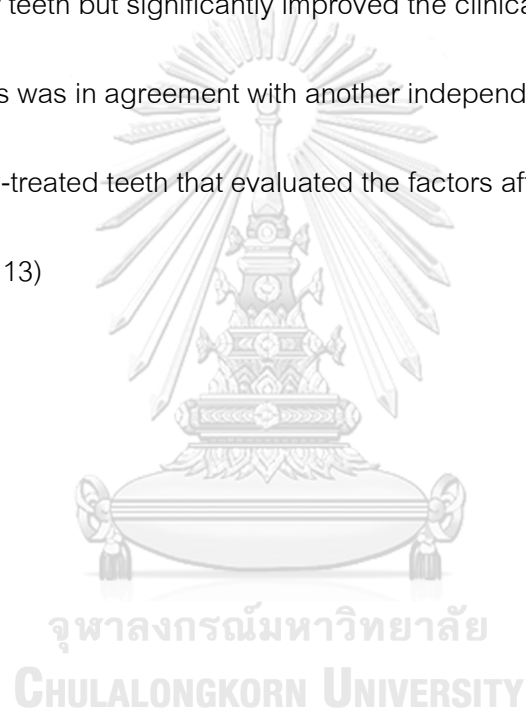
Moreover, several studies support that endodontically treated maxillary premolars should restore with cuspal coverage restorations to protect and reduce the risk of fracture. (6, 7, 10) When fracture occur, cuspal coverage were considered to avoid vertical fracture at the cemento-enamel junction especially when teeth experienced lateral forces because fractures in cuspal coverage mostly occurred within the restorative materials.(109, 110) Currently, evidence for the relative effectiveness of conventional fillings over crowns for the restoration of root canal treated-teeth is

inconclusive. Until more clinical data available clinicians will base their decisions on their own clinical experience, taking into consideration the individual circumstances and preferences of their patients.

### Ceramic crown

There is a strong conclusion from available data that cuspal coverage restorations should be final restoration for posterior root-canal treated teeth especially when the cusps have been weakened.(28, 111) Cuspal coverage with bonded resin composite, amalgam, cast metal alloy, or high-strength ceramic materials is essential to prevent tooth fractures. An *in vitro* study by Panitvisai and Messer(64) showed that access preparations result in greater cuspal flexure, increasing the probability of cuspal fracture. A systematic review 150 of single restorations in endodontically-treated teeth reported that the estimated survivals were 81% for crowned teeth and 63% for direct restorations (resin composites, amalgams, cements) at 10 years. Aquilino and Caplan(6) found a strong association between crown placement and the survival of endodontically-treated teeth. They reported that root-filled teeth without crowns were lost at a six times greater rate than teeth with crowns. They suggested cusp coverage to restore the fracture resistance because they protect cusps from the outward deflection. Smales and Hawthorne(112) reported lower 15-year survival rates for complex cusp-covering

amalgam restorations (48%) compared to crowns (89%). One of the most often cited series of studies on endodontically-treated teeth by Sorensen and Martinoff<sup>1</sup>(4, 99) evaluated the effect of tooth location, coronal coverage, and intracoronal reinforcement on the success of 1273 root-canal treated teeth over an observation period of 1 to 25 years. The results indicated that crown placement had no significant effect on the success of anterior teeth but significantly improved the clinical success rates of posterior teeth. This was in agreement with another independent, retrospective study of 608 endodontically-treated teeth that evaluated the factors affecting their survival during a 10-year period.(113)



## Digital technology

### CAD/CAM

CAD/CAM systems are composed of three components: a scanner, software that processes the data for fabrication of a restoration and milling machine. The first two parts of the system were called CAD phase while the third were the CAM phase.(114)

The overall process started from Omnicam record video with natural color from the patient's intraoral with a scanner and saved data as STL file then software began converting the data to milling machine to mill restoration.(115)

### CEREC System

The CEREC 1 System by Sirona was introduced in year 1987. Currently the most predominant CEREC system is CEREC OmniCam which marketed in 2012. The Omnicam imaging technology is a continuous imaging mode with powder-free scanning. The advantages of powder-free is easier for large working area such as quadrant or entire arch. Moreover, it provides precise 3D images with natural color.(116)The camera tip should be held a few millimeters away from the tooth surface or should slightly touch the surface. After scanning, the preparation is projected on the monitor and analyzed in different views then biogeneric suggests an ideal restoration design. After that dentist approves the restoration then inserts a block in milling machine. (117)

### e.max CAD

In 2006, A monolithic lithium disilicate CAD/CAM ceramic e.max CAD (Ivoclar Vivadent) was launched in market with their flexure strength at 350-450 MPa which are three times greater than leucite-reinforced dental ceramics.(118) These blocks are fabricated in pre-crystallized blue state with A–D and bleach in 3 degree of translucencies available. The blue ceramic has a flexural strength of average 130 MPa but after milling, re-crystallization takes place under ceramic oven for 20–25 min. After this process the block changes its color to the chosen shade and translucency and strength increases dramatically to 360 MPa.(119) e.max CAD is recommended for inlays, onlays, veneers, anterior and posterior crowns, implant supported crowns and anterior bridges.(120) There are several studies showed short-term clinical trials for this material using as single crowns and demonstrated survival rates between 97.4% 115 and 100%. (121-123)

### Compressive fracture resistance test

Loading conditions used to investigate fracture resistance of endodontically treated teeth, there are many features should be reviewed as following.

#### Load type

There are two options which are static and dynamic loads that could be applied for testing fracture resistance of endodontically treated teeth. Static forces are used to evaluate mechanical properties of a material such as toughness, stiffness or static strength whereas dynamic forces are used to evaluate mechanical properties during function over time. Advantages of static test are easier to use, less time consuming and less expensive. (12)

#### Load application area

Load application are related to tooth anatomy and type of tooth. The direction of loads used in testing premolar teeth varies in reported studies and includes being applied to: the triangular ridge of the functional cusp, supporting cusp or to the center of the occlusal surface in contact with both cusp inclines parallel to the long axis of the tooth. (12, 124) From previous studies when the fracture resistance of endodontically treated maxillary premolars were examined, the load from the center of occlusal surface has been achieved as the best load simulation of occlusion.(12, 14, 124, 125) Hannig et al. suggested the importance of applying loads in unaltered areas of teeth not



tooth/restoration interface to achieve reliable results and to avoid the influence of other factors. (125)

#### Load speed

Speed of load application should simulate oral condition during functions. Most studies are performed with crosshead speed ranging from 0.5 to 2 mm/min which considered as optimal speed.(124, 125)With high crosshead speed, it would be difficult to generate homogeneous stress for both tooth tissues and restorative materials whereas low speed would not be representative of the oral functions.(12)

#### Load intensity

In static load applications, teeth have always been loaded from 0 Newtons until fracture occurred in order to record the maximum fracture resistance data. On the contrary, in dynamic tests a proper load has been chosen based on material. (12, 124, 125)

#### Angle of load application

According to teeth anatomy and location, each tooth is subjected to different loading condition due to their specific function. As a consequence, posterior teeth have to withstand vertical forces in term of masticatory forces whereas anterior teeth are responsible for non-axial forces. (14) It has been well documented that fracture resistance of teeth depends on the angle of applied load and axial forces are less

detrimental compared to non-axial load. Direction of loads is an important factor to the longevity of endodontically treated teeth. Reviewing the literature, experimental load angulation remains a controversial subject. When load was applied directly to the cusps, it may lead to mechanical failure of adhesive restorative systems.(14) Moreover, natural variations in tooth morphology may affect the long-term success of restorations. Different kind of forces could be applied to assess fracture resistance such as compression, shear and tension. However, by using static load, resistance to fracture have usually been performed with compressive tests till fractures occurred. When anterior teeth are tested such as maxillary incisors, the load have been usually placed at  $130^{\circ}$  to the longitudinal axis of teeth which described as a simulation of incisor guidance. On the contrary, when posterior teeth are investigated, forces usually placed either at supporting cusps in angulation ranging between  $130^{\circ}$ - $150^{\circ}$  to the longitudinal axis or applied loads parallel perpendicular to cusp slopes. Many authors applied loads parallel to teeth longitudinal axes in order to distribute the stresses more evenly between the residual dental tissues and the restorative material simulating a physiological occlusion. Also it was claimed that fractures occurred from teeth itself and avoided the influence from restorative material.(12, 94, 124, 125)

## CHAPTER III

### MATERIALS AND METHOD

#### Research Design

The experimental study will be carried out as a randomized controlled trial.

Interventions of this study are type of restorations. Dependent variable is load to crack or fracture of the specimens, measured in Newton.

#### Research Methodology

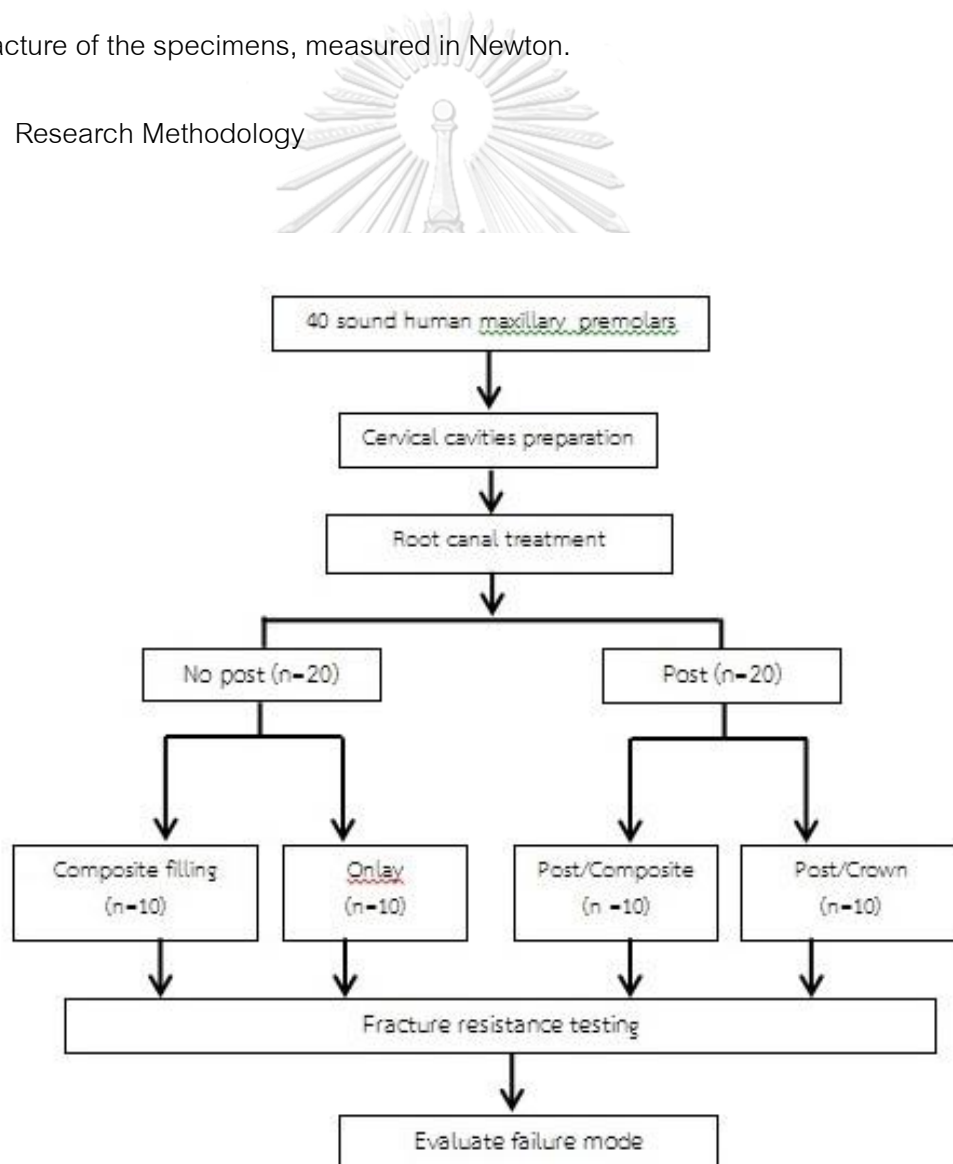


Figure 2 Research Methodology

## Dental Materials

*Table 1 Materials used in the study*

Materials	Manufacturer
ProTaper Next	Dentsply Maillefer, Ballaigues, Switzerland
K-Flex file	Kerr Sybron, Romulus, MI, USA
AH Plus	Dentsply, DeTrey, Konstanz, Germany
D.T. Light-Post	Bisco Inc., Schaumburg, IL, USA
Panavia SA Cement Plus	Kuraray, New York, USA
IPS e.max CAD block A1 LT	Ivoclar Vivadent, Schann, Liechtenstein
Premise, syringe type A2	Kerr, Orange, CA
NX3 Nexus(clear) 3 <sup>rd</sup> Generation	Kerr, Orange, CA
Gel Etchant : 37.5% H <sub>3</sub> (PO) <sub>4</sub>	Kerr, Orange, CA
OptiBond FL Primer and Adhesive	Kerr, Orange, CA
OptiBond Solo Plus	Kerr, Orange, CA
Silane Primer	Kerr, Orange, CA
9.5 % HF Porcelain etchant	Bisco,Schaumburg, IL, USA)

*Table 2 Equipments used in the study*

Equipment	Manufacturer
Periodontal probe 23/UNC 15	Hu Friedy, Chicago, IL, USA
Cerec AC Omnicam	Sirona Dental Systems GmbH
Cerec 4 CAD/CAM system	Sirona Dental Systems GmbH
Vernier caliper	Hu-Friedy CLP1, Frankfurt am Main, Germany
Ceramic fennance : Programat P700	Ivoclar Vivadent, Schann, Liechtenstein
Universal Testing Machine (Instron model 5566)	Instron, Canton, MA
DemiPlus (LED light Curing Unit )	Kerr, Orange, CA

#### Tooth preparation and root canal filling

The study used forty human two-rooted maxillary first premolars with straight canals extracted for orthodontic reasons and stored at 37°C in a solution of 0.1 % Thymol. The time from extraction to the mechanical testing of teeth was less than 6 months. Inclusion criteria were: sound teeth with a bifurcated canal at the middle third of the root; no sign of cracks, defects, and caries on visual examination under 2.8x magnifying loupes, with fully developed apices and complete root length. The average lengths of teeth used in

this study were  $22\pm 1$  mm, with bucco-lingual coronal dimensions of  $9\pm 1$  mm and mesial-distal coronal dimensions of  $7\pm 1$  mm, measured by means of a caliper at the labial midpoint of the cemento-enamel junction (CEJ) level. Initial preparation of the teeth involved the removal of any superficial staining, calculus, and adhering soft tissue with an ultrasonic scaler. The specimens were assigned to four groups ( $n=10$ ) (Figure 1) as follows: COM-NP, ETT with cervical cavity restored with resin composite without post; ON-NP, ETT with cervical cavity restored with ceramic onlay without post; COM-P, ETT with cervical cavity restored with resin composite and fiber post; and CR-P, ETT with cervical cavity restored with full-coverage crown and fiber post.

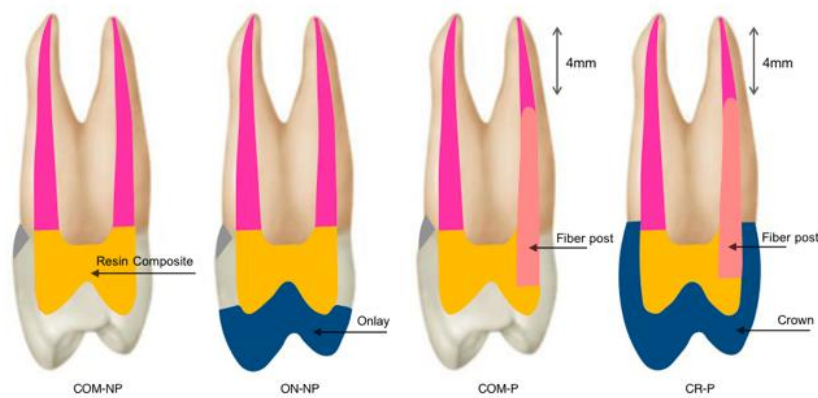


Figure 3 The division of specimens into groups

*COM-NP, ETT with cervical cavity restored with resin composite without post; ON-NP, ETT with cervical cavity restored with ceramic onlay without post; COM-P, ETT with cervical cavity restored with resin composite and fiber post; and CR-P, ETT with cervical cavity restored with full-coverage crown and fiber post.*

Cavity preparation mimicked cervical lesions that were wedge-shaped with divergent walls located in enamel (occlusal margin) and cementum (cervical margin). The cavities were prepared by means of a cylinder diamond bur (835 023 Intensiv, Grancia, Switzerland) at 45° to the buccal surface to create wedge-shaped lesions at the CEJ until a bur depth of 2.0 mm was reached as an outline forming and creating a sharp internal line angle of 90°. For standardization, preparation dimensions were finalized again in all specimens: 2.5 mm deep, 5 mm wide occluso-cervically, 4 mm long on the occlusal wall, and 3 mm long on the cervical wall. A periodontal probe was used to verify the depth (23/UNC 15, Hu Friedy, Chicago, IL, USA). After cavity preparation, teeth were etched with 37.5% phosphoric acid (Kerr, CA, U.S.A.), rinsed, Optibond FL Adhesive (Kerr, Orange, CA, USA) was applied and restored the cavities with resin composite (Premise, Kerr, Orange, CA, USA). Light-curing was performed with a LED light-curing unit for 20 seconds. (DemiPlus, Kerr Corporation, Middleton, WI, USA)

An endodontic access cavity was prepared in the center of the occlusal surface with a high-speed handpiece with a round diamond bur until the root canal orifices were identified. The access opening was oval on the occlusal surface and in the middle third of the tooth. Buccal and palatal cusps were not undermined during access opening preparation. After that use low-speed round steel bur to remove the residual of chamber roof. Using a non-end cutting high-speed diamond bur to finish and flare the cavity. The root canal length was determined by a #10 K-Flex file (Kerr Sybron, Romulus, MI) until

the tip of the file was visible at the apical foramen. Teeth with initial apical files (IAF) 20-25 were included in this study. The working length was established 1 mm short of the apex. The root canals were instrumented by means of K-Flex file and prepared up to X4 using ProTaper Next (Dentsply Maillefer, Ballaigues, Switzerland) to the working length. Each file was used with a brushing motion and a 3-mL of 2.5 % NaOCl was used to irrigate at each change of instrument. Each instrument was used to enlarge eight canals only. Apical patency was performed by a No.10 K-Flex file. Final irrigation was done by 1 mL of 17 % EDTA and 3 mL of distilled water and dried with 3 absorbent paperpoints for 3 seconds each (Dentsply, Maillefer, Ballaigues, Switzerland). After instrumentation, all canals were obturated by the lateral condensation technique with AH Plus (Dentsply, DeTrey, Konstanz, Germany). Digital x-rays confirmed the quality of canal obturation. The excess gutta percha was removed from the pulp chamber with a heated instrument, and the access cavities were wiped with alcohol. Endodontic access was etched with 37.5 % phosphoric acid for 15 seconds followed by adhesive preparation by Optibond FL and restored with resin composite (Premise) according to the manufacturer's instructions. Light-curing with a LED curing light for 20 seconds.

#### Post space preparation

Gutta percha was removed to prepare post spaces in the COM-P and CR-P groups at the palatal canal with a Largo drill No. 1 (Largo; Dentsply Maillefer, Ballaigues,

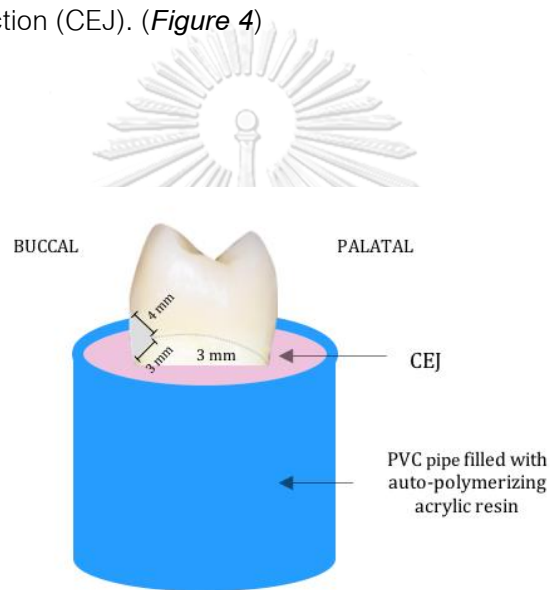


Switzerland) Post spaces were prepared with pre-shaping drills followed by D.T. drill No. 1 (D.T. Light-Post Double Taper; Bisco Inc., Schaumburg, IL, USA) to achieve a post space length with at 4 mm of gutta percha remaining in the apical third. Syringe irrigation was performed with distilled water (3 mL in 3 minutes), then 3 absorbent paperpoints were used for 3 seconds each. The prefabricated fiber post no.1 (DT Light Post Illusion X-RO, Bisco, Schaumburg, USA) was wiped with alcohol according to the manufacturer's recommendation.

#### Fiber post luting procedure

Before placing fiber posts, a digital x-ray was used to check the quality of post space preparation. Cavity and canal were etched with 37.5 % phosphoric acid 15 seconds, rinsed with water spray and dried with paper points. Subsequently, adhesive agent OptiBond Solo Plus was applied by disposable microbrush and immediately rubbed on all surfaces of root canal walls in the canal. The solvent was removed by air blown gently. The posts were prepared with the same adhesive agent and placed with a dual-cured resin cement (Panavia SA Cement Plus, Kuraray, New York, USA), seated in the root canals, and stabilized. Excess cement was removed with a brush. The cement was light-cured for 20 seconds from occlusal direction with the tip directly contact with the post. Each post was cut to an adequate length with a diamond rotary cutting instrument to cover its occlusal end with resin composite up to at least 2 mm. The resin composite

(Premise) was restored followed by light-curing with a LED curing light for 20 seconds. A digital x-ray was taken to check the quality of post placement. Samples were inserted in polyvinyl chloride (PVC) mold with 18 mm internal diameter, 22 mm external diameter and 40 mm height. The molds were filled with auto polymerizing acrylic resin (Palapress; Heraeus Kulzer GmbH, Hanau, Germany). Teeth were placed 3 mm up from cemento enamel junction (CEJ). (*Figure 4*)



### จุฬาลงกรณ์มหาวิทยาลัย

*Figure 4 Teeth were placed 3 mm up from cemento enamel junction (CEJ)*

#### Onlay preparation

Before the preparations, an impression of each tooth was made with a heavy-body silicone impression material (Zhermack Elite HD, Badia Polesine, Rovigo, Italy) as an anatomic guide to obtain an original form while the restoration was applied. All specimens in the ON-NP group were prepared by an initial occlusal reduction.

The anatomical shape by generating 2 mm of clearance for the onlay. Preparation dimensions were done according to manufacturer's instructions as follows: 1.0 mm buccal and lingual reduction with 1.0 mm-deep chamfer. All angles were rounded approximately 10 to 30 degrees and all prepared surface were refined using fine and superfine diamond cutting instruments (Intensiv, Montagnol, Switzerland). Onlays were scanned by intraoral scanner (Cerec AC Omnicam; Sirona Dental Systems, Bensheim, Germany) and generated with the CAD/CAM system (Cerec SW v. 4.5.2; Sirona Dental Systems GmbH, Bensheim, Germany). All specimens were fitted with the anatomy of a first maxillary premolar with cusp tips parallel to the preparation surface. Teeth were scanned, and onlays were designed. On the basis of this scan, a virtual onlay with defined wall thickness was constructed. The onlays were milled with lithium disilicate (e.max CAD blocks, Ivoclar Vivadent, Schaan, Liechtenstein) and crystallized in a ceramic furnace (Programat P700, Ivoclar Vivadent) according to the crystallization/Glaze LT program. All restorations were polished mechanically by means of a commercial polishing kit (Jota All Ceramic Kit 1369, Jota AG, Rüthi SG, Switzerland). The bonded surfaces of the ceramic onlays were etched with 9.5 % HF (Porcelain etchant, Bisco, Schaumburg, IL, USA) for 90 seconds in accordance with the manufacturer's instructions. After onlays were rinsed thoroughly, Silane Primer (Kerr, Orange, CA) were applied to etched surfaces; after 1 minute, the restorations were hot-air-dried for 2 minutes. After the surface treatment and before insertion, the

restoration was protected from light to prevent premature setting. Tooth preparations were treated by 30 second etching with 37.5 % phosphoric acid, then rinsed with water and dried. Restoration and tooth surfaces were coated with adhesive resin (Optibond Solo Plus) and left unpolymerized until the application of the luting material. The dual-cure resin cement system (NX3, Kerr, Orange, CA) was applied to the inner surfaces of restorations and seated on their corresponding prepared teeth with vertical seating pressure and residual cement was removed. Buccal, lingual, mesial, distal, and occlusal surfaces were light-polymerized for 20 seconds for each surface. The restored teeth were stored in distilled water at room temperature for 7 days prior to being tested.

#### Crown preparation

For the CR-P group, ten premolars were conventionally prepared by means of rounded tapered diamond cutting instruments D2, D8, and D16 (Intensiv, Montagnola, Switzerland) to obtain a 6-degree convergence between walls. Preparation dimensions were done according to manufacturer's instructions as follows: 1.0-1.5 mm buccal and lingual reduction, 2-mm reduction was performed on the occlusal surface and 1.0 mm-deep chamfer placed 0.5 mm occlusal to the CEJ except buccal surface margin was placed below the restoration. Crowns were fabricated with lithium disilicate (e.max CAD blocks) and cemented with NX3 resin cement. Surface treatment and tooth surface preparation were followed by method mentioned earlier.

### Compressive Fracture Resistance Testing

Specimens were tested using a universal testing machine (Instron 5566, London, UK).

Each specimen was inserted perpendicular to the horizontal plane in the holding device.

A controlled load was applied by means of a stainless steel tip (2-mm diameter) in a

direction parallel to the longitudinal axis of the tooth. Pressure from the rod tip was

applied at the central fossa contact of both buccal and lingual inclines, to simulate an

occlusal load. The load was applied at a crosshead speed of 0.5 mm/minute. All

samples were loaded until fracture, and the maximum breaking loads were recorded in

Newton (N). (*Figure 5*)



*Figure 5 specimens were tested using a universal machine*

The mode of failure was recorded and classified as restorable or non-restorable. The

failure mode was visually inspected, fracture that presented above the CEJ were

classified as restorable and fracture that presented below CEJ were classified as non-restorable. (Figure 6)

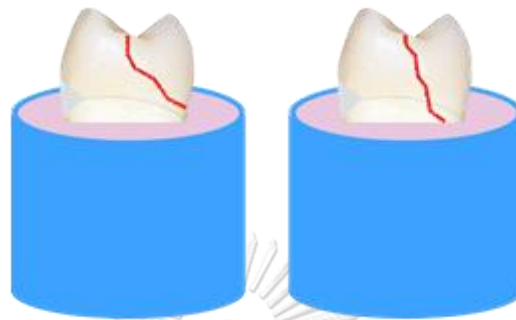


Figure 6 Mode of failure classification

Data of fracture load and mode of failure were collected by the author and analyzed using statistical software (IBM SPSS Statistics version 20.0). One-way ANOVA was used to compare the mean failure load for each group. Significant ANOVA results were also tested with the Scheffe test, with the statistical significance of  $p < 0.05$ . Pearson chi-square test was used in this study for fracture modes with the statistical significance of  $p < 0.05$ .

## CHAPTER IV

### RESULTS

The highest fracture resistance was  $2189.97 \pm 600.38$  N, recorded for the CR-P group, followed by  $1871.45 \pm 313.59$  N for the ON-NP group and  $1510.17 \pm 251.87$  for the COM-P group, with the lowest fracture resistance ( $933.48 \pm 242.53$  N) recorded for the COM-NP group. One-way ANOVA showed significant differences between COM-NP and all test groups ( $p \leq 0.05$ ). However, there were no significant differences between the ON-NP and COM-P groups ( $p=0.218$ ) and also between the ON-NP and CR-P groups ( $p=0.322$ ). The fracture loads (mean $\pm$ SD) are presented in Table 3.

Table 3 Mean value of fracture resistance of the tested groups

Group	Mean $\pm$ SD (N)
COM-NP (Composite WITHOUT fiber post)	$933.48 \pm 242.53^a$
ON-NP (Onlay WITHOUT fiber post)	$1871.45 \pm 313.59^{bc}$
COM-P (Composite WITH fiber post)	$1510.17 \pm 251.87^b$
CR-P (Crown WITH fiber post)	$2189.97 \pm 600.38^c$

*Means with the same superscript letter are not significantly different*

*from each other ( $p > 0.05$ ).*

The failure mode was determined by visual inspection and was classified into two major types relative to the CEJ (Table 2). Specimens that presented fracture above the CEJ were classified as restorable, whereas those that presented fracture below the CEJ were classified as non-restorable. Although most of specimens showed non-restorable mode of failure and there were no significant differences in mode of failure among all groups ( $p>0.05$ ), only fiber post groups showed restorable fracture.

*Table 4 Fracture modes of the tested groups*

Group	Restorable (%)	Non-restorable (%)	Pearson chi-square test
COM-NP (Composite WITHOUT fiber post)	0	100	A
ON-NP (Onlay WITHOUT fiber post)	0	100	A
COM-P (Composite WITH fiber post)	30	70	A
CR-P (Crown WITH fiber post)	20	80	A

Fracture modes followed by different upper case letters are significantly different at  $p<0.05$ .



## CHAPTER V

### DISCUSSION

This study investigated the fracture resistances of ETT with deep cervical lesions restored with fiber posts and various restorations. The mode of failure of ETT with various types of restorations was also examined. Based on our results, we found that cuspal-coverage restorations are composed of crowns and onlays showed higher fracture resistance compared with composite restorations. Also, it was determined that fiber post influences fracture strength when teeth are restored with composite restoration but does not affect the mode of failure significantly.

In this study, the fracture resistance of ETT restored with fiber posts and crowns (CR-P) did not differ significantly from that of those restored with onlay without fiber posts (ON-P). In 2002, Aquilino and Caplan stated that other forms of coronal coverage, such as gold, ceramic, or resin composite onlays, could provide RCT teeth with protection against fracture compared with full-coverage crowns.(6) Moreover, several studies reported that endodontically treated maxillary premolars should be restored with cuspal-coverage restorations to protect and reduce the risk of fracture.(6, 7, 10) When fractures occurred, cuspal coverage was considered to avoid vertical fracture at the cemento-enamel junction, especially when teeth were subjected to lateral forces, because fractures in cuspal coverage mostly occurred within the restorative materials.(109, 110) In 1984, Sorensen and Martinoff demonstrated that endodontically

treated maxillary premolars with crowns showed significantly increased success rates of 93.9 %, whereas post-endodontic restorations without crowns showed success rates of only 56 %.(4) Also, several studies compared teeth with and without crowns and reported significant differences in longevity. Crown placement extended the average time before extraction in ETT.(3, 6, 14) Recently, a retrospective study by Suksaphar and colleagues in 2018 reported that the survival rates of premolars in relation to fracture of full-coverage crowns were higher than those of direct resin composite restorations.(10) According to our results, cuspal-coverage restorations tended to achieve more desirable outcomes than direct resin composite restorations. This finding is consistent with the previous recommendation for post-endodontic restorations in posterior teeth. However, that finding differs from that of Ibrahim and colleagues, in which tooth preparation for crowns in maxillary premolars significantly decreased fracture resistance due to remaining tooth structure destruction; maximal thickness of axial tooth structure at the crown margin is necessary to resist fracture. (9)

Nevertheless, in our study, fracture resistance after restoration with crowns and onlays showed similar results. From this point of view, considering on tooth structure preservation, onlays are superior in terms of reductions in the amount of tooth loss, especially in the cervical area. Preparation for onlays could reduce tooth loss from 67.5–72.3 % with conventional crown preparation to 5.5–27.2 %.(105) The greater the amount of remaining tooth structure, the more fracture resistance the ETT have.(1, 6, 7, 16, 106)

In addition, supragingival location of the margin for onlays avoids periodontal irritation and gingival inflammation and makes the margin easily detected.(107, 108)

The drawback of this study was the lack of data from group restored with fiber post and onlays which would be beneficial to draw a better conclusion. However, several studies have already investigated fracture resistance and failure mode between lithium disilicate onlay restorations with and without fiber post. The results showed no significant differences were found in the groups with fiber posts in terms of fracture resistance. The conclusion from both studies were made saying that ceramic onlays increased the fracture strength of endodontically treated teeth, whereas insertion of fiber posts did not increase the fracture resistance significantly which was consistent with our results. (126, 127)

From the results of this study, the group restored with composite without fiber posts (COM-NP) showed the lowest fracture resistance. In terms of physical and mechanical properties, Soares and colleagues reported that direct composite resin restorations are inferior to ceramic restorations due to the side effects of composite polymerization shrinkage and also the process of fabrication in the laboratory of ceramics could enhance fracture resistance.(17, 128) In contrast to many studies that supported resin composite as a post-endodontic restoration for endodontically treated premolars with limited loss of tooth structure or where marginal ridges are preserved.(8, 96, 129) There are evidence that resin composites perform better in stress distribution

under occlusal force compare to ceramic restoration.(97, 130) Also, advantages of this conservative protocol as a final restoration can reduce treatment times and costs for patients.(10)

Compared with the composite-only group, fiber post placement significantly increased the fracture resistance of direct restorations.(7, 8, 12, 25, 94) Fiber posts improved stress distribution along the adhesive interface because their elastic modulus was close to dentin, (27, 127) contradictory from previously published results which showed no differences in fracture resistance after fiber post insertion.(16, 97, 130) Moreover, post preparation by the removal of dentin from the canal decreases tooth strength and leads to fracture.(97) It has been recommended that posts be inserted only when insufficient tooth structure is present, with the goal of facilitating the retention of restorative materials.(4)

No difference was found in modes of failure among the four groups in this study, we failed to reject the second null hypothesis. Several classifications for mode of failure have been proposed either mechanical cause which is adhesive/cohesive or clinical implications which is restorable/unrestorable. In this study we observed based on the extent of fracture compared to CEJ level. Almost all specimens fractured in an unfavorable mode. Likewise, studies by Fokkinga and colleagues in 2005(124) and Forberger and Gohring in 2008(131) indicated that failure modes in post-restored groups were 90 % unrestorable and involved deep root fracture. However, the results

that some restorable fracture were found only in both fiber post groups was interesting, which might imply that fiber post could somehow enhance and affect the mode of failure. Further carefully designed studies are needed to confirm this finding.

In the present study, the means of fracture resistance in all groups were higher than 100–400 N, which is the range of normal forces in normal occlusion for maxillary premolars. So the minimum threshold in the premolar area which might be capable of withstanding bite force is 400 N.(9, 132) The mean fracture load was at least more than 2 times greater than this threshold, suggesting that all restorations in this study could withstand forces during function.(133) However, this study was a static laboratory test, measuring fracture resistance that could not simulate dynamic oral conditions in many respects, such as magnitude, direction, and rate, but Sorrentino and colleagues proved that static and fatigue loading conditions showed comparably high stress concentration areas and similar failure patterns.(12, 133) Different forces have been applied to investigate mechanical resistance including compression, shear and tension. However, static analyses of resistance to fracture have usually been performed with compressive tests until fractures occurred(14, 124, 125) When maxillary premolars are tested with an optimal size of stainless steel tip are considered to reproduce the mean width of antagonist teeth present in the simulated clinical situation.(12) Most static mechanical fracture tests reported in the literature are characterized by a loading of the premolars at 130°-150° to the longitudinal axis which simulates non-axial forces.(7, 124, 131) On the

contrary, this study was decided to load the specimens in a direction parallel to the longitudinal axis of the tooth simulating a physiological occlusion in order to distribute the stresses more evenly between the residual dental tissues and the restorative material.(12) Load application area could vary from the center of the tooth to supporting cusps. Some studies load was applied either at the palatal cusp(12) or the buccal cusp(16) to represented parafunctional oral habits, this study investigated loads placed at the center of the tooth to simulate normal occlusion.(12, 17, 21, 94) Hannig et al. pointed out the importance of applying loads in unaltered areas of teeth in order to achieve reliable data and avoid the influence from tooth/restoration interface.(125)

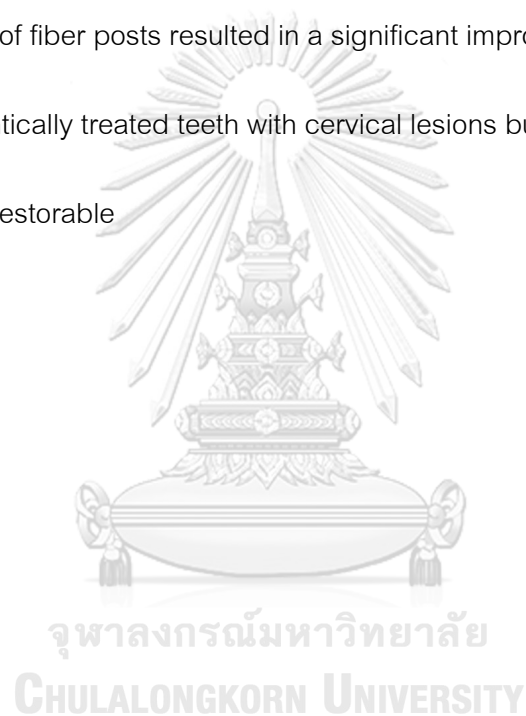Limitations of this study were our inability to recreate, in the laboratory, cervical lesions occurring in natural teeth, and the variations in depth in the natural process. Additional factors which might have affected the results include tooth anatomy, the lack of a simulated periodontal ligament, and the simulation of biting force from only one direction instead of the multiple directions of actual biting force. Further studies are also needed to include the use of a thermal cycling machine and the simulation of the periodontal ligament.

## CHAPTER VI

### CONCLUSION

Within the limitations of this study, the following conclusions can be drawn:

1. Cuspal-coverage restorations significantly enhanced the fracture resistance of endodontically treated maxillary premolars with cervical cavities.
2. Placement of fiber posts resulted in a significant improve the fracture resistance of endodontically treated teeth with cervical lesions but did not significant make the failure restorable



## APPENDIX

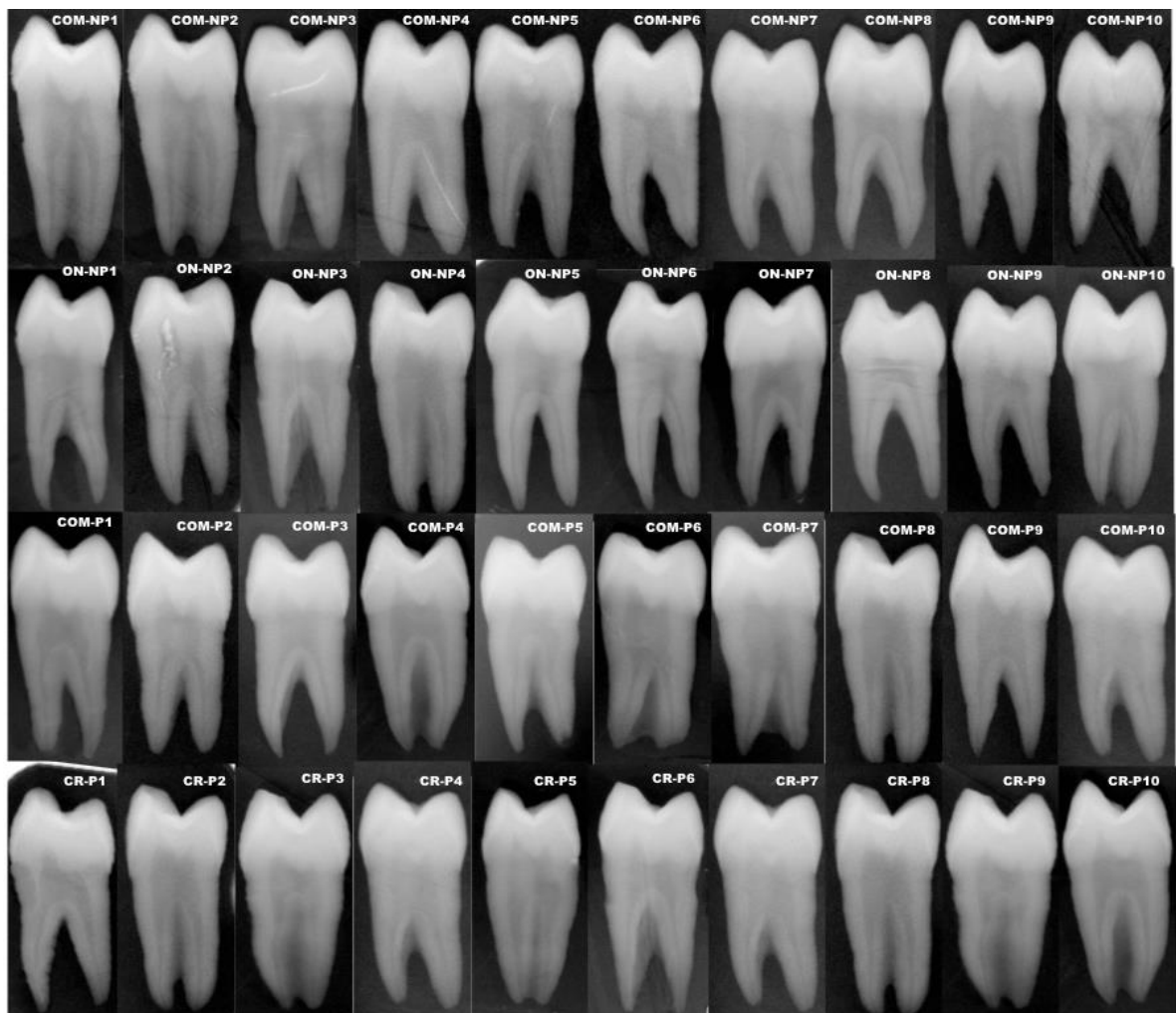


Figure 7 Initial films in tooth selection



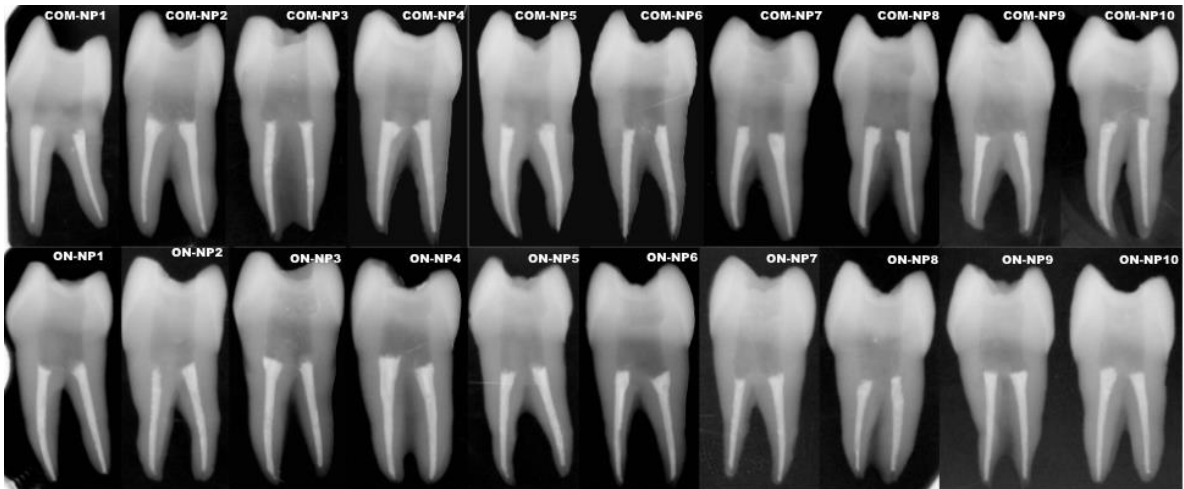


Figure 8 Specimens after canal obturation for COM-NP and ON-NP group

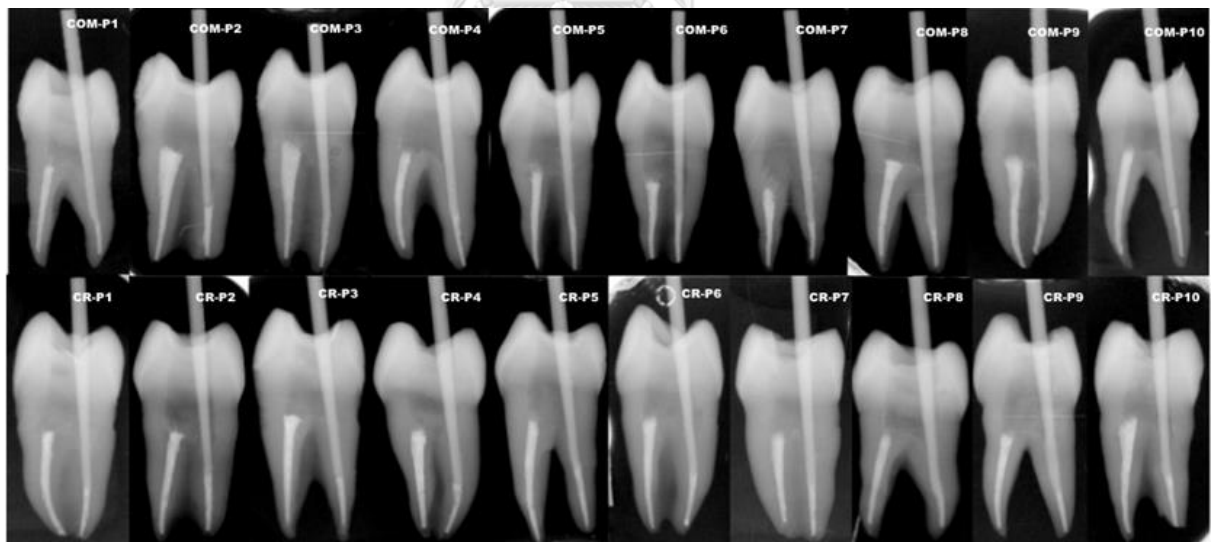
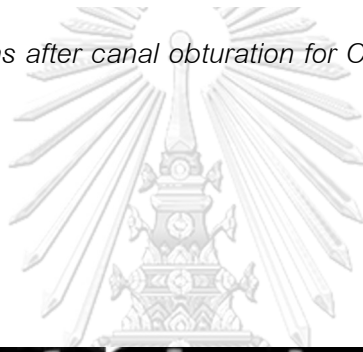
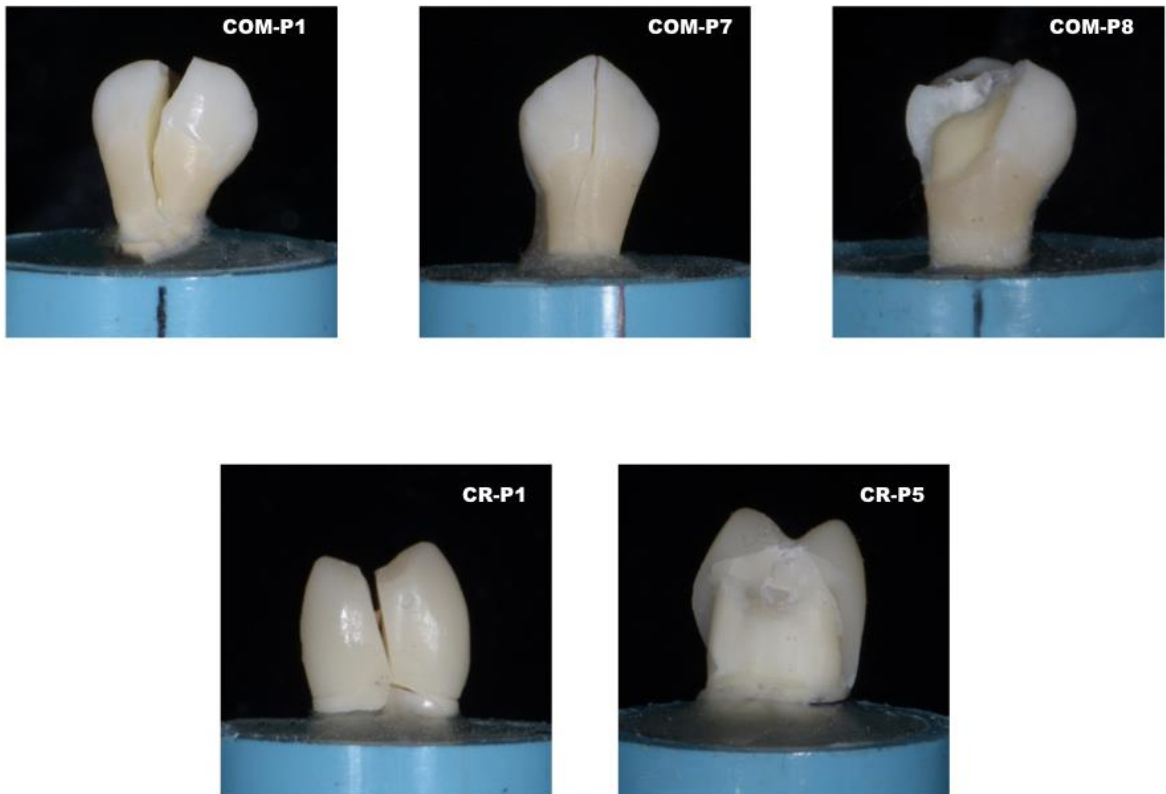
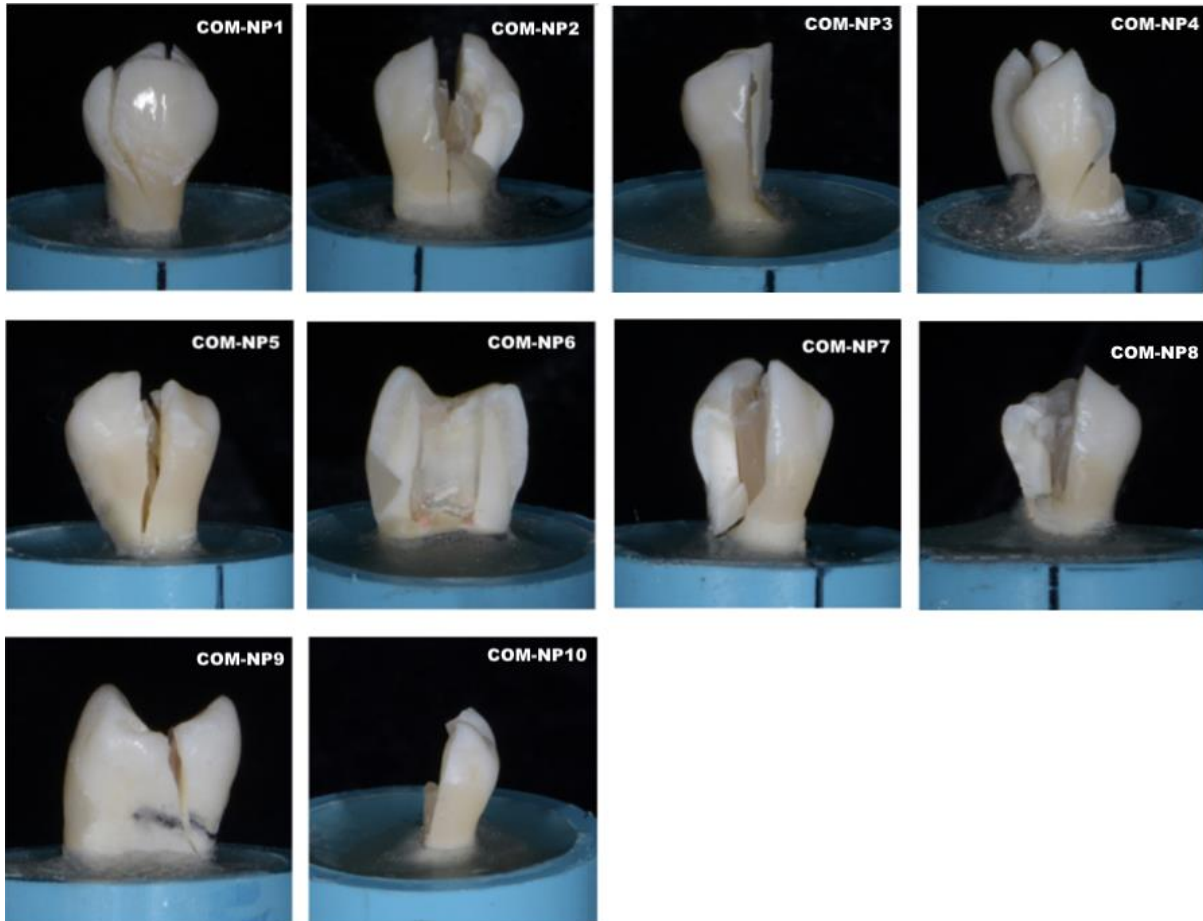


Figure 9 Specimens after try fiber post for COM-P and CR-P



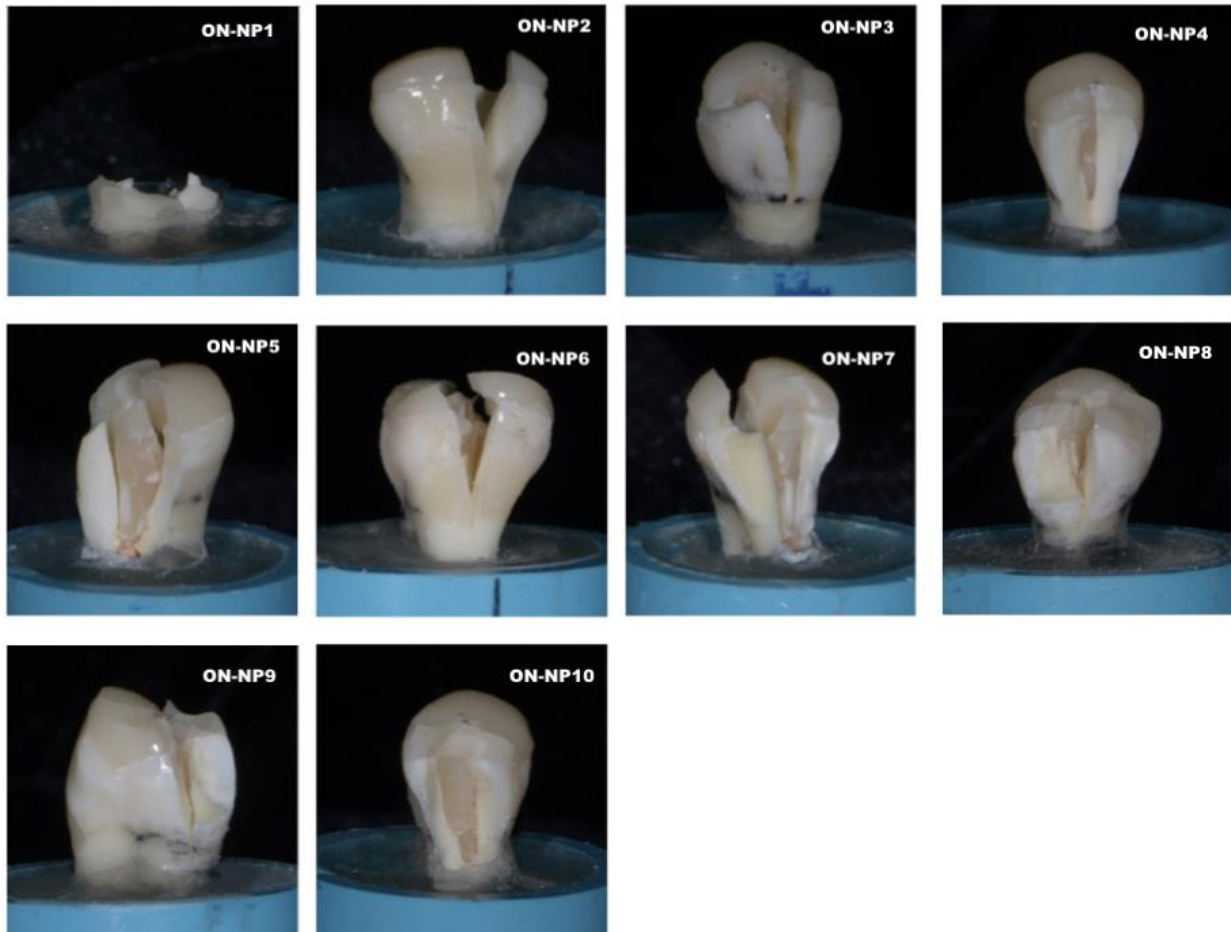
CHULALONGKORN UNIVERSITY

*Figure 10 Restorable specimens*



CHULALONGKORN UNIVERSITY

Figure 11 Unrestorable specimens in COM-NP



จุฬาลงกรณ์มหาวิทยาลัย  
CHULALONGKORN UNIVERSITY

Figure 12 Unreparable specimens in ON-NP

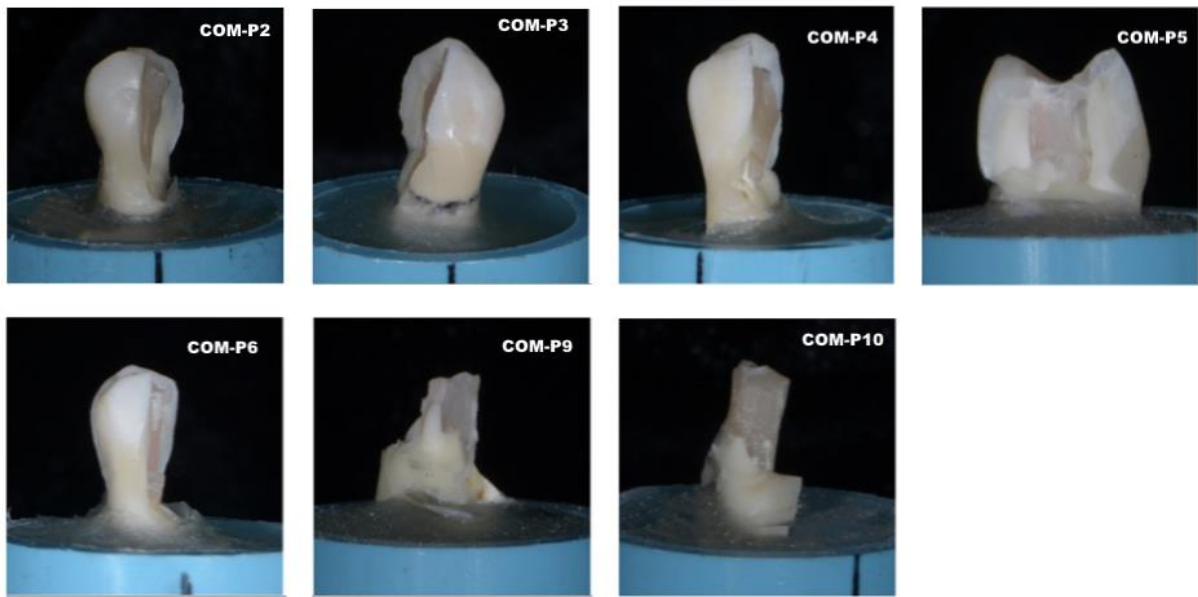


Figure 13 Unrestorable specimens in COM-P

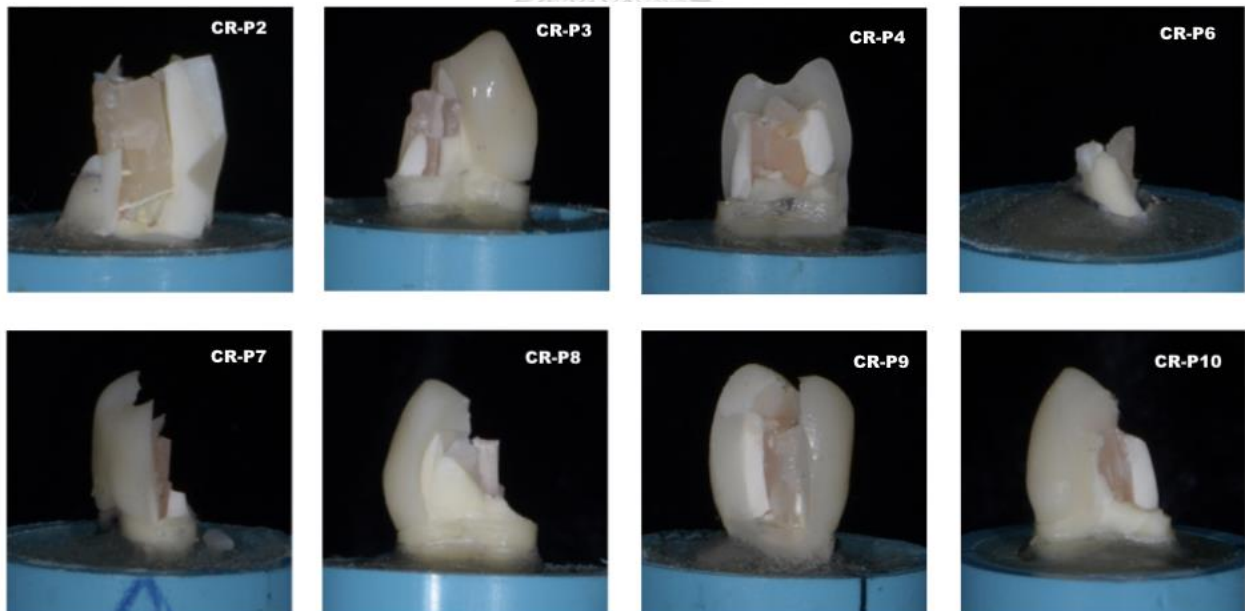


Figure 14 Unrestorable specimens in CR-P

## REFERENCES

1. Reeh ES, Messer HH, Douglas WH. Reduction in tooth stiffness as a result of endodontic and restorative procedures. *J Endod.* 1989;15(11):512-6.
2. Alharbi FA, Nathanson D, Morgano SM, Baba NZ. Fracture resistance and failure mode of fatigued endodontically treated teeth restored with fiber-reinforced resin posts and metallic posts in vitro. *Dent Traumatol.* 2014;30(4):317-25.
3. Vire DE. Failure of endodontically treated teeth: classification and evaluation. *J Endod.* 1991;17(7):338-42.
4. Sorensen JA, Martinoff JT. Intracoronal reinforcement and coronal coverage: a study of endodontically treated teeth. *J Prosthet Dent.* 1984;51(6):780-4.
5. Gogna R, Jagadish S, Shashikala K, Keshava Prasad B. Restoration of badly broken, endodontically treated posterior teeth. *Journal of Conservative Dentistry : JCD.* 2009;12(3):123-8.
6. Aquilino SA, Caplan DJ. Relationship between crown placement and the survival of endodontically treated teeth. *J Prosthet Dent.* 2002;87(3):256-63.
7. Scotti N, Rota R, Scansetti M, Paolino DS, Chiandussi G, Pasqualini D, et al. Influence of adhesive techniques on fracture resistance of endodontically treated premolars with various residual wall thicknesses. *J Prosthet Dent.* 2013;110(5):376-82.
8. Faria ACL, Rodrigues RCS, de Almeida Antunes RP, de Mattos MdGC, Ribeiro RF. Endodontically treated teeth: Characteristics and considerations to restore them. *J Prosthodont Res.* 2011;55(2):69-74.
9. Ibrahim AMBR, Richards LC, Berekally TL. Effect of remaining tooth structure on the fracture resistance of endodontically-treated maxillary premolars: An in vitro study. *J Prosthet Dent.* 2016;115(3):290-5.
10. Suksaphar W, Banomyong D, Jirathanyanatt T, Ngoenwiwatkul Y. Survival Rates from Fracture of Endodontically Treated Premolars Restored with Full-coverage Crowns or Direct Resin Composite Restorations: A Retrospective Study. *J Endod.* 2018;44(2):233-8.
11. Arunpraditkul S, Saengsanon S, Pakviwat W. Fracture resistance of endodontically

- treated teeth: three walls versus four walls of remaining coronal tooth structure. *J Prosthodont.* 2009;18(1):49-53.
12. Sorrentino R, Monticelli F, Goracci C, Zarone F, Tay FR, Garcia-Godoy F, et al. Effect of post-retained composite restorations and amount of coronal residual structure on the fracture resistance of endodontically-treated teeth. *Am J Dent.* 2007;20(4):269-74.
  13. Nissan J, Barnea E, Bar Hen D, Assif D. Effect of remaining coronal structure on the resistance to fracture of crowned endodontically treated maxillary first premolars. *Quintessence Int.* 2008;39(8):e183-7.
  14. Nagasiri R, Chitmongkolsuk S. Long-term survival of endodontically treated molars without crown coverage: A retrospective cohort study. *J Prosthet Dent.* 2005;93:164-70.
  15. Tamse A, Fuss Z, Lustig J, Kaplavi J. An evaluation of endodontically treated vertically fractured teeth. *J Endod.* 1999;25(7):506-8.
  16. Bitter K, Meyer-Lueckel H, Fotiadis N, Blunck U, Neumann K, Kielbassa AM, et al. Influence of endodontic treatment, post insertion, and ceramic restoration on the fracture resistance of maxillary premolars. *Int Endod J.* 2010;43(6):469-77.
  17. Soares PV, Santos-Filho PC, Martins LR, Soares CJ. Influence of restorative technique on the biomechanical behavior of endodontically treated maxillary premolars. Part I: fracture resistance and fracture mode. *J Prosthet Dent.* 2008;99(1):30-7.
  18. Wood I, Jawad Z, Paisley C, Brunton P. Non-carious cervical tooth surface loss: a literature review. *J Dent.* 2008;36(10):759-66.
  19. Soares PV, Souza PG, Souza SC, Gonzaga RCdQ, Faria VLG, Naves MFdL, et al. Effects of non-carious cervical lesions and coronary structure loss association on biomechanical behavior of maxillary premolars. *J Res Dent.* 2013;1(2):14.
  20. Aw TC, Lepe X, Johnson GH, Mancl L. Characteristics of noncarious cervical lesions: a clinical investigation. *J Am Dent Assoc.* 2002;133(6):725-33.
  21. Soares PV, Santos-Filho PC, Queiroz EC, Araujo TC, Campos RE, Araujo CA, et al. Fracture resistance and stress distribution in endodontically treated maxillary premolars restored with composite resin. *J Prosthodont.* 2008;17(2):114-9.
  22. Steele A, Johnson BR. In vitro fracture strength of endodontically treated

premolars. *J Endod.* 1999;25(1):6-8.

23. Mincik J, Urban D, Timkova S, Urban R. Fracture resistance of endodontically treated maxillary premolars restored by various direct filling materials: an in vitro study. *Int J Biomater.* 2016:1-5.
24. Xie KX, Wang XY, Gao XJ, Yuan CY, Li JX, Chu CH. Fracture resistance of root filled premolar teeth restored with direct composite resin with or without cusp coverage. *Int Endod J.* 2012;45(6):524-9.
25. Torres-Sanchez C, Montoya-Salazar V, Cordoba P, Velez C, Guzman-Duran A, Gutierrez-Perez JL, et al. Fracture resistance of endodontically treated teeth restored with glass fiber reinforced posts and cast gold post and cores cemented with three cements. *J Prosthet Dent.* 2013;110(2):127-33.
26. Cagidiaco MC, Radovic I, Simonetti M, Tay F, Ferrari M. Clinical performance of fiber post restorations in endodontically treated teeth: 2-year results. *Int J Prosthodont.* 2007;20(3):293-8.
27. Ferrari M, Vichi A, Mannocci F, Mason PN. Retrospective study of the clinical performance of fiber posts. *Am J Dent.* 2000;13(Spec No):9b-13b.
28. Schwartz RS, Robbins JW. Post placement and restoration of endodontically treated teeth: a literature review. *J Endod.* 2004;30(5):289-301.
29. Mair LH. Wear in dentistry--current terminology. *J Dent.* 1992;20(3):140-4.
30. Grippo JO. Abrasions: a new classification of hard tissue lesions of teeth. *J Esthet Dent.* 1991;3(1):14-9.
31. Levitch LC, Bader JD, Shugars DA, Heymann HO. Non-carious cervical lesions. *J Dent.* 1994;22(4):195-207.
32. Tomasik M, Lipski M. Frequency and etiology of noncarious cervical lesions with pulp exposure. *Ann Acad Med Stetin.* 2009;55(1):70-8.
33. Litonjua LA, Andreana S, Bush PJ, Tobias TS, Cohen RE. Noncarious cervical lesions and abfractions: A re-evaluation. *The Journal of the American Dental Association.* 2003;134(7):845-50.
34. Lee WC, Eakle WS. Possible role of tensile stress in the etiology of cervical erosive



lesions of teeth. *J Prosthet Dent.* 1984;52(3):374-80.

35. Lee WC, Eakle WS. Stress-induced cervical lesions: review of advances in the past 10 years. *J Prosthet Dent.* 1996;75(5):487-94.
36. Ichim I, Schmidlin PR, Kieser JA, Swain MV. Mechanical evaluation of cervical glass-ionomer restorations: 3D finite element study. *J Dent.* 2007;35(1):28-35.
37. Sarode GS, Sarode SC. Abfraction: A review. *J Oral Maxillofac Pathol.* 2013;17(2):222-7.
38. Ommerborn MA, Schneider C, Giraki M, Schafer R, Singh P, Franz M, et al. In vivo evaluation of noncarious cervical lesions in sleep bruxism subjects. *J Prosthet Dent.* 2007;98(2):150-8.
39. Weine FS, Healey HJ, Gerstein H, Evanson L. Canal configuration in the mesiobuccal root of the maxillary first molar and its endodontic significance. *Oral Surg Oral Med Oral Pathol.* 1969;28(3):419-25.
40. Vertucci FJ. Root canal anatomy of the human permanent teeth. *Oral Surg Oral Med Oral Pathol.* 1984;58(5):589-99.
41. Gupta S, Sinha D, Gowhar O, Tyagi S, Singh N, Gupta S. Root and canal morphology of maxillary first premolar teeth in north Indian population using clearing technique: An in vitro study. *Journal of Conservative Dentistry.* 2015;18(3):232-6.
42. Senan EM, Alhadainy HA, Genaid TM, Madfa AA. Root form and canal morphology of maxillary first premolars of a Yemeni population. *BMC Oral Health.* 2018;18(1):94.
43. Dinakar C, Shetty UA, Salian VV, Shetty P. Root Canal Morphology of Maxillary First Premolars Using the Clearing Technique in a South Indian Population: An In vitro Study. *International journal of applied & basic medical research.* 2018;8(3):143-7.
44. Atieh MA. Root and canal morphology of maxillary first premolars in a Saudi population. *J Contemp Dent Pract.* 2008;9(1):46-53.
45. Ok E, Altunsoy M, Nur BG, Aglarci OS, Colak M, Gungor E. A cone-beam computed tomography study of root canal morphology of maxillary and mandibular premolars in a Turkish population. *Acta Odontol Scand.* 2014;72(8):701-6.
46. Gulabivala K, Aung TH, Alavi A, Ng YL. Root and canal morphology of Burmese

mandibular molars. *Int Endod J.* 2001;34(5):359-70.

47. Sert S, Bayirli GS. Evaluation of the root canal configurations of the mandibular and maxillary permanent teeth by gender in the Turkish population. *J Endod.* 2004;30(6):391-8.
48. Peiris HR, Pitakotuwage TN, Takahashi M, Sasaki K, Kanazawa E. Root canal morphology of mandibular permanent molars at different ages. *Int Endod J.* 2008;41(10):828-35.
49. Al-Qudah AA, Awawdeh LA. Root and canal morphology of mandibular first and second molar teeth in a Jordanian population. *Int Endod J.* 2009;42(9):775-84.
50. Rashmi Bansal SH, Madhu Sudan Astekar. Classification of Root Canal Configurations: A Review and a New Proposal of Nomenclature System for Root Canal Configuration. *Journal of Clinical and Diagnostic Research.* 2018;12(5):1-5.
51. Pineda F, Kuttler Y. Mesiodistal and buccolingual roentgenographic investigation of 7,275 root canals. *Oral Surg Oral Med Oral Pathol.* 1972;33(1):101-10.
52. Patel S, Dawood A, Whaites E, Pitt Ford T. New dimensions in endodontic imaging: part 1. Conventional and alternative radiographic systems. *Int Endod J.* 2009;42(6):447-62.
53. Scarfe WC, Fana CR, Jr., Farman AG. Radiographic detection of accessory/lateral canals: use of RadioVisioGraphy and Hypaque. *J Endod.* 1995;21(4):185-90.
54. Pecora JD, Saquy PC, Sousa Neto MD, Woelfel JB. Root form and canal anatomy of maxillary first premolars. *Braz Dent J.* 1992;2(2):87-94.
55. Vertucci FJ, Gegauff A. Root canal morphology of the maxillary first premolar. *J Am Dent Assoc.* 1979;99(2):194-8.
56. Helfer AR, Melnick S, Schilder H. Determination of the moisture content of vital and pulpless teeth. *Oral Surg Oral Med Oral Pathol.* 1972;34(4):661-70.
57. Huang TJ, Schilder H, Nathanson D. Effects of moisture content and endodontic treatment on some mechanical properties of human dentin. *J Endod.* 1992;18(5):209-15.
58. Sim TP, Knowles JC, Ng YL, Shelton J, Gulabivala K. Effect of sodium hypochlorite on mechanical properties of dentine and tooth surface strain. *Int Endod J.* 2001;34(2):120-32.
59. Dietschi D, Duc O, Krejci I, Sadan A. Biomechanical considerations for the

restoration of endodontically treated teeth: a systematic review of the literature--Part 1.

Composition and micro- and macrostructure alterations. *Quintessence Int.* 2007;38(9):733-43.

60. Hansen EK, Asmussen E, Christiansen NC. In vivo fractures of endodontically treated posterior teeth restored with amalgam. *Endod Dent Traumatol.* 1990;6(2):49-55.

61. Fennis WM, Kuijs RH, Kreulen CM, Roeters FJ, Creugers NH, Burgersdijk RC. A survey of cuspal fractures in a population of general dental practices. *Int J Prosthodont.* 2002;15(6):559-63.

62. Caplan DJ, Kolker J, Rivera EM, Walton RE. Relationship between number of proximal contacts and survival of root canal treated teeth. *Int Endod J.* 2002;35(2):193-9.

63. Felton DA, Webb EL, Kanoy BE, Dugoni J. Threaded endodontic dowels: effect of post design on incidence of root fracture. *J Prosthet Dent.* 1991;65(2):179-87.

64. Panitvisai P, Messer HH. Cuspal deflection in molars in relation to endodontic and restorative procedures. *J Endod.* 1995;21(2):57-61.

65. Sakaguchi RL, Peters MC, Nelson SR, Douglas WH, Poort HW. Effects of polymerization contraction in composite restorations. *J Dent.* 1992;20(3):178-82.

66. Kleverlaan CJ, Feilzer AJ. Polymerization shrinkage and contraction stress of dental resin composites. *Dent Mater.* 2005;21(12):1150-7.

67. Kwon Y, Ferracane J, Lee IB. Effect of layering methods, composite type, and flowable liner on the polymerization shrinkage stress of light cured composites. *Dent Mater.* 2012;28(7):801-9.

68. Tantbirojn D, Versluis A, Pintado MR, DeLong R, Douglas WH. Tooth deformation patterns in molars after composite restoration. *Dent Mater.* 2004;20(6):535-42.

69. Larson TD, Douglas WH, Geistfeld RE. Effect of prepared cavities on the strength of teeth. *Oper Dent.* 1981;6(1):2-5.

70. Jafarpour S, El-Badrawy W, Jazi HS, McComb D. Effect of composite insertion technique on cuspal deflection using an in vitro simulation model. *Oper Dent.* 2012;37(3):299-305.

71. Zamboni SC, Nogueira L, Bottino MA, Sobrinho LC, Valandro LF. The effect of

mechanical loading on the cuspal deflection of premolars restored with direct and indirect techniques. *J Contemp Dent Pract.* 2014;15(1):75-81.

72. Cotert HS, Sen BH, Balkan M. In vitro comparison of cuspal fracture resistances of posterior teeth restored with various adhesive restorations. *Int J Prosthodont.* 2001;14(4):374-8.

73. Jensen ME, Redford DA, Williams BT, Gardner F. Posterior etched-porcelain restorations: an in vitro study. *Compendium.* 1987;8(8):615-7, 20-2.

74. Cerutti A, Flocchini P, Madini L, Mangani F, Putignano A, Docchio F. Effects of bonded composites vs. amalgam on resistance to cuspal deflection for endodontically-treated premolar teeth. *Am J Dent.* 2004;17(4):295-300.

75. Thompson JY, Bayne SC, Heymann HO. Mechanical properties of a new mica-based machinable glass ceramic for CAD/CAM restorations. *J Prosthet Dent.* 1996;76(6):619-23.

76. Gonzalez-Lopez S, De Haro-Gasquet F, Vilchez-Diaz MA, Ceballos L, Bravo M. Effect of restorative procedures and occlusal loading on cuspal deflection. *Oper Dent.* 2006;31(1):33-8.

77. Reeh ES, Douglas WH, Messer HH. Stiffness of endodontically-treated teeth related to restoration technique. *J Dent Res.* 1989;68(11):1540-4.

78. Taha NA, Palamara JEA, Messer HH. Cuspal deflection, strain and microleakage of endodontically treated premolar teeth restored with direct resin composites. *J Dent.* 2009;37(9):724-30.

79. Pantvisai P, Messer HH. Cuspal deflection in molars in relation to endodontic and restorative procedures. *J Endod.* 1995;21(2):57-61.

80. Eskandarizadeh A, Torabi Parizi M, Parirokh M, Taheri A. Cusp deflection, infraction and fracture in endodontically treated teeth filled with three temporary filling materials (in vitro). *Journal of Dental Materials and Techniques.* 2015;4(4):173-5.

81. Salehrabi R, Rotstein I. Endodontic treatment outcomes in a large patient population in the USA: an epidemiological study. *J Endod.* 2004;30(12):846-50.

82. Trope M, Maltz DO, Tronstad L. Resistance to fracture of restored endodontically

treated teeth. *Dent Traumatol.* 1985;1(3):108-11.

83. Song M, Kim HC, Lee W, Kim E. Analysis of the cause of failure in nonsurgical endodontic treatment by microscopic inspection during endodontic microsurgery. *J Endod.* 2011;37(11):1516-9.

84. Tabassum S, Khan FR. Failure of endodontic treatment: The usual suspects. *European Journal of Dentistry.* 2016;10(1):144-7.

85. Daokar S, Kalekar A. Endodontic Failures-A Review. *IOSR Journal of Dental and Medical Sciences.* 2013;4:5-10.

86. Olcay K, Ataoglu H, Belli S. Evaluation of Related Factors in the Failure of Endodontically Treated Teeth: A Cross-sectional Study. *J Endod.* 2018;44(1):38-45.

87. Toure B, Faye B, Kane AW, Lo CM, Niang B, Boucher Y. Analysis of reasons for extraction of endodontically treated teeth: a prospective study. *J Endod.* 2011;37(11):1512-5.

88. Zadik Y, Sandler V, Bechor R, Salehrabi R. Analysis of factors related to extraction of endodontically treated teeth. *Oral Surg Oral Med Oral Pathol Oral Radiol Endod.* 2008;106(5):31-5.

89. Fuss Z, Lustig J, Tamse A. Prevalence of vertical root fractures in extracted endodontically treated teeth. *Int Endod J.* 1999;32(4):283-6.

90. Dummer PM, McGinn JH, Rees DG. The position and topography of the apical canal constriction and apical foramen. *Int Endod J.* 1984;17(4):192-8.

91. Gillen BM, Looney SW, Gu LS, Loushine BA, Weller RN, Loushine RJ, et al. Impact of the quality of coronal restoration versus the quality of root canal fillings on success of root canal treatment: a systematic review and meta-analysis. *J Endod.* 2011;37(7):895-902.

92. McLaren JD, McLaren CI, Yaman P, Bin-Shuwaish MS, Dennison JD, McDonald NJ. The effect of post type and length on the fracture resistance of endodontically treated teeth. *J Prosthet Dent.* 2009;101(3):174-82.

93. Soares CJ, Raposo LH, Soares PV, Santos-Filho PC, Menezes MS, Soares PB, et al. Effect of different cements on the biomechanical behavior of teeth restored with cast dowel-and-cores-in vitro and FEA analysis. *J Prosthodont.* 2010;19(2):130-7.

94. Salameh Z, Sorrentino R, Ounsi HF, Sadig W, Atiyeh F, Ferrari M. The effect of different full-coverage crown systems on fracture resistance and failure pattern of endodontically treated maxillary incisors restored with and without glass fiber posts. *J Endod.* 2008;34(7):842-6.
95. Ray HA, Trope M. Periapical status of endodontically treated teeth in relation to the technical quality of the root filling and the coronal restoration. *Int Endod J.* 1995;28(1):12-8.
96. Cheung W. A review of the management of endodontically treated teeth. Post, core and the final restoration. *J Am Dent Assoc.* 2005;136(5):611-9.
97. Assif D, Gorfil C. Biomechanical considerations in restoring endodontically treated teeth. *J Prosthet Dent.* 1994;71(6):565-7.
98. Peroz I, Blankenstein F, Lange KP, Naumann M. Restoring endodontically treated teeth with posts and cores--a review. *Quintessence Int.* 2005;36(9):737-46.
99. Sorensen JA, Martinoff JT. Endodontically treated teeth as abutments. *J Prosthet Dent.* 1985;53(5):631-6.
100. Ferrari M, Cagidiaco MC, Goracci C, Vichi A, Mason PN, Radovic I, et al. Long-term retrospective study of the clinical performance of fiber posts. *Am J Dent.* 2007;20(5):287-91.
101. Parisi C, Valandro LF, Ciocca L, Gatto MR, Baldissara P. Clinical outcomes and success rates of quartz fiber post restorations: A retrospective study. *J Prosthet Dent.* 2015;114(3):367-72.
102. Shafiei F, Memarpour M, Karimi F. Fracture resistance of cuspal coverage of endodontically treated maxillary premolars with combined composite-amalgam compared to other techniques. *Oper Dent.* 2011;36(4):439-47.
103. Kovarik RE, Breeding LC, Caughman WF. Fatigue life of three core materials under simulated chewing conditions. *J Prosthet Dent.* 1992;68(4):584-90.
104. Sornkul E, Stannard JG. Strength of roots before and after endodontic treatment and restoration. *J Endod.* 1992;18(9):440-3.
105. Edelhoff D, Sorensen JA. Tooth structure removal associated with various preparation designs for posterior teeth. *Int J Periodontics Restorative Dent.*

2002;22(3):241-9.

106. Conrad HJ, Seong WJ, Pesun IJ. Current ceramic materials and systems with clinical recommendations: a systematic review. *J Prosthet Dent.* 2007;98(5):389-404.

107. Ross IF. Fracture susceptibility of endodontically treated teeth. *J Endod.* 1980;6(5):560-5.

108. Ross IF. Problems connected with combined periodontal therapy and fixed restorative care. *Dent Clin North Am.* 1972;16(1):47-57.

109. Goerig AC, Mueninghoff LA. Management of the endodontically treated tooth. Part I: concept for restorative designs. *J Prosthet Dent.* 1983;49(3):340-5.

110. Veerapavati W, Vongphan N, Harnirattisai C, Sakdee J. Fracture resistance of endodontically treated premolars restored with different restorations. *Chin J Dent Res.* 2005;5:75-9.

111. Varlan C, Dimitriu B Fau - Varlan V, Varlan V Fau - Bodnar D, Bodnar D Fau - Suciul, Suciul. Current opinions concerning the restoration of endodontically treated teeth: basic principles. (1844-122X (Print)).

112. Smales RJ, Hawthorne WS. Long-term survival of extensive amalgams and posterior crowns. *Journal Of Dentistry Bristol.* (5):225-8.

113. Cheung GS, Chan TK. Long-term survival of primary root canal treatment carried out in a dental teaching hospital. *Int Endod J.* 2003;36(2):117-28.

114. Beuer F, Schweiger J, Edelhoff D. Digital dentistry: an overview of recent developments for CAD/CAM generated restorations. *Br Dent J.* 2008;204(9):505-11.

115. Fasbinder DJ. Computerized technology for restorative dentistry. *Am J Dent.* 2013;26(3):115-20.

116. Birnbaum NS, Aaronson HB. Dental impressions using 3D digital scanners: virtual becomes reality. *Compend Contin Educ Dent.* 2008;29(8):494, 6, 8-505.

117. Galhano GA, Pellizzer EP, Mazaro JV. Optical impression systems for CAD-CAM restorations. *J Craniofac Surg.* 2012;23(6):e575-9.

118. Ho GW, Matinlinna JP. Insights on Ceramics as Dental Materials. Part II: Chemical Surface Treatments. *Silicon.* 2011;3(3):117.

119. Culp L, McLaren EA. Lithium disilicate: the restorative material of multiple options. *Compend Contin Educ Dent*. 2010;31(9):716-20, 22, 24-5.
120. Tysowsky GW. The science behind lithium disilicate: a metal-free alternative. *Dent Today*. 2009;28(3):112-3.
121. Reich S, Fischer S, Sobotta B, Klapper HU, Gozdowski S. A preliminary study on the short-term efficacy of chairside computer-aided design/computer-assisted manufacturing- generated posterior lithium disilicate crowns. *Int J Prosthodont*. 2010;23(3):214-6.
122. Fasbinder DJ, Dennison JB, Heys D, Neiva G. A clinical evaluation of chairside lithium disilicate CAD/CAM crowns: a two-year report. *J Am Dent Assoc*. 2010;141 Suppl 2:10s-4s.
123. Li RWK, Chow TW, Matinlinna JP. Ceramic dental biomaterials and CAD/CAM technology: State of the art. *J Prosthodont Res*. 2014;58(4):208-16.
124. Fokkinga WA, Le Bell AM, Kreulen CM, Lassila LV, Vallittu PK, Creugers NH. Ex vivo fracture resistance of direct resin composite complete crowns with and without posts on maxillary premolars. *Int Endod J*. 2005;38(4):230-7.
125. Hannig C, Westphal C, Becker K, Attin T. Fracture resistance of endodontically treated maxillary premolars restored with CAD/CAM ceramic inlays. *J Prosthet Dent*. 2005;94(4):342-9.
126. Mobilio N, Fasiol A, Mollica F, Catapano S. In Vitro Fracture Strength of Teeth Restored with Lithium Disilicate Onlays with and without Fiber Post Build-Up. *Dentistry journal*. 2018;6(3).
127. Kececi AD, Heidemann D, Kurnaz S. Fracture resistance and failure mode of endodontically treated teeth restored using ceramic onlays with or without fiber posts-an ex vivo study. *Dent Traumatol*. 2016;32(4):328-35.
128. Magne P, Belser UC. Porcelain versus composite inlays/onlays: effects of mechanical loads on stress distribution, adhesion, and crown flexure. *Int J Periodontics Restorative Dent*. 2003;23(6):543-55.
129. Mannocci F, Bertelli E, Sherriff M, Watson TF, Ford TR. Three-year clinical



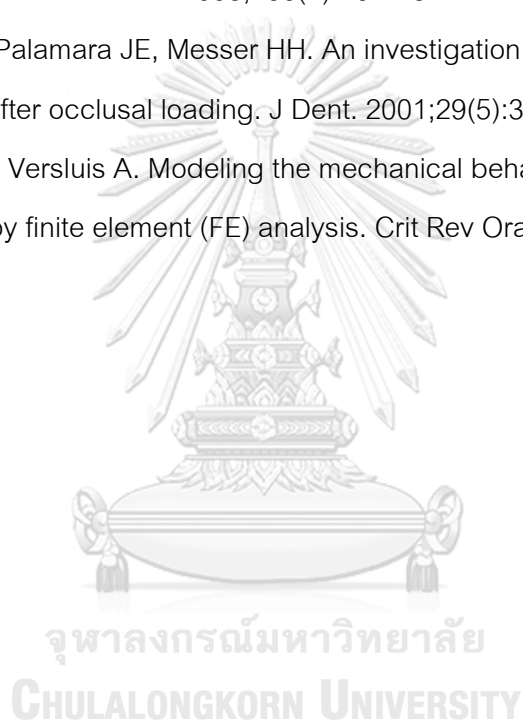comparison of survival of endodontically treated teeth restored with either full cast coverage or with direct composite restoration. *J Prosthet Dent.* 2002;88(3):297-301.

130. Mohammadi N, Kahnamoii MA, Yeganeh PK, Navimipour EJ. Effect of fiber post and cusp coverage on fracture resistance of endodontically treated maxillary premolars directly restored with composite resin. *J Endod.* 2009;35(10):1428-32.

131. Forberger N, Gohring TN. Influence of the type of post and core on in vitro marginal continuity, fracture resistance, and fracture mode of lithia disilicate-based all-ceramic crowns. *J Prosthet Dent.* 2008;100(4):264-73.

132. Jantarat J, Palamara JE, Messer HH. An investigation of cuspal deformation and delayed recovery after occlusal loading. *J Dent.* 2001;29(5):363-70.

133. Koriath TW, Versluis A. Modeling the mechanical behavior of the jaws and their related structures by finite element (FE) analysis. *Crit Rev Oral Biol Med.* 1997;8(1):90-104.



## VITA

NAME Phrohphrim Suebsawadphatthana  
DATE OF BIRTH 31 August 1988  
PLACE OF BIRTH Bangkok,Thailand  
INSTITUTIONS ATTENDED Srinakharinwirot University  
HOME ADDRESS 18 Sukhumvit101/10 Bangna Bangna Bangkok 10260

