

Interstitial pneumonitis: An unusual complication of rituximab

Udomsak Bunworasate*

Worakij Chalermkulrat** Chavit Chantranuwat***

Asda Vibhagool**

Narin Voravud*

Bunworasate U, Chalermkulrat W, Chantranuwat C, Vibhagool A, Voravud N. Interstitial pneumonitis: An unusual complication of rituximab. Chula Med J 2006 Apr; 50(4): 249 - 57

Rituximab, a monoclonal anti-CD20 antibody, is very effective and being used increasingly in the treatment of B-cell lymphomas. Its side-effects are generally limited to infusion-related reactions which are usually mild, brief, and self-limited. Delayed pulmonary reactions related to rituximab, however, have rarely been described. We report a case of 46-year-old man with diffuse large B-cell lymphoma who developed interstitial pneumonitis 16 days after the second cycle of rituximab and CHOP chemotherapy. Transbronchial biopsy showed interstitial inflammation with foci of intra-alveolar organizing fibrinous material. Neither infection nor malignancy was identified. He was successfully treated with high dose methylprednisolone with resolution of the infiltrates within 48 hours. He received subsequent chemotherapy without rituximab and had no recurrence of the interstitial pneumonitis. A review of the literature and possible pathophysiological mechanisms of this unusual complication were discussed. Physicians should be aware of this rare but serious complication.

Keywords : *Rituximab, Interstitial pneumonitis, Complication.*

Reprint request: Bunworasate U. Department of Medicine, Faculty of Medicine,
Chulalongkorn University, Bangkok 10330, Thailand.

Received for publication. November 7, 2005.

* Department of Medicine, Faculty of Medicine, Chulalongkorn University

** Bumrungrad Hospital, Bangkok 10110, Thailand

*** Department of Pathology, Faculty of Medicine, Chulalongkorn University

อุดมศักดิ์ บุญวรเศรษฐ์, วรกิจ เฉลิมสกุลรัตน์, ชวิษฐ์ จันทรานูวัฒน์, อัญญา วิภากุล, นรินทร์ วรวุฒิ. ปอดอักเสบชนิดอินเตอร์สตีเทียล: ภาวะแทรกซ้อนที่พบบ่อยของยาิริทูซิแมบ. จุฬาลงกรณ์เวชสาร 2549 เม.ย; 50(4): 249 – 57

ยาิริทูซิแมบ (Rituximab) เป็นโมโนโคลนัลแอนติบอดีต่อซีดี 20 ที่มีประสิทธิภาพมาก และมีการใช้เพิ่มขึ้นในการรักษาโรคมะเร็งต่อมน้ำเหลืองชนิดบีเซลล์ ผลข้างเคียงของยาที่พบได้โดยทั่วไป ได้แก่อาการข้างเคียงในขณะผู้ป่วยได้รับยา ซึ่งมักมีอาการไม่มาก เป็นอยู่ไม่นาน และหายได้เอง สำหรับภาวะแทรกซ้อนทางปอดที่เกิดภายหลังจากได้รับยาิริทูซิแมบไปแล้วนั้นพบน้อยมาก คณะผู้รายงานได้รายงานผู้ป่วยชายอายุ 46 ปี ที่เป็นมะเร็งต่อมน้ำเหลืองชนิดบีเซลล์และเกิดปอดอักเสบชนิดอินเตอร์สตีเทียลที่ 16 วันภายหลังจากได้รับยาิริทูซิแมบร่วมกับยาเคมีบำบัดชนิด CHOP ในรอบที่ 2 การตัดชิ้นเนื้อปอดไปตรวจพบว่าการอักเสบชนิดอินเตอร์สตีเทียลร่วมกับมีไฟบรินอยู่ภายในถุงลมในหลายตำแหน่ง แต่ไม่พบมีการติดเชื้อหรือมะเร็ง ผู้ป่วยได้รับการรักษาด้วยยาเมธิลเพริดนิโซโลนในขนาดสูงและทำให้ปอดอักเสบหายภายใน 48 ชั่วโมง ผู้ป่วยได้รับยาเคมีบำบัดชุดถัดไปโดยที่ไม่มียาิริทูซิแมบ และไม่พบว่าปอดอักเสบกลับเป็นซ้ำอีก คณะผู้รายงานได้ศึกษาบททวนรายงานทางวิชาการและได้กล่าวถึงกลไกการเกิดภาวะแทรกซ้อนที่พบบ่อยนี้ แพทย์ควรที่จะตระหนักถึงภาวะแทรกซ้อนนี้ที่เกิดจากยาิริทูซิแมบได้

คำสำคัญ : ยาิริทูซิแมบ, ปอดอักเสบชนิดอินเตอร์สตีเทียล, ภาวะแทรกซ้อน

Nowadays the use of monoclonal antibodies in cancer treatment is common. Rituximab, a chimeric murine-human monoclonal anti-CD20 antibody, is one of the most commonly used agents; its efficacy is well demonstrated in the treatment of B-cell lymphomas as a single agent or in combination with chemotherapy.⁽¹⁻⁵⁾ The mechanisms of action responsible for its efficacy include antibody-dependent cell-mediated cytotoxicity, complement-dependent cytotoxicity, and direct induction of apoptosis.⁽⁶⁾ Rituximab therapy has often been associated with infusion-related reactions consisting of fever, chills, and rigors which are usually mild, brief and self-limited.⁽⁷⁾ Overt bronchospasm may occur in few patients during the infusion.

We report a non-Hodgkin's lymphoma patient who developed a delayed interstitial pneumonitis related to rituximab after treatment with a combination of rituximab and cyclophosphamide, doxorubicin, vincristine, and prednisolone (R-CHOP) chemotherapy. A review of the literature and possible pathophysiological mechanisms of this unusual complication are discussed.

Case Report

A 46-year-old man presented with generalized lymphadenopathy involving bilateral cervical, axillary, and inguinal lymph nodes. He had no other medical conditions or allergies. A supraclavicular lymph node biopsy revealed diffuse large B-cell non-Hodgkin's lymphoma. Large neoplastic lymphoid cells were diffusely positive for CD20 and negative for CD3 by immunohistochemical staining. His blood tests including lactate dehydrogenase (LDH) were within normal ranges. Viral serologic studies were negative

for anti-HIV antibody and positive for hepatitis B surface antigen. Chest radiograph (CXR) and echocardiogram were normal. Computed tomography (CT) of the chest and whole abdomen revealed a few subcentimeter aortocaval and paraaortic lymph nodes. No abnormality of lung parenchyma was detected. Bone marrow examination showed no lymphoma involvement. He was diagnosed of stage IIIA diffuse large B-cell non-Hodgkin's lymphoma and underwent a treatment with rituximab (375 mg/m^2) and cyclophosphamide, doxorubicin, vincristine, and prednisolone (R-CHOP) chemotherapy every three weeks. He also received lamivudine for hepatitis B carrier and glipizide for steroid-induced diabetes during the chemotherapy.

Twelve days after the second cycle of R-CHOP, the patient was admitted to hospital for neutropenic fever. He denied any pulmonary symptoms. He had a temperature of 38.9°C ; his oxygen saturation and CXR were normal on admission. Physical examination showed disappearance of previous cervical and axillary lymphadenopathy and revealed only a few residual subcentimeter inguinal lymph nodes. The total white cell count was $1.3 \times 10^9/\text{l}$ with 46 % neutrophils, 36 % lymphocytes, 13 % monocytes, 5 % eosinophils; hemoglobin was 12.3 gm/dl and platelet count was $150 \times 10^9/\text{l}$. Cefipime was administered with minimal improvement of the fever, despite recovery of the white cell counts. His sinus X-ray, ultrasound of the abdomen, and all cultures yielded negative results. He was found to have oral candidiasis which was successfully treated with oral fluconazole. He never required any blood transfusion. Sixteen days after the second cycle of R-CHOP, a repeated CXR revealed diffuse bilateral reticulonodular infiltrates (Figure 1). Cefipime was

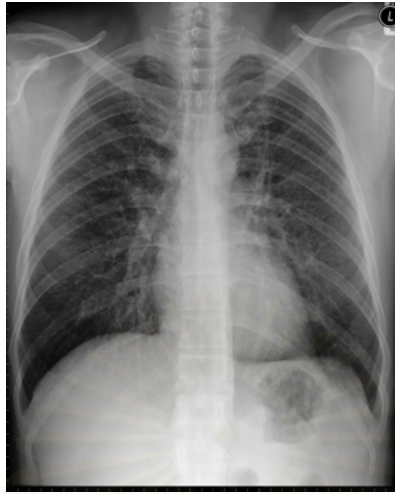


Figure 1. A chest radiograph revealed diffuse bilateral reticulonodular infiltrates.

changed to azithromycin for coverage of atypical pneumonia. All sputum stains and cultures including acid-fast bacilli (AFB), PPD skin test, and blood PCR for cytomegalovirus were negative. He had no pulmonary symptom and his room-air oxygen saturation was 96 %. No signs of congestive heart failure were detected. A follow-up CXR performed two days later showed increased diffuse reticulonodular infiltrates. A faint macular erythematous rash was observed over his back and the fever persisted up to 39.5°C.

Bronchoscopy with bronchoalveolar lavage (BAL) and transbronchial biopsy was performed. The BAL showed nonspecific inflammation and was negative for bacteria including AFB, fungi, virus, and pneumocystis carinii pneumonia by special stains, PCR, and cultures. Transbronchial biopsy (Figure 2A-2B) displayed well-preserved alveolar structures with interstitial mononuclear cell infiltration and focal mild pneumocyte type II proliferation. The most striking pathology was the presence of abundant fibrinous material accumulating in many alveolar spaces with organizing process

by macrophage infiltration and early fibroblastic proliferation. Neutrophils were rarely seen and eosinophil was lacking. Neither hyaline membrane nor bronchiolitis obliterans organizing pneumonia pattern was present. The vasculatures were unremarkable. No foamy exudate, viral inclusion, granuloma or any identifiable organism was detected in hematoxylin and eosin stained sections or special stains (Ziehl-Neelsen, Gram and Gomori methenamine silver stains). Immunohistochemical study (Figure 2C) highlighted scattered T-lymphocytes distributed in the alveolar septa throughout the tissue and within the fibrin material. B-lymphocytes were rarely present. There was no evidence of lymphoma involvement. Azithromycin was discontinued and treatment with steroid was started for possible rituximab reaction causing interstitial pneumonitis. Intravenous methylprednisolone 500 mg on day 1 followed by 250 mg daily for another two doses were given. On the second day of the treatment he was afebrile, and for the first time felt better. The rash on his back began to disappear. Within 48 hours after the treatment, a follow-up CXR demonstrated a

complete resolution of the infiltrates (Figure 3). The chemotherapy was postponed for one week. Upon follow-up, his rash disappeared and a follow-up CXR remained negative. The third cycle of CHOP chemotherapy was administered without rituximab. He tolerated the chemotherapy well without any

toxicity. The follow-up CT scan after three cycles of chemotherapy showed a near complete remission of the lymphoma with no demonstrated lung parenchymal abnormality. He received subsequent chemotherapy without rituximab and had no recurrence of the interstitial pneumonitis.

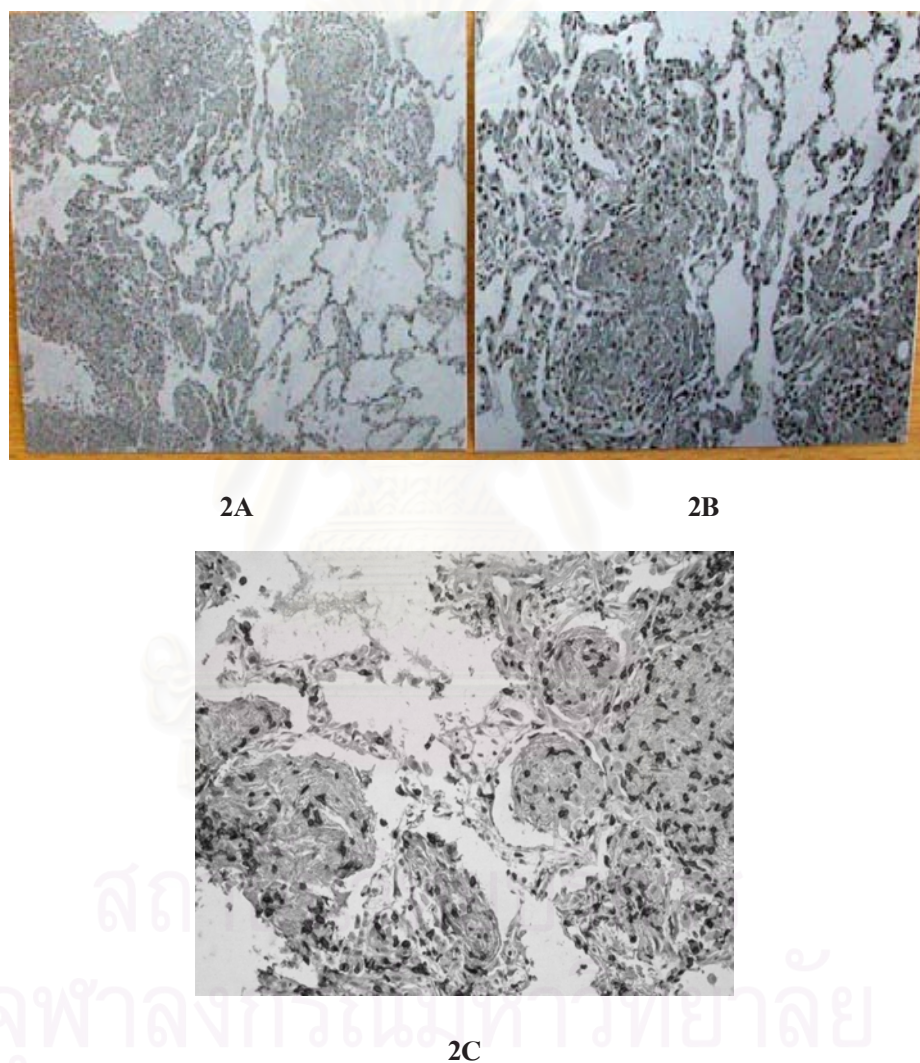


Figure 2. 2A) An alveolar tissue displays several foci of intra-alveolar accumulation of organizing fibrinous material. Alveolar septa contain chronic inflammatory cell infiltrates (hematoxylin and eosin, original magnification X100).
2B) Higher magnification of intra-alveolar organizing fibrinous material characterized by an amorphous eosinophilic material and infiltration of lymphocytes and macrophages (hematoxylin and eosin, original magnification X200)
2C) Immunohistochemical study displaying scattered T-cells in alveolar septae and within the intra-alveolar fibrinous material. (Immunoperoxidase, CD3, original magnification X 200)

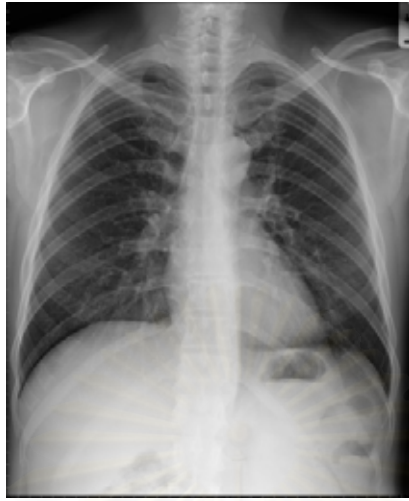

Figure 3. Within 48 hours after the therapy, a follow-up chest radiograph demonstrates a complete resolution of the infiltrates.

Discussion

Pulmonary reactions to rituximab occur most frequently as reversible events during initial infusion in 38 % of patients and consist of cough (13 %), rhinitis (12 %), bronchospasm (8 %), and dyspnea (7 %); 4 % of these events are grade 3 and 4.⁽⁸⁾ In addition, severe infusion reactions, generally occurring during the first two hours of the first infusion can present with hypotension, angioedema and pulmonary involvement in the form of bronchospasm, hypoxia, infiltrates and even acute respiratory distress syndrome.⁽⁶⁾ A higher number of circulating lymphoma cells is associated with an increased incidence of infusion-related side effects.^(7,9,10) In contrast, delayed-onset pulmonary events related to rituximab have rarely been reported. These delayed pulmonary reactions can be in the forms of interstitial pneumonitis, bronchiolitis obliterans with organizing pneumonia (BOOP), pulmonary hemorrhage, or pulmonary fibrosis.^(8, 11-17) The patients usually present with dyspnea, fever, and bilateral pulmonary infiltrates

one to three weeks after any cycle of rituximab treatment. In all reported cases, extensive investigations excluded the diagnosis of infectious pneumonitis. Of eleven patients in the literature, three were ultimately fatal despite steroid treatment.

Our patient in this report developed persistent fever despite recovery of the white cell counts, and developed diffuse bilateral reticulonodular infiltrates 16 days after the second cycle of R-CHOP. Interestingly, he had no significant pulmonary symptom and this could imply an early process of the abnormality. Prompt and extensive investigations including bronchoscopy with BAL and transbronchial biopsy excluded the diagnosis of infectious pneumonia and lymphoma. The transbronchial biopsy revealed subacute interstitial inflammation with foci of intra-alveolar organizing fibrinous material. The current histopathology is compatible with a recently described form of acute to subacute lung injury, namely acute fibrinous and organizing pneumonia (AFOP).⁽¹⁸⁾ Pathologic finding of patchy

distribution with no hyaline membrane, and lack of well form fibroblastic Masson body made pattern of diffuse alveolar damage and BOOP excluded. With clinical features and adequate follow up after the treatment, such condition as infection was unlikely. The current case could be placed in a less severe spectrum of AFOP, since the areas involved were not wide spread, and pneumocyte type II hyperplasia or myxoid fibrotic stroma was only minimal, suggesting of less degree of lung injury and better prognosis. In retrospect, a hypersensitivity reaction to rituximab may be suggested by an association of the skin rash in our patient. In a report of a patient who developed fatal intra-alveolar hemorrhage after rituximab and had skin rash biopsy, it showed pigmented purpuric dermatitis (Schamberg's disease), frequently associated with hypersensitivity reactions. Another report of skin biopsy in a patient who had rituximab reactions demonstrated leukocytoclastic vasculitis.⁽¹⁹⁾

CHOP regimen or its components have been used for decades and usually have not been associated with late pulmonary hypersensitivity reactions. In the absence of other etiologies, together with the temporal relation to the use of rituximab, this has made us believe that rituximab could be suspected as the cause of interstitial pneumonitis. Our patient responded very well to high-dose methylprednisolone with resolution of fever and lung infiltrates within 48 hours. The skin rash totally disappeared within one week. He received subsequent CHOP chemotherapy without rituximab and had no recurrence of the pulmonary reactions.

The mechanisms that lead to rituximab-induced interstitial lung disease are unknown. First-dose infusional reactions are usually considered to be from complement activation, B-lymphocyte cytotoxicity, and cytokine [tumor necrosis factor

alpha (TNF-alpha), interleukin 6 (IL-6) and IL-8] release.^(9, 10, 20) These mechanisms are important in the pathogenesis of initial lung reaction but they cannot entirely explain the late pulmonary reaction from rituximab. Alternatively, dysregulated cellular cytotoxicity has been suggested as the mechanism of delayed pulmonary damage.⁽⁸⁾ Cytotoxic T-lymphocytes (CTL) are believed to play a role in the long-term anti-tumor effects after rituximab treatment. Their activation ('cross-priming') appears to be induced by dendritic cells that mature under the influence of cell-derived peptides resulting from rituximab-induced tumor destruction.⁽²¹⁾ Cross-priming can occur in the lungs since cellular microaggregates were demonstrated to accumulate in lung vasculature after rituximab administration,⁽⁹⁾ and the resultant CTL activation may produce vascular and alveolar damage. As demonstrated by immunohistochemical study in our study, the lymphoid infiltrates were shown to be T-cells and not only presented in interstices of the involved areas but also presented in the intervening lung tissue and within the fibrinous material (Figure 2C). This assumption is also supported by the findings of T-cell infiltration in the lung specimens of the patients who developed delayed rituximab-induced pulmonary damage in other studies.^(8, 15)

In summary, here we report a patient who developed a delayed interstitial pneumonitis related to rituximab after treatment with R-CHOP chemotherapy. Since rituximab is being increasingly used, physicians should be aware of this rare but serious complication. Prompt investigations to rule out other causes, e.g., infection, discontinuation of rituximab, and early steroid treatment will lead to successful outcome and avoid progression to irreversible lung damage.

Acknowledgement

This work was supported by the Development Grants for New Faculty/ Researchers, Chulalongkorn University.

References

1. Coiffier B, Lepage E, Briere J, Herbrecht R, Tilly H, Bouabdallah R, Morel P, Van Den Neste E, Salles G, Gaulard P, et al. CHOP chemotherapy plus rituximab compared with CHOP alone in elderly patients with diffuse large-B-cell lymphoma. *N Engl J Med* 2002 Jan 24;346(4):235-42
2. Feugier P, Van Hoof A, Sebban C, Solal-Celigny P, Bouabdallah R, Ferme C, Christian B, Lepage E, Tilly H, Morschhauser F, et al. Long-term results of the R-CHOP study in the treatment of elderly patients with diffuse large B-cell lymphoma: a study by the Groupe d'Etude des Lymphomes de l'Adulte. *J Clin Oncol* 2005 Jun 20;23(18):4117-26
3. Schmits R, Schmitz N, Pfreundschuh M. German High-Grade Non-Hodgkin's Lymphoma Study Group. The best treatment for diffuse large B-cell lymphoma: a German perspective. *Oncology (Williston Park)* 2005 Apr;19(4 Suppl 1):16-25
4. Marcus R, Imrie K, Belch A, Cunningham D, Flores E, Catalano J, Solal-Celigny P, Offner F, Walewski J, Raposo J, et al. CVP chemotherapy plus rituximab compared with CVP as first-line treatment for advanced follicular lymphoma. *Blood* 2005 Feb 15;105(4):1417-23
5. Hainsworth JD. Prolonging remission with rituximab maintenance therapy. *Semin Oncol* 2004 Feb;31(1 Suppl 2):17-21
6. Maloney DG, Smith B, Rose A. Rituximab: mechanism of action and resistance. *Semin Oncol* 2002 Feb;29(1 Suppl 2):2-9
7. Byrd JC, Waselenko JK, Maneatis TJ, Murphy T, Ward FT, Monahan BP, Sipe MA, Donegan S, White CA. Rituximab therapy in hematologic malignancy patients with circulating blood tumor cells: association with increased infusion-related side effects and rapid blood tumor clearance. *J Clin Oncol* 1999 Mar;17(3):791-5
8. Alexandrescu DT, Dutcher JP, O'Boyle K, Albulak M, Oiseth S, Wiernik PH. Fatal intra-alveolar hemorrhage after rituximab in a patient with non-Hodgkin lymphoma. *Leuk Lymphoma* 2004 Nov;45(11):2321-5
9. Winkler U, Jensen M, Manzke O, Schulz H, Diehl V, Engert A. Cytokine-release syndrome in patients with B-cell chronic lymphocytic leukemia and high lymphocyte counts after treatment with an anti-CD20 monoclonal antibody (rituximab, IDEC-C2B8). *Blood* 1999 Oct 1;94(7):2217-24
10. van der Kolk LE, Grillo-Lopez AJ, Baars JW, Hack CE, van Oers MH. Complement activation plays a key role in the side-effects of rituximab treatment. *Br J Haematol* 2001 Dec;115(4):807-11
11. Kanelli S, Ansell SM, Habermann TM, Inwards DJ, Tuinstra N, Witzig TE. Rituximab toxicity in patients with peripheral blood malignant B-cell lymphocytosis. *Leuk Lymphoma* 2001

- Nov-Dec;42(6):1329-37
12. Burton C, Kaczmarski R, Jan-Mohamed R. Interstitial pneumonitis related to rituximab therapy. *N Engl J Med* 2003 Jun 6;348(26): 2690-1
 13. Byrd JC, Peterson BL, Morrison VA, Park K, Jacobson R, Hoke E, Vardiman JW, Rai K, Schiffer CA, Larson RA. Randomized phase 2 study of fludarabine with concurrent versus sequential treatment with rituximab in symptomatic, untreated patients with B-cell chronic lymphocytic leukemia: results from Cancer and Leukemia Group B 9712 (CALGB 9712). *Blood* 2003 Jan 1;101(1):6-14
 14. Hainsworth JD, Litchy S, Lamb MR, Rodriguez GI, Scroggin C Jr, Greco FA. First-line treatment with brief-duration chemotherapy plus rituximab in elderly patients with intermediate-grade non-Hodgkin's lymphoma: phase II trial. *Clin Lymphoma* 2003 Jun;4(1): 36-42
 15. Leon RJ, Gonsalvo A, Salas R, Hidalgo NC. Rituximab-induced acute pulmonary fibrosis. *Mayo Clin Proc* 2004 Jul;79(7):949, 953
 16. Swords R, Power D, Fay M, O'Donnell R, Murphy PT. Interstitial pneumonitis following rituximab therapy for immune thrombocytopenic purpura (ITP). *Am J Hematol* 2004 Sep;77(1): 103-4
 17. Macartney C, Burke E, Elborn S, Magee N, Noone P, Gleadhill I, Allen D, Kettle P, Drake M. Bronchiolitis obliterans organizing pneumonia in a patient with non-Hodgkin's lymphoma following R-CHOP and pegylated filgrastim. *Leuk Lymphoma* 2005 Oct;46(10): 1523-6
 18. Beasley MB, Franks TJ, Galvin JR, Gochuico B, Travis WD. Acute fibrinous and organizing pneumonia: a histological pattern of lung injury and possible variant of diffuse alveolar damage. *Arch Pathol Lab Med* 2002 Sep; 126(9):1064-70
 19. Dereure O, Navarro R, Rossi JF, Guilhou JJ. Rituximab-induced vasculitis. *Dermatology* 2001;203(1):83-4
 20. Bienvenu J, Chvetzoff R, Salles G, Balter C, Tilly H, Herbrecht R, Morel P, Lederlin P, Solal-Celigny P, Audhuy B, et al. Groupe d'Etude des Lymphomes de l'Adulte. Tumor necrosis factor alpha release is a major biological event associated with rituximab treatment. *Hematol J* 2001;2(6):378-84
 21. Selenko N, Maidic O, Draxier S, Berer A, Jager U, Knapp W, Stockl J. CD20 antibody (C2B8)-induced apoptosis of lymphoma cells promotes phagocytosis by dendritic cells and cross-priming of CD8+ cytotoxic T cells. *Leukemia* 2001 Oct;15(10):1619-26