

## Hepatocellular carcinoma with sarcomatous change mimicking hepatic angiosarcoma : a case report

Mana Tawevisit\*

Sunpetch Benjavonkulchai\* Lalana Sansopha\*

Nareumon Wisedopas\* Pongsepeera Suwangool\*

Tawevisit M, Benjavonkulchai S, Sansopha L, Wisedopas N, Suwangool P. Hepatocellular carcinoma with sarcomatous change mimicking hepatic angiosarcoma : A case report. Chula Med J 2003 Aug; 47(8): 493 - 9

*This is a case report of hepatocellular carcinoma with sarcomatous change. The prevalence of this morphological variant is very rare and the prognosis is poor. The etiology is still uncertain. The tumor occurred in a 74-year-old female who was known to have liver cirrhosis secondary to hepatitis B infection. The autopsy displayed severe bronchopneumonia of both lungs as the major cause of death. The gross appearance of the cirrhotic liver disclosed generalized numerous blood-filled spaces mimicking the angiosarcoma. Although the histopathologic finding revealed sheets of neoplastic cells enclosed with numerous red blood cells and scattered endothelium-like cells, a panel of immunohistochemistry confirmed that these cells originated from hepatocytes rather than endothelial cells.*

**Keywords:** Hepatocellular carcinoma, Sarcomatous change, Angiosarcoma.

Reprint request : Tawevisit M, Department of Pathology, Faculty of Medicine, Chulalongkorn University, Chulalongkorn University, Bangkok 10330, Thailand.

Received for publication. May 15, 2003.

มานะ ทวีวิชญ์, สรรเพชญ เบญจวงศ์กุลชัย, ลลนา แสนโสภา, นฤมล วิเศษโอภาส, พงษ์พีระ สุวรรณกุล. มะเร็งเซลล์ตับร่วมกับการเปลี่ยนแปลงคล้าย sarcoma ที่มีลักษณะเหมือนมะเร็งหลอดเลือด : รายงานผู้ป่วย 1 ราย. จุฬาลงกรณ์เวชสาร 2546 ส.ค; 47(8): 493 - 9

รายงานผู้ป่วยมะเร็งเซลล์ตับที่มีการเปลี่ยนแปลงคล้าย sarcoma ในผู้หญิง อายุ 74 ปี ร่วมกับโรคตับแข็งจากไวรัสตับอักเสบบี มะเร็งตับที่มีลักษณะแบบนี้พบได้ไม่บ่อยนักและมีการพยากรณ์โรคไม่ดี พยาธิกำเนิดนั้นยังไม่เป็นที่ทราบแน่ชัด ผลการตรวจศพพบว่าการติดเชื้ออย่างรุนแรงที่ปอดทั้งสองข้างเป็นสาเหตุการตายหลัก เมื่อพิจารณารอยโรคของตับด้วยตาเปล่าจะพบแองเงโอซันดาเล็กกระจายทั่วไปคล้ายกับมะเร็งหลอดเลือดอย่างมาก จุดพยาธิสภาพแสดงลักษณะของเซลล์มะเร็งล้อมรอบเม็ดเลือดแดงและเซลล์รูปกระสวยคล้ายเยื่อผนังหลอดเลือดเช่นกัน อย่างไรก็ตาม การศึกษาทางอิมมูโนฮิสโตเคมีได้พิสูจน์ต้นกำเนิดของมะเร็งอย่างแน่นอนว่ามาจากเซลล์ตับ

คำสำคัญ : มะเร็งเซลล์ตับ, การเปลี่ยนแปลงคล้าย sarcoma, มะเร็งหลอดเลือด

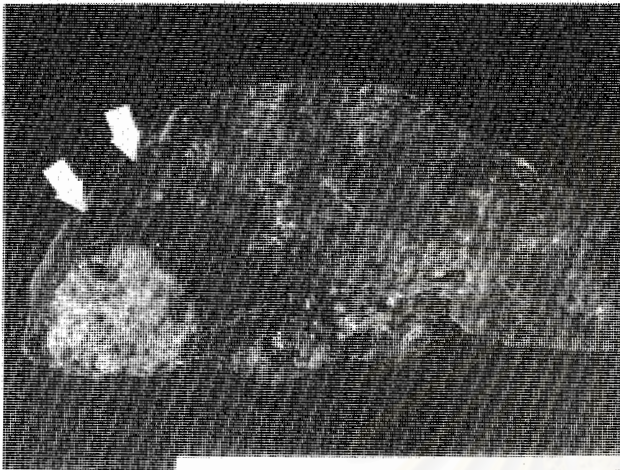
Hepatocellular carcinoma (HCC) with sarcomatous change or sarcomatoid HCC is uncommon and has been sporadically reported.<sup>(1,2)</sup> Its histogenesis still remains a mystery. The vast majority of the neoplasm grossly exhibit infiltrative, mixed infiltrative and expansive, or pedunculate fashion.<sup>(3)</sup> Histologically, the tumors show scattered atypical spindle-shaped cells which look like soft-tissue sarcomas.<sup>(4)</sup> Caution is required when facing with the spindle cell tumor in the liver.

The authors report an autopsy case of sarcomatoid HCC in cirrhotic liver in a patient who passed away from severe bilateral bronchopneumonia at King Chulalongkorn Memorial Hospital. The purpose of this report is to illustrate an unusual feature of HCC with sarcomatous change which shows a large amount of vascular spaces of the entire liver mimicking angiosarcoma. Immunohistochemical approach plays an important role to support the findings.


### Case report

A 74-year-old patient with an underlying disease of hepatic cirrhosis, secondary to hepatitis B infection, was brought to hospital because she experienced abdominal distension, vomiting and drowsiness. The physical examination revealed markedly pale conjunctivae without icteric sclerae and multiple ecchymoses on her extremities. Magnetic resonance imaging (MRI) demonstrated multiple masses with hypointense signals of both hepatic lobes. Laboratory data exhibited hemoglobin of 9.8 g%, leukocyte count of 3,600 /mm<sup>3</sup> with 90% of neutrophils, blood urea nitrogen of 102 mg/dl, and creatinine of 6 mg/dl. Her liver function test gave abnormal results, with aspartate aminotransferase (SGOT) of 131 U/ml, alanine aminotransferase (SGPT)

of 90 U/ml, and alkaline phosphatase of 370 mg/dl. The patient's serum was positive for hepatitis B surface antigen and its antibodies. The clinical impression was hepatocellular carcinoma with subsequent complication of hepatic encephalopathy, spontaneous bacterial peritonitis, and acute renal failure. The clinician gave her antibiotics and other supportive measures. During hospitalization, the patient developed dyspnea and a chest radiograph showed patchy infiltration in both lungs. Despite appropriate management, her condition was worsened and she died 3 days after admission. She was found at autopsy to have splenomegaly, esophageal varices, and extensive patchy bronchopneumonia in both lungs. The liver weighed 1,300 grams and it revealed cirrhotic surface with generalized infiltrative blood-filled spaces, ranging from 0.3 to 0.6 cm in diameter (Fig.1), together with two yellow white fibronecrotic masses, measuring 6X5X4 and 4X2X2 cm of right and left lobes, respectively. Microscopically, sections showed large amounts of malignant nodules, comprising central hemorrhage lined by marked pleomorphic cells with large vesicular nuclei containing distinct nucleoli, infiltrating throughout hepatic parenchyma (Fig.2 and 3) admixed with scattered spindle and giant cells (Fig.4). Mitoses were frequently detected. Investigation of the immunohistochemical localization were performed by the avidin-biotin complex technique. The pleomorphic cells around the hemorrhagic zones expressed cytokeratin, vimentin, hepatocyte antigen, and alpha fetoprotein (AFP) whereas spindle cells only expressed cytokeratin (Fig.5) and vimentin. However, the tumor cells reacted negatively with CD34 and factor VIII. The cause of death was identified as sepsis from severe bilateral bronchopneumonia with acute pulmonary edema.




**Figure 1.** Discrete blood-filled spaces of the liver (arrow) in addition to two grayish white fibronecrotic masses.



**Figure 2.** The neoplasm demonstrates dimorphic appearance consisting of sarcomatouslike (left) and angiosarcoma-like (right) patterns. Normal hepatic parenchyma (\*) is noted. (H&E stain X 100)



**Figure 3.** The neoplastic cells encircle numerous red blood cells (left lower corner) mimicking angiosarcoma. (H&E stain X 400)



**Figure 4.** The pleomorphic spindle cells are arranged in haphazard pattern. (H&E stain X 400)



**Figure 5.** The tumor cells are strongly positive for cytokeratin.

## Discussion

Hepatocellular carcinoma (HCC) is the most common malignant tumor with a prevalence of one million new cases per year.<sup>(5)</sup> Typical microscopic examination can demonstrate tumor cells arranged in cords separated by prominent sinusoids.<sup>(6-8)</sup> In addition to the ordinary histomorphology, the coexistence of sarcomatoid or sarcomatous change is exceeding rare and has been found in a small fraction of the vulnerable population.<sup>(1,2,9)</sup> The etiopathogenesis has been debated whether it consists of double independent malignant epithelial and soft tissue tumors, neoplastic liver cell metaplasia, or development from uncommitted embryonic stem cells.<sup>(3)</sup>

There is no notable the age and gender predilection at the time of diagnosis.<sup>(4)</sup> Regardless to non-specific symptoms and signs, the patients usually present as end-stage with rapidly progressive hepatic dysfunction, malignant ascites, and distant metastasis.<sup>(10,11)</sup> The symptoms which include high graded fever and hypochondralgia have been

published in current studies.<sup>(12)</sup> In most of the cases are sarcomatous change, serum AFP levels can be low or negative.<sup>(13)</sup> The relation to liver cirrhosis is not different from the conventional HCC.<sup>(4)</sup>

Macroscopic feature frequently exhibits infiltration or mixed infiltration with expansion.<sup>(14)</sup> Pedunculated masses, however, are uncommon, but it is significantly higher in HCC with sarcomatous change than in ordinary HCC.<sup>(4)</sup> In this autopsy case, a large number of various sizes of blood-filled spaces grossly resemble aggressive vascular lesions, particularly angiosarcoma, which is an unusual finding and it has not previously been described in the literature.

Histologically, the tumor with sarcomatous change consists mainly of spindle-shaped cells and bizarre multinucleated giant cells, which often lack cohesiveness. Pathologists may misdiagnose these characters as a spindle or pleomorphic sarcoma of the liver. In rare instances, chondrosarcomatous and rhabdomyoblastic transformation can occur.<sup>(6,14,15)</sup> Autophagocytosis or cannibalism, which is occasionally seen in poorly differentiated carcinoma can be identified in some tumor cells in sarcomatous part.<sup>(4,9)</sup> In contrast to replacing feature of conventional HCC, the growth pattern of sarcomatoid HCC often shows a sinusoidal spreading. The tumor eventually contains atrophic liver cell cords with irregular destruction of the reticulin framework when treated by silver impregnation. Transition between trabecular HCC and sarcomatous areas are occasionally observed. The sinusoidal growth pattern reflects macroscopically permeative tumor-non-tumor boundary with high incidence of extrahepatic metastasis and poor prognosis. An additional characteristic finding is the presence of advanced

necrosis in the tumor.<sup>(3,13)</sup>

In our case, angiosarcoma should be first excluded because most malignant vascular lesions, that have central bleeding, is rimmed by pleomorphic cells admixed with scattered neoplastic spindle cells identical to dysplastic endothelium.<sup>(16,17)</sup> However, an evidence of HCC with sarcomatous change is immunohistochemically proved that the tumor cells express cytokeratin and vimentin with typical intracytoplasmic pattern, but do not express endothelial markers consisting of CD34 and factor VIII.<sup>(18,19)</sup> Giving the fact into consideration, the intermingled neoplastic spindle cells are hepatocyte antigen and AFP negative as opposed to pleomorphic cells around hemorrhagic lesions which indicate poorly biological differentiation of the tumor.<sup>(11,12)</sup>

According to development of sarcomatous change in HCC, there is markedly increased over the past several years. The incidence is predominantly elevated in the patients who received or are receiving anticancer therapy, such as transcatheter arterial embolization (TAE) and single bolus injections of anticancer agents into the hepatic artery.<sup>(20)</sup> It is possible that chemotherapy may be an important factor in morphological and phenotypic changes of tumor progression.<sup>(3,4)</sup> However, this patient was not treated with any chemotherapy because of very poor performance status.

## References

1. Tsuji K, Sakurai Y, Kang JH, Katanuma A, Miyoshi M, Osanai M, Yanagawa N, Izumi S, Itoh H, Watanabe S, et al. A case of mixed type hepatoma with sarcomatous change. *Nippon Shokakibyo Gakkai Zasshi* 1999 Sep; 96(9): 1073 - 8
2. Uchida E, Miyata Y, Sakai H, Koga S, Yamashita T, Muramatsu K, Ibayashi H, Adachi Y, Fukushima M. Two cases of hepatocellular carcinoma with sarcomatous change showing an unusual infiltrative metastasis. *Nippon Shokakibyo Gakkai Zasshi* 1987 Dec; 84(12): 2740 - 4
3. Kakizoe S, Kojiro M, Nakashima T. Hepatocellular carcinoma with sarcomatous change. Clinicopathologic and immunohistochemical studies of 14 autopsy cases. *Cancer* 1987 Jan 15; 59(2): 310 - 6
4. Komada N, Yamagata M, Komura K, Hayashi K, Maruyama T, Kataoka H, Koono M, Tsubouchi H. Hepatocellular carcinoma with sarcomatous change arising in primary cirrhosis. *J Gastroenterol* 1997 Feb; 32(1): 95 - 101
5. Dominguez-Malagon H, Gaytan-Graham S. Hepatocellular carcinoma: an update. *Ultrastruct Pathol* 2001 Nov-Dec; 25(6): 497 - 516
6. Ikebe T, Wakasa K, Sasaki M, Hamba H, Kaneko M, Yamamoto T, Mikami S, Shuto T, Hirohashi K, Kinoshita H, et al. Hepatocellular carcinoma with chondrosarcomatous variation: case report with immunohistochemical findings, and review of the literatures. *J Hepatobiliary Pancreat Surg* 1998; 5(2): 217 - 20
7. Wee A, Nilsson B. Highly well differentiated hepatocellular carcinoma and benign hepatocellular lesions. Can they be distinguished on fine needle aspiration biopsy? *Acta Cytol* 2003 Jan-Feb; 47(1): 16 - 26

8. Brage A, Tome S, Figueruela B, Abdulkader I, Martinez J, Varo E. Hepatoma in a 40-year old male with hereditary hemochromatosis in the absence of cirrhosis. Implications of molecular diagnosis. *Rev Esp Enferm Dig* 2002 Aug; 94(8): 493 - 9
9. Han JH, Park YN, Jung WH, Chi HS, Park C. A case with sarcomatoid hepatocellular carcinoma. *Yonsei Med J* 1998 Aug 8,39(4): 390 - 4
10. Morishita Y, Etori F, Sawada K, Kachi H, Yamada T, Kawamori T, Tanaka T. Sarcomatous hepatocellular carcinoma with malignant ascites. A report of two cases. *Acta Cytol* 1998 May-Jun; 42(3): 759 - 64
11. Honda H, Hayashi T, Yoshida K, Takenaka K, Kaneko K, Fukuya T, Tateshi Y, Ro T, Maeda T, Masuda K. Hepatocellular carcinoma with sarcomatous change: characteristic findings of two-phased incremental CT. *Abdom Imaging* 1996 Jan-Feb; 21(1): 37 - 40
12. Eriguchi N, Aoyagi S, Okuda K, Hara M, Fukuda S, Tamae T, Ohdo M, Kanazawa N, Kawabata M, Kodama T et al. Unusual liver carcinomas with sarcomatous features: analysis of four cases. *Surg Today* 2001; 31(6): 530 - 3
13. Matsuoka N, Yamamoto T, Haratake J, Hashimoto H, Unoki H. Sarcomatoid liver carcinoma diagnosed clinically as hemangioma. *J UOEH* 1992 Dec 1; 14(4): 297 - 303
14. Akasofu M, Kawahara E, Kaji K, Nakanishi I. Sarcomatoid hepatocellular carcinoma showing rhabdomyoblastic differentiation in the adult cirrhotic liver. *Virchows Arch* 1999 Jun; 434(6): 511 - 5
15. Fu Y, Kobayashi S, Kushida Y, Sao K, Haba R, Mori S, Miki H, Ohmori M. Sarcomatoid hepatocellular carcinoma with chondroid variant: case report with immunohistochemical findings. *Pathol Int* 2000 Nov; 50(11): 919 - 22
16. Tordjman R, Eugene C, Clouet O, Wesenfelder L, Collet C, Bergue A. Hepatosplenic angio-sarcoma complicated by hemoperitoneum and disseminated intravascular coagulation. Treatment by arterial embolization and chemotherapy. *Gastroenterol Clin Biol* 1995 Jun-Jul; 19(6-7): 625 - 8
17. Basten O, Bandorski D, Langner C. Hemangiosarcoma of the liver with unusual expression of neuron-specific enolase (NSE). *Z Gastroenterol* 2002 Aug; 40(8): 577 - 80
18. Sasaki A, Yokoyama S, Nakayama I, Nakashima K, Kim YI, Kitano S. Sarcomatoid hepatocellular carcinoma with osteoclast-like giant cells: case report and immunohistochemical observation. *Pathol Int* 1997 May, 47(5): 318 - 34
19. Kim DG, Park SY, Kim H, Chun YH, Moon WS, Park SH. A comprehensive karyotypic analysis on a newly established sarcomatoid hepatocellular carcinoma cell line SH-J1 by comparative genomic hybridization and chromosome painting. *Cancer Genet Cytogenet* 2002 Jan 15; 132(2): 120 - 4
20. Kojiro M, Sugihara S, Kakizoe S, Nakashima O, Kiyomatsu K. Hepatocellular carcinoma with sarcomatous change: a special reference to the relationship with anticancer therapy. *Cancer Chemother Pharmacol* 1989; 23 Suppl: S4 - 8