

## Epstein Barr virus infection with unusual pneumothorax: a case report

Piyachat Lekhanont\*

Rujipat Samransamruajkit\* Prakat Charearnrad\*

Sasithorn Likitnukul\*

Nuanchan Prapphal\*

**Lekhanont P, Samransamruajkit R, Charearnrad P, Likitnukul S, Prapphal N. Epstein Barr virus infection with unusual pneumothorax: a case report. Chula Med J 2004 Apr; 48(4): 247 - 52**

*Epstein-Barr virus causes various clinical features. The frequent manifestations include exudative pharyngitis, lymphadenopathy and hepatosplenomegaly. The patient may be asymptomatic and spontaneously recover from infection or has severe symptoms with fatal complication. The incidence of previously reported respiratory complication ranged between 2-11 % including interstitial pneumonia, hilar or mediastinal adenopathy, upper airway obstruction from enlarged lymph nodes of Waldeyer ring. In addition, massive hemoptysis was also described in a patient with EBV infection. Pneumothorax related with EBV infection had never been reported.*

*We report a 4 years and 9 months old boy who was hospitalized because of intractable cough and respiratory distress. Epstein-Barr viral pneumonitis was later diagnosed. Spontaneous pneumothorax which was rarely reported to be associated with EBV infection occurred in our patient. The possible mechanism of pneumothorax following EBV pneumonitis was discussed.*

**Keywords :** *Epstein-Barr virus, Pneumothorax, Pulmonary complication.*

Reprint request : Samransamruajkit R. Department of Pediatrics, Faculty of Medicine,  
Chulalongkorn University, Bangkok 10330, Thailand.

Received for publication. January 10, 2004.

ปิยฉัตร เลขานนท์, รุจิภัตต์ สาราณสารวจกิจ, ประกาศ เจริญราษฎร์, ศศิธร ลิขิตนุกูล, นवलจันทร์ ปราบพาล. การเกิดลมรั่วในช่องปอดจากการติดเชื้อ Epstein-Barr virus. จุฬาลงกรณ์เวชสาร 2547 เม.ย; 48(4): 247 - 52

การติดเชื้อ Epstein-Barr virus (EBV) ก่อให้เกิดอาการทางคลินิกได้หลายรูปแบบที่พบบ่อย ได้แก่ คออักเสบมีหนอง ต่อม้ำน้ำเหลืองโต ตับม้ามโต ผู้ป่วยที่ติดเชื้ออาจไม่มีอาการและหายเอง หรือมีอาการมากและเกิดภาวะแทรกซ้อนจนอาจถึงแก่ชีวิตได้ ภาวะแทรกซ้อนในระบบหายใจพบได้ร้อยละ 2 - 11 โดยที่มีรายงานไว้ ได้แก่ ปอดอักเสบ (interstitial pneumonia) ต่อม้ำน้ำเหลืองที่ขั้วปอด หรือบริเวณเมดิแอสติเนียมโต (hilar or mediastinal adenopathy) ภาวะอุดกั้นในระบบทางเดินหายใจ ส่วนบนจากการมีต่อม้ำน้ำเหลืองบริเวณ waldeyer ring โตขึ้น นอกจากนี้มีรายงานผู้ป่วยที่ติดเชื้อนี้ที่มีอาการไอเป็นเลือดปริมาณมาก แต่ยังไม่มีการเกิดภาวะลมรั่วในช่องปอดในผู้ป่วยที่ติดเชื้อไวรัสชนิดนี้

อาการไอรุนแรงและภาวะหายใจลำบาก ซึ่งต่อมาได้รับการวินิจฉัยว่าติดเชื้อ EBV และมีภาวะลมรั่วในช่องปอด โดยนำเสนออาการทางคลินิก ผลการตรวจทางห้องปฏิบัติการ การตรวจทางรังสี การดำเนินโรค การรักษา และการติดตามผู้ป่วย รวมถึงข้อสันนิษฐานเกี่ยวกับกลไกของการเกิดภาวะลมรั่วในช่องปอดที่ตรวจพบในผู้ป่วย

**คำสำคัญ :** Epstein-Barr virus, ภาวะลมรั่วในช่องปอด, ภาวะแทรกซ้อนในระบบหายใจ

Epstein-Barr virus produces a number of clinical manifestations and multiple system involvements. The spectrum of the diseases is wide, ranging from asymptomatic to fatal infection. Respiratory tract complications have been described in many literatures such as interstitial pneumonia, hilar or mediastinal adenopathy<sup>(1)</sup>, upper airway obstruction<sup>(2,3)</sup> secondary to hypertrophy of tonsils as well as other lymph nodes of Waldeyer's tonsillar ring, and life-threatening hemoptysis,<sup>(4)</sup> but pneumothorax rarely occurred. We here report an unusual pulmonary complication related to EBV infection which has never been reported in accessible literatures.

### Case presentation

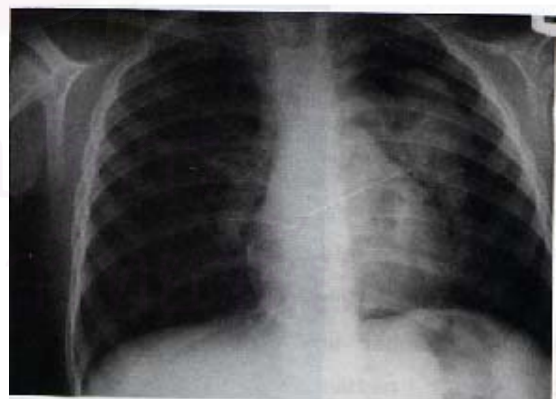
A 4 years and 9 months old Thai boy with previous healthy condition was admitted to Chulalongkorn University Hospital secondary due to high fever, intractable cough and respiratory distress. One day prior to the admission, he developed bilaterally swollen eyelids and a few round tender masses on both sides of his neck, with more frequent cough and severe abdominal pain. He had no history of TB contact and recent traveling. His symptoms were rapidly worsening on the day of admission.

On initial physical examination, he looked acutely ill and tachypneic with BP 110/59 mmHg, pulse rate 154/min, respiratory rate 46/min and BT 37.5°C. His oxygen saturation was 97 % in room air. Marked swollen eyelids were observed bilaterally. Whitish patches on both enlarged tonsils were also noted. He had multiple tender cervical lymphadenopathy, the largest one was the left anterior cervical node size 4 by 4 cm. There was subcostal

retraction, inspiratory and expiratory wheezing of both lung fields and coarse crepitations at left lower lung. Air entry of both lungs was equal. Heart sounds were normal. His liver was 2 cm. below the right costal margin with span of 10 cm. The spleen was 2 cm. below the left costal margin. His neurological exam was unremarkable.

Initial laboratory investigations showed hemoglobin 11.2 gm/dl, white blood cell count  $30.8 \times 10^9/l$  (52 % neutrophils, 1 % band forms, 20 % atypical lymphocytes, 21 % lymphocytes, 6 % monocytes), platelet count  $25 \times 10^9/l$ , BUN 14 mg/dl, Cr 0.5 mg/dl and normal serum electrolytes. The urine analysis was negative. His chest radiograph on admission demonstrated bilateral interstitial infiltrations, medial pneumothorax and atelectasis of left upper lung with mediastinal adenopathy. (Figure 1.)

The child was treated with intravenous hydrocortisone 5 mg/kg/day for three days because of severe upper airway obstruction. Oxygen



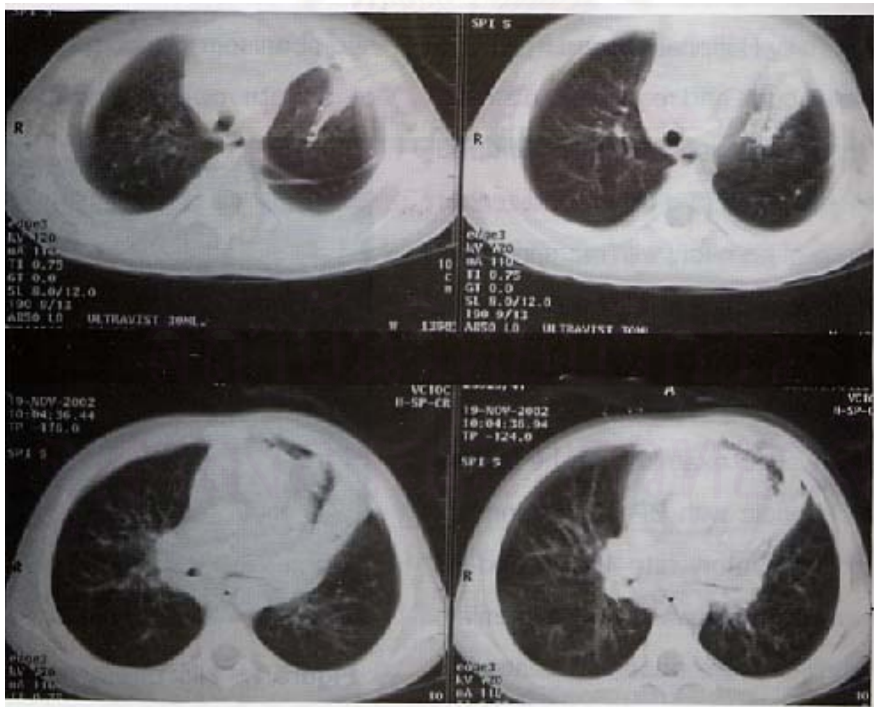
**Figure 1.** His chest radiograph on admission demonstrated bilateral interstitial infiltrations, medial pneumothorax, atelectasis of the left upper lung and mediastinal adenopathy.

supplement via non-rebreathing mask as well as intravenous hydration was given. His overall symptoms gradually improved except for fever. A trial of aerosolized beta-2 agonist bronchodilator was given to relieve lower airway obstruction but no definite response was observed. Moreover, he still had high fever and looked very uncomfortable until the fifth day of hospitalization. Thus, we decided to follow his complete blood count, chest x-ray and CT scan of the chest. The laboratory findings displayed the hemoglobin of 10.3 gm/dl, white blood cell count  $35.6 \times 10^9 / l$  (6 % neutrophils, 29 % atypical lymphocytes, 26 % lymphocytes, and 39 % monocytes), platelet count of  $30.8 \times 10^9 / l$

Two days after admission, his chest x-ray demonstrated patchy infiltrations on the left upper lung field. Then, intravenous cefotaxime was initiated for

possible secondary bacterial infection. CT scan of the chest, performed on the fifth day of hospitalization, revealed soft tissue density lesion compatible with multiple lymph nodes wrapping around the left main bronchus. Narrowing of left main bronchus, atelectasis of anterior segment of the left upper lobe and the lingular lobe together with left pleural thickening and resolved pneumothorax were disclosed. (Figure 2.)

The EBV serology revealed significantly elevated EBV-viral capsid antigen IgM ( $>140$  u; cut off 20.94 u) and EBV-viral capsid antigen IgG 55.94 u (cut off 23.66 u) which were compatible with primary acute EBV infection. Additional laboratory findings, liver and kidney function tests yielded normal results. Blood culture was negative. His fever resolved on the seventh day of hospitalization. However, he later



**Figure 2.** Computerized tomographic scan of the chest was also performed on the fifth day of hospitalization and revealed soft tissue density lesion compatible with multiple lymph nodes wrap around the left main bronchus, causing narrowing of left main bronchus, atelectasis of anterior segment of left upper

developed generalized erythematous maculopapular rashes on his face, trunk, back and all extremities after receiving two days of cefotaxime. The rashes disappeared two days after discontinuing cefotaxime. His clinical symptoms gradually improved and he was discharged after three weeks with excellent condition. He was followed up 2 weeks later and looked healthy with normal chest radiograph. Furthermore, the second serological study revealed EBV-viral capsid antigen IgM of 45.64 u (cut off 19.55 u) and EBV-viral capsid antigen IgG of 31.96 u (cut off 22.21 u) which confirmed primary acute EBV infection.

## Discussion

The majority of infectious mononucleosis cases are asymptomatic and their pulmonary manifestations are extremely variable. The incidence of previously reported respiratory complications ranged between 2-11 %.<sup>(1, 5-6)</sup> Severe pulmonary complication is rare but potentially fatal.<sup>(7-9)</sup> There were a number of case series with pulmonary involvement but none of them had pneumothorax.

Possible mechanisms of pneumothorax in our patient might be the increased transpulmonary pressure and prolonged duration of alveolar expansion during protracted coughing. Moreover, uneven ventilation due to secretions obstruction in the airway also predisposed the expansible alveoli to overdistend and became rupture.<sup>(10)</sup> The pneumothorax was treated conservatively with 100 % oxygen and gradually resolved within seven days. Although pneumothorax can be caused by infection with gas-producing microorganisms<sup>(10)</sup>, there was no evidence of the usual bacterial organisms caused pneumothorax such as *S.aureus* or *K. pneumoniae* from sputum culture and

hemoculture in our patient. Furthermore, no lung cyst or bleb was demonstrated in the CT scan. The diagnosis of EBV infection in our patient was made by serological test which is a specific method for determining EBV infection. His serology results suggested primary acute EBV infection with high rise of VCA IgM as well as IgG that consistent with its acute infection.<sup>(11-12)</sup>

In summary, EBV infection can manifest in a large number of clinical pictures, one of them is pneumothorax. We believed that our case represented a unique clinical entity which describes EBV infection related pneumothorax.

## Acknowledgements

We appreciated the assistance of all pediatric house-staff in collecting all clinical data.

## References

1. Fermaglich DR. Pulmonary involvement in infectious mononucleosis. J Pediatr 1975 Jan; 86(1): 93 - 5
2. Schooley RT. Epstein-barr virus (infectious mononucleosis) In: Mandell GI, Bennett JE, Dolin R, eds. Mandell, Douglas, and Bennett's Principles and Practice of Infectious Diseases. 5<sup>th</sup> ed. New York: Churchill Livingstone, 2000: 1599 - 608
3. Sumaya CV, Ench Y. Epstein-Barr virus infectious mononucleosis in children I. Clinical and general laboratory findings. Pediatrics 1985 Jun; 75(6): 1003-10
4. Weinstein M. Hemoptysis and Epstein-Barr virus infection. Pediatr Infect Dis 2000 Aug; 19(8): 759 - 60

5. Alpert G, Fleisher GR. Complications of infection with Epstein-barr virus during childhood: a study of children admitted to the hospital. *Pediatr Infect Dis* 1984 Jul-Aug; 3(4): 304 - 7
6. Lander P, Palayew MJ. Infectious mononucleosis— a review of chest roentgenographic manifestations. *J Can Assoc Radiol* 1974; 25: 303 - 6
7. Haller A, von Segesser L, Baumann PC, Krause M. Severe respiratory insufficiency complicating Epstein-Barr virus infection: case report and review. *Clin Infect Dis* 1995 Jul; 21(1): 206-9
8. Veal CF Jr, Carr MB, Briggs DD Jr. Diffuse pneumonia and acute respiratory failure due to infectious mononucleosis in a middle-aged adult. *Am Rev Respir Dis* 1990 Feb; 141(2): 502 - 4
9. Andiman WA, McCarthy P, Markowitz RI, Cormier D, Horstmann DM. Clinical, Virologic, and serologic evidence of Epstein-Barr virus infection in association with childhood pneumonia. *J Pediatr* 1981 Dec;99(6):880-6
10. Montgomery M. Air and liquid in the pleural space, etiology and pathogenesis. In: Chernick V, Boat TF, Kendig EL, eds. *Kendig's Disorders of the Respiratory Tract in Children*. 6<sup>th</sup> ed. Philadelphia: W.B. Saunders, 1998: 403 - 4
11. Evans AS, Niederman JC, Cenabre LC, West B, Richards VA. A prospective evaluation of heterophile and Epstein Barr virus - specific IgM antibody tests in clinical and subclinical infectious mononucleosis: specificity and sensitivity of the tests and persistent of antibody. *J Infect Dis* 1975 Nov; 132(5): 546 - 54
12. American Academy of Pediatrics. [Epstein-Barr virus infections (infectious mononucleosis)]. In: Pickering LK ed. *Red Book: 2003 Report of the Committee on Infectious Diseases*. 26<sup>th</sup>ed. Elk Grove Village, IL: American Academy of Pediatrics; 2003: 271 - 3