

MR findings of the spine and the spinal cord in HIV patients

Sukalaya Lerdlum*

Pattraporn Chaowanapanja* Kanokporn Chutiwongthanaphat*

Lerdlum S, Chaowanapanja P, Chutiwongthanaphat K. MR findings of the spine and the spinal cord in HIV patients. Chula Med J 2006 Feb;50(2): 91 - 101

- Objective** : *To describe MR findings in HIV-infected patients, suspected spinal disease.*
- Design** : *Retrospective study.*
- Setting** : *Department of Radiology, King Chulalongkorn Memorial Hospital.*
- Material and Method** : *Spinal MR studies and medical records of 19 HIV-patients, clinically suspected spinal diseases in King Chulalongkorn Memorial Hospital from June 2001 to November 2003, were reviewed. Diagnoses were confirmed by CSF analysis and/or histopathological studies.*
- Results** : *All extradural lesions were tumors. All proven intramedullary lesions and some intradural-extramedullary lesions were infection. Some intradural-extramedullary lesions and multi-compartmental lesions were infection or tumors. Of these tumors, four cases were leiomyosarcoma and three were lymphoma. Leiomyosarcoma mimics meningioma or schwannoma. No spondylodiskitis case was found.*

Conclusion : *The spinal compartment was an advantageous for classifying group of disease in HIV-patients. All of the extradural lesions were tumors. Leiomyosarcoma should be included in the differential diagnosis of the lesions mimic meningioma or schwannoma in HIV-patients.*

Keywords : *Spinal MR findings, HIV patients, Spine and spinal cord lesion.*

Reprint request : Lerdlum S. Department of Radiology, Faculty of Medicine, Chulalongkorn University, Bangkok 10330, Thailand.

Received for publication. October 15, 2005.

สถาบันวิทยบริการ
จุฬาลงกรณ์มหาวิทยาลัย

สุกัลยา เลิศล้ำ, ภัทรภรณ์ เขาวนະปัญญา, กนกพร ชูติวงศ์ธนะภัทร. ลักษณะภาพ MRI ของกระดูกสันหลังและช่องไขสันหลังในผู้ป่วย HIV. จุฬาลงกรณ์เวชสาร 2549 ก.พ.;50(2): 91 - 101

- วัตถุประสงค์** : ศึกษาลักษณะภาพ MR (magnetic resonance) ของผู้ป่วย HIV ที่มีความผิดปกติทางไขสันหลัง
- รูปแบบการศึกษา** : การศึกษาแบบย้อนหลัง และพรรณนา
- สถานที่ศึกษา** : แผนกรังสีวิทยา โรงพยาบาลจุฬาลงกรณ์
- วิธีการศึกษา** : ศึกษาทบทวนภาพ MR และเวชระเบียนของผู้ป่วย HIV ที่มีความผิดปกติทางไขสันหลัง จำนวน 19 คน ที่มารับการตรวจรักษาที่โรงพยาบาลจุฬาลงกรณ์ ระหว่าง มิถุนายน 2544 - พฤศจิกายน 2546 โดยเปรียบเทียบผลการวินิจฉัยโรค กับผลการตรวจน้ำไขสันหลัง และ/หรือพยาธิวิทยา
- ผลการศึกษา** : พบว่ารอยโรคในส่วน extradura ทั้งหมดเป็นเนื้องอก รอยโรคในเนื้อไขสันหลังที่พิสูจน์ได้ทั้งหมด และในส่วน intradura-extramedulla บางรายเป็นการติดเชื้อ ผู้ป่วยที่มีรอยโรคในส่วน intradura-extramedulla บางรายและผู้ป่วยที่มีรอยโรคในหลายส่วนของไขสันหลัง พบว่าเป็นเนื้องอกหรือการติดเชื้อ
- สรุปผล** : การแบ่งรอยโรคตามส่วนไขสันหลัง รวมถึงรูปแบบ enhancement มีประโยชน์ในการจัดกลุ่มโรคออกเป็นเนื้องอก หรือการติดเชื้อในไขสันหลัง ลักษณะที่น่าสนใจอีกประการหนึ่งพบว่า spinal leiomyosarcoma ในการศึกษานี้มีรอยโรคคล้าย schwannoma หรือ meningioma จึงควรคิดถึงมากขึ้นในผู้ป่วยติดเชื้อ HIV
- คำสำคัญ** : ลักษณะรอยโรคจากภาพ magnetic resonance, ผู้ป่วย HIV, ความผิดปกติทางไขสันหลัง

A wide spectrum of diseases that affect the CNS in patients with AIDS include opportunistic infections, neoplasms and direct infection of the CNS by the human immunodeficiency virus. Approximately 30 % of patients with AIDS had neurological complications.⁽¹⁾ Only a small number of histologically proven spinal diseases, in this group of patients, have been described in radiological literature.

Our study documents the spectrum of MR abnormalities which involved the spinal column, spinal nerve roots, subarachnoid space, meninges, dura and paraspinal area in AIDS patients.

Material and Method

Medical records and spinal MR studies of 19 HIV-infected patients, who presented with neurological symptoms or signs suspected spinal disease, were reviewed retrospectively, by two neuroradiologists. The study included 19 patients, 10 men and 9 women, from June 2001 to November 2003, at King Chulalongkorn Memorial Hospital. The mean age of the patients was 34.6 year, ranged 22-65 year. All final diagnoses were confirmed by CSF analysis, surgical excision or biopsy. All of our patients underwent MR studies using GE SIGNA 1.5 Tesla. The imaging protocols were SE T1WI, FSE T2WI-fat suppression, GRE T2*WI, post contrast-enhanced SE T1WI-fat suppression with gadolinium 0.1 mmol /kg body weight. There were seven cervical spines, ten thoracic spines, nine lumbosacral spines, four whole spines and two brains included in our study. Follow-up studies were performed in two cases, 6-month follow up of one case and 8-month follow up of the other.

Results

The clinical findings of the 19 patients are shown in table 1. Weakness of lower extremities was the most frequent, loss of sensory level, back pain, bowel and bladder dysfunction being common. There were more than one clinical findings in each patient.

The 19 patients were classified into two groups. Six patients in the first group had normal CSF and/or histopathological studies. Two of six also revealed normal MR studies and 4 of 6 showed degenerative changes, which were not associated with HIV infection. The second group consisted of 13 patients, who had abnormal CSF analysis, abnormal histopathological or abnormal MR findings, which were associated with HIV infection.

The patients in the second group were categorized according to the site of the abnormality of the spinal compartment, shown in relationship to the group of diseases in table 2. The number of patients in each group of diseases is shown in table 3 and the combined categories between the spinal compartment and the group of diseases in these patients are shown in table 4.

Table 1. Neurological symptoms and signs in 19 HIV-patients.

Symptom and Sign	Number of patients
Leg weakness	14
Incontinence	6
Back pain	7
Numbness, burning	4
Paresthesia	2
Ataxia	2
Decrease sphincter tone	2

Table 2. Compartmental lesions on MRI findings in relationship to the group of diseases in 13 HIV patients with abnormal CSF analysis and/or histopathological studies.

Compartment	Patients (%)	Diseases
Extradural	2 (15.4 %)	Tumors
Intradural-extramedullary	5 (38.4 %)	Tumors or Infection
Intramedullary	2 (15.4 %)	Infection
Multicompartment	4 (30.8 %)	Tumors or Infection
Total number of patients	13 (100 %)	-

Table 3. Spine and spinal cord pathology in 13 HIV-patients.

Disease	Patients (%)
Infectious process	6 (46.2 %)
Tuberculous infection	1 (7.7 %)
Viral infection (cytomegalovirus 2, varicella -zoster virus1, herpes zoster virus1)	4 (30.8 %)
Fungal infection	1 (7.7 %)
Tumor	6 (46.2 %)
Leiomyosarcoma	4 (30.8 %)
Lymphoma	2 (15.4 %)
Lymphoma with herpes simplex viral infection	1 (7.7 %)
Total number of patients	13 (100 %)

Table 4. Correlation between spinal compartment and group of disease in 13 HIV-patients.

Compartment	Lymphoma	Leiomyo-sarcoma	VZV	CMV	HSV	HZV	TB	Crypto
ED	1	1						
ED + ID-EM	1	1						
ED + IM					1			
					lymphoma			
IM			1				1	
IM + ID-EM						1		
ID-EM		2		2				1

- IM = intramedullary lesion
- ID-EM = intradural-extramedullary lesion
- ED = extradural lesion
- VZV = varicella-zoster virus

- CMV = cytomegalovirus
- HSV = herpes simplex virus
- HZV = herpes zoster virus
- TB = tuberculosis
- Crypto = cryptococcosis

Of these 13 patients, six cases were proved to be infectious process, six cases were proved neoplastic lesions and one case had lymphoma of the vertebra and the extradural soft tissue concomitant with herpes simplex viral (HSV) infection in the subarachnoid space. The latter patient also had the

intramedullary lesion but biopsy of the cord lesion was not performed (Fig.1). Viral infection was the most common cause in the infectious group. The second most common causes of this group were tuberculosis (Fig.2) and cryptococcosis (Fig.3), equally.

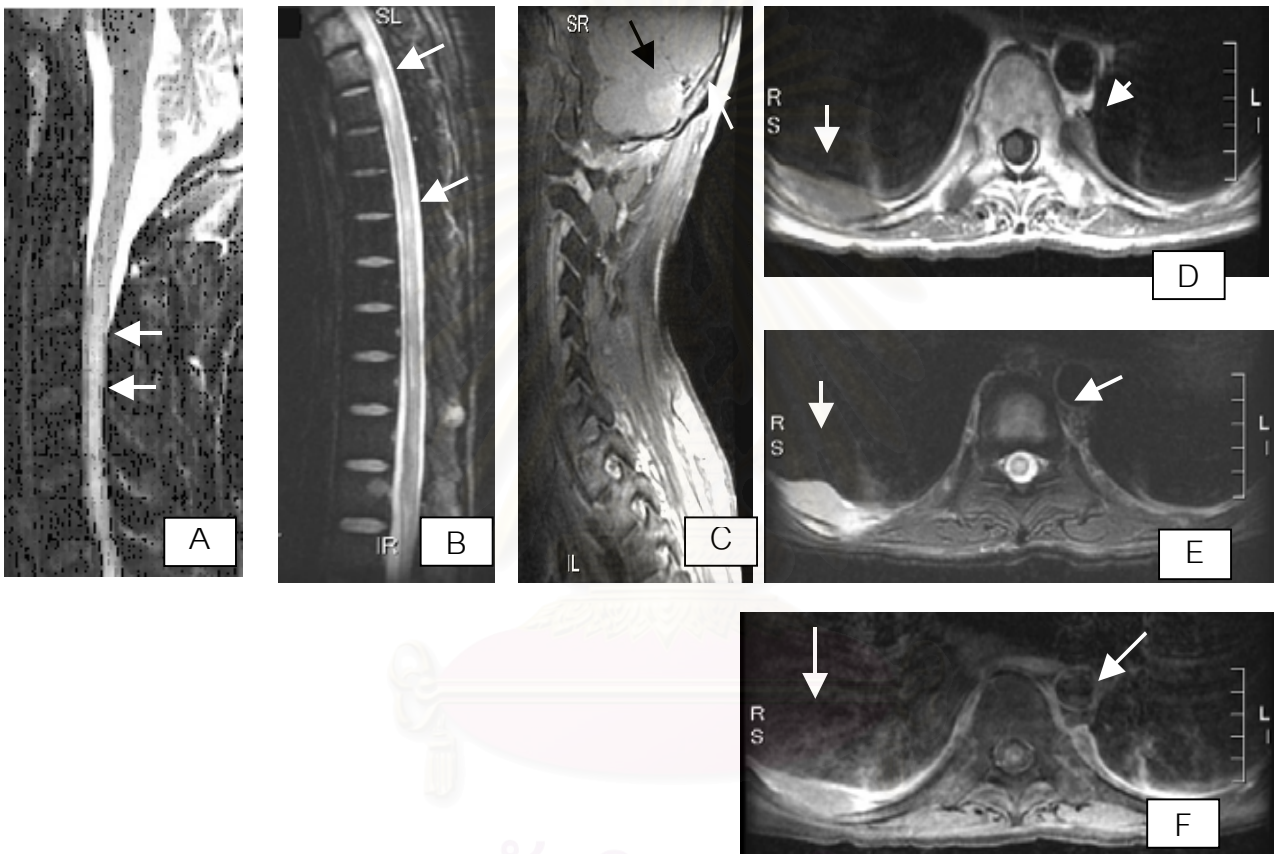


Figure 1. A 43-year-old man with an underlying of NHL, CMV retinitis, presented with weakness of lower extremities, impaired bowel and bladder function. MR study revealed diffuse enlarged cord from cervical level down to conus medullaris with inhomogeneous hypersignal intensity on T2WI (white arrows in A, B). On the post contrast T1WI with fat suppression, there is abnormal enhancement at the left cerebella hemisphere (black arrow in C) with focal bony destruction of adjacent occipital bone (white arrow in C). There are multiple bony hyposignal intensities on T1WI (arrow in D) hypersignal intensities on T2WI (arrow in E) at posterior ribs and transverse process at T10 level with extension to adjacent soft tissue, these lesions show enhancement on the post contrast study (arrow in F). Other bony lesions are also detected at L1, L2, L4, L5, S2 and S3 vertebrae.

Pathological finding of the soft tissue and bony lesions were proven of lymphoma and CSF studies reveals HSV infection. (The patient did not undergo the cord biopsy, thus the cord pathology were not known.)

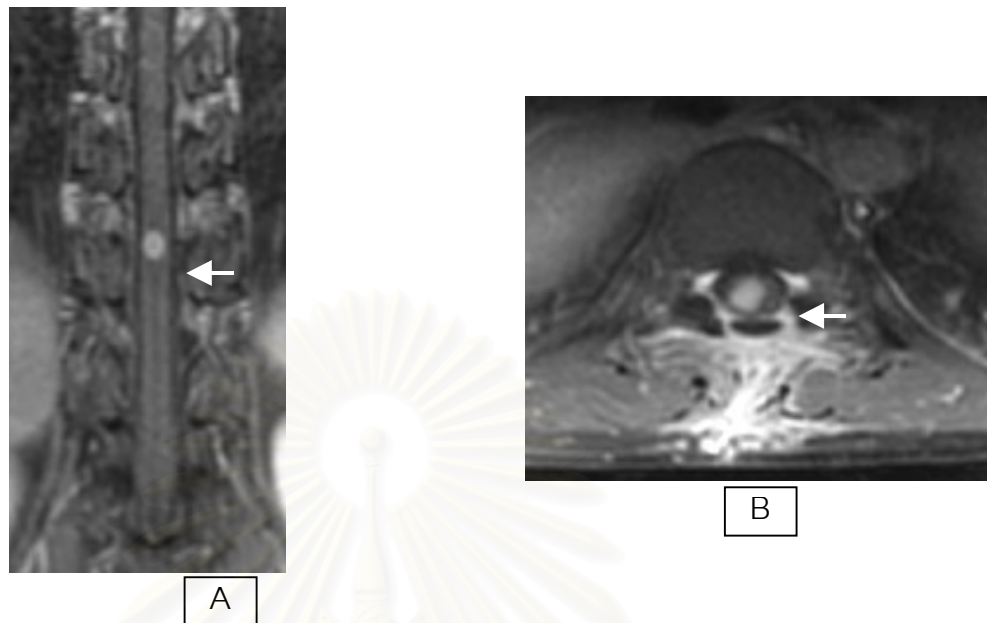


Figure 2. A 35-year-old woman, underlying of pulmonary tuberculosis, had weakness of lower extremities.

MR study revealed an 8x2.3 mm, intramedullary lesion at T10-11 level, that was isosignal intensity to cord on T1WI, hyperintensity on T2WI. After contrast injection, there was nodular enhancement in the central portion of the lesion, causing focal enlarged cord at T10-11 level (arrows in A and B).

Pathological diagnosis was tuberculous myelitis.

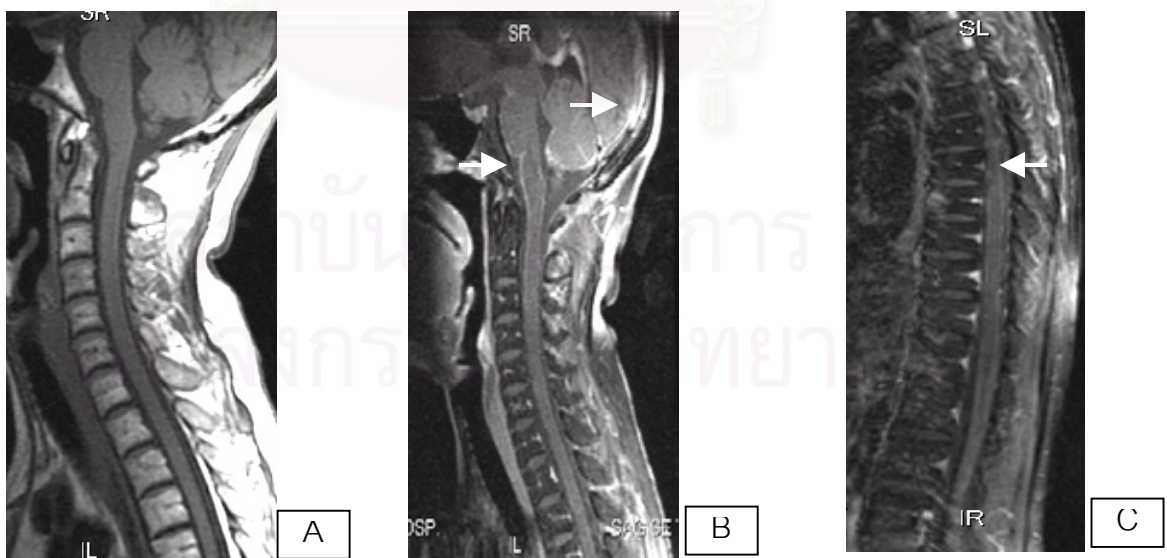


Figure 3. A 40-year-old woman with an underlying of tuberculous lymphadenitis, herpes zoster, had a history of bowel bladder dysfunction for five months and weakness of lower extremities for 3 months.

MR study revealed diffuse leptomeningeal enhancement along the surface of brainstem, cerebellum, cervical cord down to conus medullaris (arrows in B and C).

Cryptococcal meningitis was proved by CSF study.

Leiomyosarcoma was the most common cause in the neoplastic group (Fig. 4). They involved multiple spinal levels with the extradural and intradural extension. Some of them exhibited

internal hemorrhage, some enlarged the adjacent neural foramina and some demonstrated the dural attachment. All of them showed inhomogeneous enhancement after contrast administration.

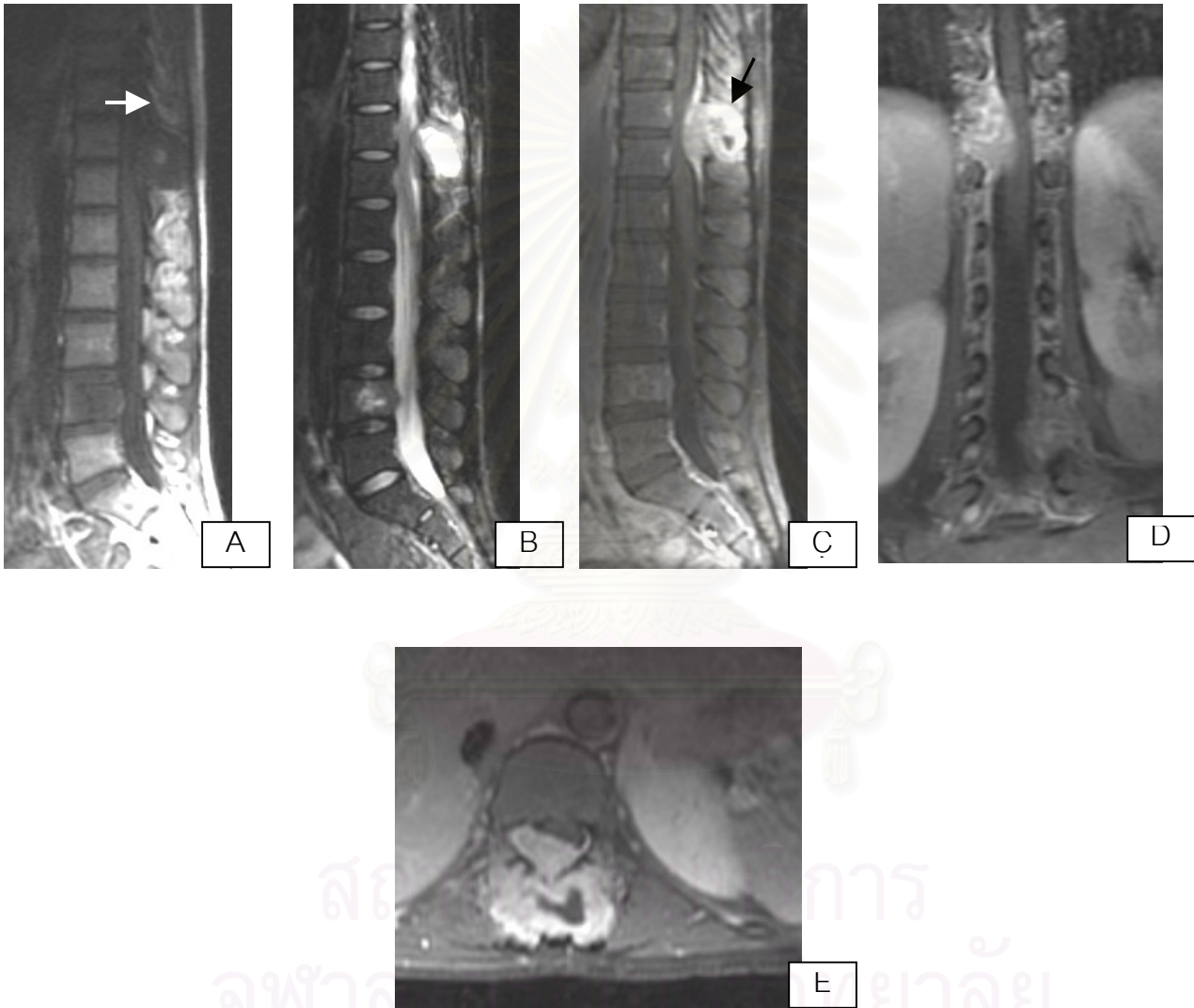


Figure 4. A 36-year-old woman had weakness of lower extremities, paraparesis and loss of sphincter tone.

MR study revealed two ill-defined border masses, located at the posterior element, paraspinal compartment and disc with epidural extension at T11-12 and L4, these were hypointense on T1WI (A), hyperintense on T2WI (B) with internal area of subacute hemorrhagic foci (arrows in A and C). After contrast injection, there were thick peripheral enhancement and minimal central enhancement (C-E).

Pathological diagnosis was leiomyosarcoma.

The infectious lesions involved the intramedullary compartment, intradural-extramedullary compartment or multi-compartments, but none was found in the extradural compartment.

There were coexistent HIV-associated diseases of the brain and other organs in most of the patients in this study. The coexistent diseases were found in both normal CSF analysis-normal histopathology group and HIV-related MR-abnormality group. Four cases of meningitis were proved, one case of viral, two cases of fungal and one case of tuberculous causes. There is also a case of coexistent progressive multifocal leukoencephalopathy (PML) of the brain. Other documented coexistent diseases are pulmonary tuberculosis, tuberculosis of the adrenal gland, tuberculous lymphadenitis, pneumocystis carinii pneumonia and ocular infection by viruses.

Discussion

The spinal compartment and enhancing patterns of the lesions were advantageous for classifying group of the disease in HIV-patients.

In our study, the extradural lesions with or without concomitant other compartmental lesion were verified tumors, 2 cases of leiomyosarcomas, 2 cases of lymphomas and 1 case of lymphoma with superimposed HSV infection. However, the common infection in the extradural compartment in other studies such as tuberculous spondylitis⁽²⁻⁴⁾ was not found in our study. This is due to the small population size, thus there is limitation to evaluate specific group of disease in this study.

All of the intradural-extramedullary lesions were verified either leiomyosarcoma or infection.

The interesting finding is that leiomyosarcoma was not uncommon in the HIV-patients in our institute, there were 4 cases of spinal involvement and 2 cases of the other organ involvement. The leiomyosarcoma was less than 2 % of soft tissue sarcomas, an incidence of only eight cases per million in the general population. This frequency is much higher than previously expected, particularly in the HIV-infected children.⁽⁵⁾ In this study, they involved multiple levels with the extradural and intradural extension. Some of these masses enlarged the neural foramina, giving dumbbell appearances which mimic the neurofibroma. Some of them demonstrated the dural attachment and thus grossly and radiologically resembled the meningioma. Thus, leiomyosarcoma should be included in the differential diagnosis of the spinal lesions that mimic neurofibroma or meningioma in HIV-patients.

In our study, the infectious process was found in all compartments, except pure extradural space. The leptomeningeal enhancement, enlarged conus medullaris and clumping nerve roots were favored infectious process, this is not different from other studies.^(1,4,6-8) Some previous reported studies have shown that CMV is the most common viral infection in AIDS, usually involves the cauda equina and inferior part of the spinal cord.^(1,4,6,7,9,10) Most of these patients also had CMV retinitis. Cerebrospinal fluid (CSF) study is the method of confirmation of CMV infection. Our study included two cases of CMV arachnoiditis, confirmed by CSF studies. Their MR findings were not different from the previous reports, showing leptomeningeal enhancement and clumping nerve roots. VZV infection has no specific imaging finding. There was one case of VZV arachnoiditis in our study,

showing distortion of the affected cord and mild enhancement. Detection of VZV-DNA from polymerase chain reaction (PCR) study of the CSF is the method of definite diagnosis.⁽¹¹⁾

Our study included one case of tuberculous myelitis at T10 -11, that is an of uncommon finding of spinal cord infection.⁽²⁾ According to some previous reports, there was an even distribution of spinal cord tuberculomas in the cervical and thoracic portions of the spinal cord. Also, the majority of these lesions were associated with foci of tuberculosis elsewhere in the body.^(3,12) Our case of tuberculous myelitis also had pulmonary tuberculosis.

In conclusion, the spinal compartment was an advantageous for classifying group of disease in HIV- patients. All lesions in our study involving extradural compartment were tumors. However due to too small population size in this study, the lack of spondylodiskitis case was probably in chance. The leptomenigeal enhancing pattern, enlarged conus medullaris and clumping nerve roots were common infectious process. Leiomyosarcoma was not uncommon in the HIV patients in our institute, thus it should be included in the differential diagnosis of the lesions that mimic schwannoma or meningioma in HIV-infected patients.

References

1. Thurnher MM, Post MJ, Jinkins JR. MRI of infections and neoplasms of the spine and spinal cord in 55 patients with AIDS. *Neuroradiology* 2000 Aug;42(8):551-63
2. Melhem ER, Wang H. Intramedullary spinal cord tuberculoma in a patient with AIDS. *Am J Neuroradiol* 1992 May-Jun;13(3):986-8
3. Sharif HS, Morgan JL, al Shahed MS, al Thagafi MY. Role of CT and MR imaging in the management of tuberculous spondylitis. *Radiol Clin North Am* 1995 Jul;33(4):787-804
4. Atlas SW. *Magnetic Resonance Imaging of the Brain and Spine*. Vol. 2. 3rd ed. Philadelphia: Lippincott Williams & Wilkins, 2002:1920-30, 1945,1953-60
5. Choi S, Levy ML, Krieger MD, McComb JG. Spinal extradural leiomyoma in a pediatric patient with acquired immunodeficiency syndrome: case report. *Neurosurgery* 1997 May;40(5):1080-2
6. Bazan C 3rd, Jackson C, Jirkins JR, Barohn RJ. Gadolinium-enhanced MRI in a case of cytomegalovirus polyradiculopathy. *Neurology* 1991 Sep;41(9):1522-3
7. Moulignier A, Mikol J, Gonzalez-Canali G, Polivka M, Pialoux G, Welker Y, Alain S, Thiebaut JB, Dupont B. AIDS-associated cytomegalovirus infection mimicking central nervous system tumor: a diagnostic challenge. *Clin Infect Dis* 1996 Apr;22(4):626-31
8. Berger JR, Sabet A. Infectious myelopathies. *Semin neurol* 2002 Jun;22(2):133-42
9. Gray F, Gherardi R, Trotot P, Fenelon G, Poirier J. Spinal cord lesions in the acquired immune deficiency syndrome (AIDS). *Neurosurgery Rev* 1990;13(3):189-94
10. Maschke M, Kastrup O, Diener HC. CNS manifestations of cytomegalovirus infections: diagnosis and treatment. *CNS Drugs* 2002; 16(5):303-15

11. Corral I, Quereda C, Antela A, Pintado V, Casado JL, Martin-Davila P, Navas E, Moreno S. Neurological complications of varicella-zoster virus in human immunodeficiency virus-infected patients: changes in prevalence and diagnostic utility of polymerase chain reaction in cerebrospinal fluid. *Neurovirol* 2003 Feb;9(1):129-35
12. Villoria MF, Fortea F, Moreno S, Munoz L, Manero M, Benito C. MR imaging and CT of central nervous system tuberculosis in the patient with AIDS. *Radiol Clin North Am* 1995 Jul;33(4):805-20



สถาบันวิทยบริการ
จุฬาลงกรณ์มหาวิทยาลัย