

การศึกษาประสิทธิภาพของกาวไฟบรินจากเลือดกระบือ ในการศัลยกรรมปลูกถ่ายผิวหนังทั้งชั้น โดย  
วิธี pinch และ punch ในสุกร



นายกฤตธี เดชขยง

จุฬาลงกรณ์มหาวิทยาลัย

CHULALONGKORN UNIVERSITY

บทคัดย่อและแฟ้มข้อมูลฉบับเต็มของวิทยานิพนธ์ตั้งแต่ปีการศึกษา 2554 ที่ให้บริการในคลังปัญญาจุฬาฯ (CUIR)  
เป็นแฟ้มข้อมูลของนิสิตเจ้าของวิทยานิพนธ์ ที่ส่งผ่านทางบัณฑิตวิทยาลัย

The abstract and full text of theses from the academic year 2011 in Chulalongkorn University Intellectual Repository (CUIR)  
are the thesis authors' files submitted through the University Graduate School.

วิทยานิพนธ์นี้เป็นส่วนหนึ่งของการศึกษาตามหลักสูตรปริญญาวิทยาศาสตรมหาบัณฑิต

สาขาวิชาศัลยศาสตร์ทางสัตวแพทย์ ภาควิชาศัลยศาสตร์

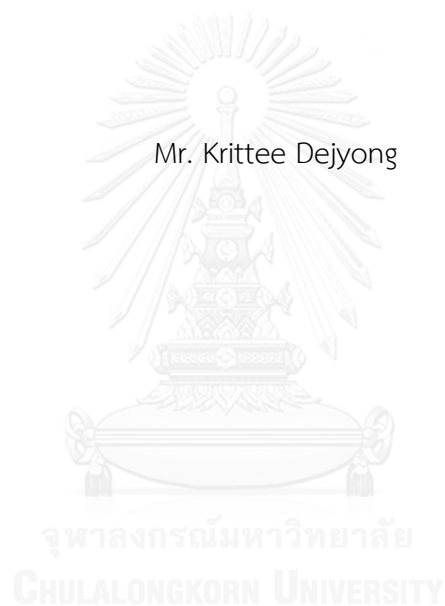
คณะสัตวแพทยศาสตร์ จุฬาลงกรณ์มหาวิทยาลัย

ปีการศึกษา 2557

ลิขสิทธิ์ของจุฬาลงกรณ์มหาวิทยาลัย

THE STUDY ON EFFICACY OF BUBALINE FIBRIN GLUE ON FULL-  
THICKNESS PINCH AND PUNCH SKIN GRAFTING IN PORCINE

Mr. Krittee Dejyong



A Thesis Submitted in Partial Fulfillment of the Requirements  
for the Degree of Master of Science Program in Veterinary Surgery

Department of Veterinary Surgery

Faculty of Veterinary Science

Chulalongkorn University

Academic Year 2014

Copyright of Chulalongkorn University

Thesis Title THE STUDY ON EFFICACY OF BUBALINE FIBRIN  
GLUE ON FULL-THICKNESS PINCH AND PUNCH  
SKIN GRAFTING IN PORCINE

By Mr. Krittee Dejjong

Field of Study Veterinary Surgery

Thesis Advisor Assistant Professor Sumit Durongphongtorn,  
D.V.M.,Ph.D.

Thesis Co-Advisor Associate Professor Theerayuth Kaewamatawong,  
D.V.M.,Ph.D.

---

Accepted by the Faculty of Veterinary Science, Chulalongkorn University in  
Partial Fulfillment of the Requirements for the Master's Degree

.....Dean of the Faculty of Veterinary Science  
(Professor Roongroje Thanawongnuwech, D.V.M.,Ph.D.)

THESIS COMMITTEE

.....Chairman  
(Professor Marissak Kalpravidh, D.V.M.,Ph.D.)

.....Thesis Advisor  
(Assistant Professor Sumit Durongphongtorn, D.V.M.,Ph.D.)

.....Thesis Co-Advisor  
(Associate Professor Theerayuth Kaewamatawong, D.V.M.,Ph.D.)

.....Examiner  
(Nan Choisunirachon, D.V.M.,Ph.D.)

.....External Examiner  
(Grisnarong Wongbandue, D.V.M.,Ph.D.)

กฤตธี เดชขยง : การศึกษาประสิทธิภาพของกาวไฟบรินจากเลือดกระบือ ในการศัลยกรรมปลูกถ่าย ผิวน้ำทั้งชั้น โดยวิธี pinch และ punch ในสุกร (THE STUDY ON EFFICACY OF BUBALINE FIBRIN GLUE ON FULL-THICKNESS PINCH AND PUNCH SKIN GRAFTING IN PORCINE) อ.ที่ปรึกษา วิทยาลัยพยาบาลบรมราชชนนีสมาธิราชบุรี, อ.ที่ปรึกษาวิทยาลัยพยาบาลบรมราชชนนีสมาธิราชบุรี: รศ. น.สพ. ดร. อธิวัฒน์ อธิวัฒน์, รศ. น.สพ. ดร. อธิวัฒน์ อธิวัฒน์, 46 หน้า.

การปลูกถ่ายผิวน้ำทั้งชั้นเป็นทางเลือกหลักสำหรับการรักษาในกรณีการสูญเสียผิวน้ำทั้งชั้นอย่างรุนแรงจากการบาดเจ็บ ในช่วงหลายร้อยปีที่ผ่านมา การปลูกถ่ายผิวน้ำทั้งชั้นด้วยวิธี pinch และ punch ใช้สำหรับการรักษาแผลที่เกิดเนื้อเยื่อแกรนูเลชัน แผลติดเชื้อเรื้อรัง และผิวที่ไม่สม่ำเสมอ กาวไฟบรินประกอบด้วยไฟบรินโนเจน และ ทรอมบิน ได้รับการพัฒนาขึ้นเพื่อใช้เป็นกาวสำหรับการผ่าตัดปลูกถ่ายผิวน้ำทั้งชั้น ในงานวิจัยนี้ใช้ไฟบรินโนเจนจากเลือดกระบือซึ่งมีความเข้มข้นของไฟบรินโนเจน และ คุณภาพ สูงสุด สกัดโดยการหมุนเหวี่ยงและการตกตะกอนที่อุณหภูมิต่ำ สำหรับการประยุกต์ใช้ในสุกรทดลองที่มีสุขภาพดี โดยดำเนินการผ่าตัด 2 ครั้ง การผ่าตัดครั้งแรก เป็นการสร้างบาดแผลแบบคู่ขนานลึกเต็มชั้นผิวน้ำทั้งชั้นบนหลังของสุกรทั้งฝั่งซ้ายและขวา และรอให้เกิดเนื้อเยื่อแกรนูเลชัน และการผ่าตัดครั้งที่สองทำในวันที่ 5 หลังจากการผ่าตัดครั้งแรก เป็นการปลูกถ่ายผิวน้ำทั้งชั้น โดยวิธี pinch และ punch โดยกลุ่มควบคุม จะวางชั้นกราฟตามวิธีปกติ แต่กลุ่มทดลองใช้กาวไฟบรินจากเลือดกระบือก่อนวางชั้นกราฟ ซึ่งจากการทดลองพบว่ามีความแตกต่างของการคงอยู่ของชั้นกราฟอย่างมีนัยสำคัญทางสถิติระหว่างกลุ่มที่ใช้กาวไฟบรินจากเลือดกระบือ ซึ่งมากกว่ากลุ่มควบคุม ( $p < 0.05$ ) แม้ว่าบาดแผลจะได้รับการปนเปื้อนจากเชื้อแบคทีเรียจำนวนมาก และพบว่าไม่มีการปฏิเสธ (เกรด 0) หรือ พบการปฏิเสธแบบไม่แน่ชัด (เกรด 1) ต่อการปลูกถ่ายผิวน้ำทั้งชั้น ในทั้งกลุ่มควบคุมและกลุ่มที่ใช้กาวไฟบรินจากเลือดกระบือ การสร้างหลอดเลือดใหม่ การเพิ่มจำนวนของ ไฟโบรบลาสต์ การอักเสบ และการเกิดเนื้อเยื่อเกี่ยวพัน จากการปลูกถ่ายผิวน้ำทั้งชั้นในทั้งสองกลุ่ม พบว่ามีความแตกต่างอย่างมีนัยสำคัญทางสถิติของจำนวนหลอดเลือดใหม่ระหว่าง 2 กลุ่ม โดยกลุ่มที่ใช้กาวไฟบรินจากเลือดกระบือพบปริมาณหลอดเลือดใหม่มากกว่ากลุ่มควบคุม ในวันที่ 3 หลังการผ่าตัด ( $p < 0.05$ ) และ พบความแตกต่างอย่างมีนัยสำคัญทางสถิติของการอักเสบในวันที่ 7 หลังการผ่าตัด ( $p < 0.05$ ) โดยกลุ่มที่ใช้กาวไฟบรินจากเลือดกระบือมีระดับต่ำการอักเสบกว่ากลุ่มควบคุม จากการทดลอง พบว่าประสิทธิภาพของกาวไฟบรินจากเลือดกระบือสามารถส่งผลดีในการใช้สำหรับศัลยกรรมปลูกถ่ายผิวน้ำทั้งชั้น โดยวิธี pinch และ punch ในสุกร จากระดับเข้มข้นของไฟบรินโนเจนที่สูง ซึ่งเกี่ยวข้องกับการอยู่รอดของการปลูกถ่ายผิวน้ำทั้งชั้น โดยอาจไม่เพียงแต่ช่วยลดการสะสมของเลือดและ / หรือของเหลวใต้ผิวน้ำทั้งชั้นที่ปลูกถ่าย การเคลื่อนไหวของผิวน้ำทั้งชั้นที่ปลูกถ่าย แต่ยังสามารถส่งเสริมการสร้างหลอดเลือดใหม่ของการปลูกถ่ายผิวน้ำทั้งชั้นด้วย

ภาควิชา ศัลยศาสตร์

ลายมือชื่อนิสิต .....

สาขาวิชา ศัลยศาสตร์ทางสัตวแพทย์

ลายมือชื่อ อ.ที่ปรึกษาหลัก .....

ปีการศึกษา 2557

ลายมือชื่อ อ.ที่ปรึกษาร่วม .....

# # 5675301231 : MAJOR VETERINARY SURGERY

KEYWORDS: BUBALINE / FIBRIN GLUE / FULL THICKNESS PINCH AND PUNCH SKIN GRAFT / PORCINE

KRITTEE DEJYONG: THE STUDY ON EFFICACY OF BUBALINE FIBRIN GLUE ON FULL-THICKNESS PINCH AND PUNCH SKIN GRAFTING IN PORCINE. ADVISOR: ASST. PROF. SUMIT DURONGPHONGTORN, D.V.M.,Ph.D., CO-ADVISOR: ASSOC. PROF. THEERAYUTH KAEWAMATAWONG, D.V.M.,Ph.D., 46 pp.

Skin transplantation or grafting is the principle choice for treating the severe skin losing injury over hundred years. Pinch and punch grafting which is indicated for the treatment of granulating wound, low-grade infection wound and irregular surface wound. Fibrin glue which is the combination of fibrinogen and thrombin has been developed to use as an adhesive for skin graft surgery. In this research used bubaline fibrinogen had the highest fibrinogen concentration and qualification which was extracted by cryoprecipitation and cryocentrifugation. For bubaline fibrin glue application, a healthy swine was operated two times. The first operation, parallel square areas with full skin depth wounds were created at dorsal of loin area on each side for creating the granulation wound. The second operation was done five days later for pinch and punch skin grafting. The control group was done by routine pinch and punch grafting, but the bubaline fibrin glue was added to the experimental group with before a graft was placed. There was a significant statistical difference of graft remaining, which remained graft pieces in the bubaline fibrin glue group were more than that in the control group ( $p < 0.05$ ) even if, wounds have been contaminated by numerous bacteria. The histological grading for skin graft rejection indicated no (grade 0) or indeterminate (grade 1) for the rejection of both control and bubaline fibrin glue group. The angiogenesis, fibroblast proliferation, inflammation and scarring of skin graft in both groups found that there was a statistical significant difference of the number of new microvessels between two groups on 3<sup>rd</sup> post-operative day ( $p < 0.05$ ), which the number of new microvessels in the bubaline fibrin glue group was more than that in the control group and there was a statistical significant difference of intensity of the inflammation on 7<sup>th</sup> post-operative day ( $p < 0.05$ ), which the intensity of the inflammation in the bubaline fibrin glue group was lower than that in the control group. From the experiment, the bubaline fibrin glue achieves advantages in the full thickness pinch and punch skin grafting due to high concentration of fibrinogen that relate to graft survival because it may not only reduce hematoma and/or seroma, movement of the graft but also promote the angiogenesis.

Department: Veterinary Surgery

Student's Signature .....

Field of Study: Veterinary Surgery

Advisor's Signature .....

Academic Year: 2014

Co-Advisor's Signature .....

## ACKNOWLEDGEMENTS

I would like to express my sincere gratitude to the 90th anniversary of Chulalongkorn university fund (Ratchadaphiseksomphot endowment fund) and Chulalongkorn university graduate scholarship to commemorate the 72nd anniversary of His Majesty King Bhumibol Adulydej for support and giving me a chance to study in honorable institute. In full gratitude I would like to acknowledge the following individuals who encouraged, inspired, supported, assisted, and sacrificed themselves to help my pursuit of a higher education degree. I would like to express my deepest gratitude to my advisor, Assist. Prof. Sumit Durongphongtorn for his excellent guidance, caring, patience, and providing me with an excellent atmosphere for doing research. I would like to thank my kind co-advisors, Assist. Prof. Passakorn Brikshavana and Assoc. Prof. Theerayuth Kaewamatawong for guiding my research for the past two years and helping me to develop my background in surgery and pathology. I would like to thank every teacher in the Department of Surgery, Faculty of Veterinary Science, Chulalongkorn University for giving me a lot of advices to develop my thesis especially Prof. Marissak Kalpravidh and Dr. Nan Choisunirachon. I would like to thank Dr. Grisnarong Wongbandue for his advantageous comments. A special thank goes to Mr. Somchai Lertsrisatit, who is not only providing me a pig but also assisting me for several times in the research. I would like to thank Mr. Somporn Wangsoongnoen from the Department of Animal Husbandry, who helped me collect blood from a buffalo which was a key at the beginning of the research. I would like to thank Mrs. Sujit Sirisawadi from the Department of Veterinary Physiology helped and gave her best suggestions in the laboratory. Many thanks were to my beloved friends, brothers and sisters who studied together during the master's degree program for helping me in the research. My research would not have been possible without their helps. Importantly, I would like to thank my parents, who always support and encourage me with their best wishes. Finally, I would like to thank my wife, Mrs. Kwanchanok Dejong, who is always there, cheering me up and standing by me through the good and bad times.

## CONTENTS

	Page
THAI ABSTRACT .....	iv
ENGLISH ABSTRACT .....	v
ACKNOWLEDGEMENTS .....	vi
CONTENTS .....	vii
List of Tables .....	ix
List of Figures.....	x
CHAPTER I INTRODUCTION .....	1
1.1 Important and Rationale.....	1
1.2 Objectives of Study.....	2
1.3 Research Frame .....	3
1.4 Advantage of Study .....	3
CHAPTER II REVIEW OF LITERATURES .....	4
2.1 Fibrin glue history.....	4
2.2 Sources of fibrin glue.....	5
2.3 Fibrin glue pathophysiology.....	6
2.4 Engraftment process.....	7
2.5 Pinch and punch skin grafting.....	9
2.6 The common causes of graft failure .....	10
2.7 The advantages of fibrin glue in skin grafting .....	10
2.8 Animal model .....	11
CHAPTER III MATERIALS AND METHODS.....	13
3.1 Bubaline fibrin glue preparation.....	13

	Page
3.2 Bubaline fibrin glue application .....	16
3.2.1 Animal .....	16
3.2.2 Anesthesia and surgical preparation .....	16
3.2.3 Surgical procedures .....	16
3.3 Variable evaluation .....	22
CHAPTER IV RESULTS .....	26
4.1 Bubaline fibrin glue and bacterial culture .....	26
4.2 The remaining of the survival graft pieces .....	26
4.3 Histology .....	30
4.3.1 Skin graft rejection .....	30
4.3.2 Skin graft healing .....	31
4.3.2.1. The angiogenesis .....	32
4.3.2.2. The number of fibroblasts .....	34
4.3.2.3. The intensity of the inflammation .....	36
4.3.2.4. The intensity of scarring .....	38
CHAPTER IV CONCLUSION, DISCUSSION, COMMENT .....	41
Conclusion .....	41
Discussion .....	41
Comment .....	46
REFERENCES .....	2
VITA .....	13



## List of Tables

- Table 1.** Grading system for rejection of full-thickness skin transplant which was modified from the system of Bejarano et al. (2004) by using histopathology features including perivascular infiltration, epidermal transformation and stromal changing. ... 23
- Table 2.** The results of remaining grafts in the bubaline fibrin glue group and the control group represented as remained graft and Wilcoxon Signed Rank Test. .... 29
- Table 3.** The number of new microvessels were presented as mean, standard deviation (SD) and p-value (paired-t test). There was statistically significant difference between the control group and the bubaline fibrin glue group on the 3rd post-operative day ( $p < 0.05$ ) ..... 33
- Table 4.** The number of fibroblasts were presented as mean, standard deviation (SD) and p-value (paired-t test). There were no statistically significant differences between the control group and the bubaline fibrin glue group on the 3rd, 7th and 14th post-operative days ( $p > 0.05$ ) ..... 35
- Table 5.** The intensity of inflammation was presented as mean, negative rank, positive rank, ties and p-value (Wilcoxon Signed Ranks Test). There was statistically significant difference ( $p < 0.05$ ) between the control group and the bubaline fibrin glue group on the 7th post-operative day ..... 37
- Table 6.** The intensity of inflammation was presented as mean, negative rank, positive rank, ties, and p-value (Wilcoxon Signed Ranks Test). There were no statistically significant difference ( $p > 0.05$ ) between the control group and the bubaline fibrin glue group on the 3rd, 7th and 14th post-operative days. .... 39

## List of Figures

- Figure 1.** Factors of fibrin deposition and breakdown. Thrombin breaks down the fibrinogen to fibrin monomer. The fibrin monomer is driven by factor XIII and calcium to polymerization process. Fibrin polymers form a stable structure that simplifies the growth of collagen-producing fibroblasts. The fibrin polymers can be broken down to fibrin degradation products (FDP) by plasmin, and plasmin can be inhibited by aprotinin (Currie et al., 2001)..... 7
- Figure 2.** The picture represents the engraftment process by time including plasmatic imbibition phase **(A)**: serum with nutrients accumulated between graft and bed, inosculation phase **(B)**: the new capillaries between graft and bed pushed through fibrin networks and vascular ingrowth phase **(C)**: the graft survived by disorganized capillaries which connected between graft and bed (Tobias and Johnston, 2013)..... 9
- Figure 3.** The bubaline fibrin glue extraction procedure by cryoprecipitation and cryocentrifugation which was modified from the method of Thorn et al. (2004). The bubaline blood was drawn from a buffalo and kept in the anticoagulant after that all of the steps of centrifugation and precipitation were done at low temperature to separate thrombin and fibrinogen from platelet rich plasma. .... 15
- Figure 4.** Size and location of the control and the experimental wounds on the loin area of a pig. There were two of 3x12 cm<sup>2</sup> wounds on each side of the spinal vertebrae. .... 17
- Figure 5.** Wound dressing on the pig. The wounds were covered by the polyethylene terephthalate, which was bonded with an absorbent layer consisting of a mixture of cotton and polyacrylonitrile fibers covered by a layer of an aperture non-woven cellulose fabric to protect the primary layer from damage **(a)**; wounds were covered with a highly conformable non-woven retention bandage coated with a hypoallergenic acrylic adhesive **(b)**; water-proofed by a water resistant, transparent, adhesive film ..... 18

- Figure 6.** 6 mm skin graft pieces which were punched by a sterile 6 mm disposable dermal biopsy punch key **(a)** and the donor site at the dorsal neck area after the skin grafts were taken away **(b)**..... 19
- Figure 7.** Eight 0.6 cm grafts and gap width between the grafts with 3mm of radius, 0.6 cm of gap width, and 1 cm away from the wound edges..... 19
- Figure 8.** The total of 36 grafting units were separated into 16 grafting units of the control group and 16 grafting units of the experimental group. The left cranial and the right caudal graft were the control groups, and the right cranial and the left caudal graft were the experimental group. .... 20
- Figure 9.** Eight 6 mm diameter of pits with 6 mm apart were prepared for eight skin grafts..... 21
- Figure 10.** The application of 0.1-0.2 ml of bubaline fibrin glue in the pits of the experimental group **(a)**, then a skin graft was placed in the pit and held by a forceps for 1-2 minutes **(b)**..... 21
- Figure 11.** Hematoxylin and eosin (H&E) staining for routine histopathology observation **(a)** and Masson's trichrome staining for highlight collagen fibers **(b)** (4x magnification). .... 22
- Figure 12.** Epidermis of the graft piece (the white arrow) with the necrotic area (red arrow) and the granulation area (yellow arrow) that was selected for the quantification of vessels, cells and fibers (4x magnification, H&E stain)..... 24
- Figure 13.** Scarring grading using color intensity and arrangement of the collagen in the graft-bed area; Grade I (unsystematic arrangement with pale blue staining of the collagen networks) **(a)**, Grade II (moderate connection of the collagen bundles with blue staining) **(b)**, and Grade III (continuously and regularly arrangement of the collagen fibers with dark blue staining) **(c)** (40x magnification, Masson's trichrome stain). .... 25
- Figure 14.** The remaining grafts on the 3<sup>rd</sup> post-operative day in comparison between the experimental group and the control group. There were six positive

difference pairs (The skin graft remained in the bubaline fibrin glue group remained but disappeared from the control group) and no negative difference pair (The skin graft remained in the control group remained but disappeared from the bubaline fibrin glue group)..... 27

**Figure 15.** The remaining grafts on the 3<sup>rd</sup> post-operative day were partially covered by debris and dry exudate. .... 27

**Figure 16.** The remaining grafts on the 7<sup>th</sup> post-operative day in comparison between the experimental group and the control group. There were five positive difference pairs (The skin graft remained in the bubaline fibrin glue group remained but disappeared from the control group) and no negative difference pair (The skin graft remained in the control group remained but disappeared from the bubaline fibrin glue group)..... 28

**Figure 17.** The remaining grafts on the 7<sup>th</sup> post-operative day were almost covered with dry exudate at the caudal part **(a)**. However, the survived grafts can be visualized in the enlarged picture of the bubaline fibrin glue group at the right cranial wound **(b)** and the left caudal wound **(c)**. .... 28

**Figure 18.** The wounds on the 14<sup>th</sup> post-operative day. All of the skin grafts were covered by abundant granulation tissue **(a)**; the enlarged picture of the left cranial wound of the experimental group showed trace of the wound that was not healed after sampling for histological examination (black arrow) **(b)**. .... 29

**Figure 19.** The histological tissues were biopsied on the 14<sup>th</sup> post-operative day from the control group **(a)** and the bubaline fibrin glue group **(b)**. In both pictures, the epidermal layer of the graft was adhered to granulation tissue of the bed (4x magnification, H&E stain). .... 30

**Figure 20.** Histological finding on the 3<sup>rd</sup> post-operative day of the control group represents a vessel was infiltrated by a small lymphocyte (white arrow) and an eosinophil (green arrow) indicating indeterminate rejection (grade I) (40x magnification, H&E stain). .... 31

- Figure 21.** Histological fining of the 3<sup>rd</sup> post-operative day of the bubaline fibrin glue group represents a vessel was infiltrated by a small lymphocyte (white arrow) and an eosinophil (green arrow) was seen that indicated indeterminate rejection (grade I) (40x magnification, H&E stain). ..... 31
- Figure 22.** Angiogenesis of the control group **(a)** and the bubaline fibrin glue group **(b)** on the 3<sup>rd</sup> post-operative day presented new microvessels (white arrow) with oval endothelial cells and old microvessels with spindle endothelial cells (black arrow) (40x magnification, H&E stain). ..... 32
- Figure 23.** The average number of new microvessels on the 3<sup>rd</sup>, 7<sup>th</sup> and 14<sup>th</sup> post-operative days in comparison between the control and the bubaline fibrin glue groups. The average number of new microvessels on the 3<sup>rd</sup> post-operative day of the bubaline fibrin glue group was noticeably more than that of the control group, but rapidly decreased to the comparable levels of the control group at the 7<sup>th</sup> and 14<sup>th</sup> post-operative days. .... 33
- Figure 24.** Fibroblasts surrounded by extracellular matrix (white arrows) in the control group **(a)** and the bubaline fibrin glue group **(b)** on the 7<sup>th</sup> post-operative day (40x magnification, H&E stain). ..... 34
- Figure 25.** The average number of fibroblasts on the 3<sup>rd</sup>, 7<sup>th</sup> and 14<sup>th</sup> post-operative days in comparison between the control and the bubaline fibrin glue groups. The average number of fibroblasts of the bubaline fibrin glue group was slightly more than that of the control group on the 3<sup>rd</sup> and 7<sup>th</sup> post-operative days, then was comparable to the level of the control group on the 14<sup>th</sup> post-operative day..... 35
- Figure 26.** The predominant inflammatory cells including neutrophil (N), mast cell (M), lymphocyte (L), plasma cell (P), histiocyte (H), and eosinophil (E) on the 3<sup>rd</sup> **(a)** and the 7<sup>th</sup> post-operative days **(b)** in the bubaline fibrin glue group (40x magnification, H&E stain)..... 36
- Figure 27.** The intensity of the inflammation on the 3<sup>rd</sup>, 7<sup>th</sup> and 14<sup>th</sup> post-operative days in comparison between the control and the bubaline fibrin glue groups. The intensity of the inflammation of the bubaline fibrin glue group was dropped,

opposition to the intensity of the inflammation of the control group, on the 3<sup>rd</sup> post-operative day, and continued decreasing until the 14<sup>th</sup> post-operative day. .... 37

**Figure 28.** The number of each type of the inflammatory cells types on the 3<sup>rd</sup>, 7<sup>th</sup> and 14<sup>th</sup> post-operative days in comparison between the control and the bubaline fibrin glue groups. The number of neutrophils of the control group was more than that of the bubaline fibrin glue group on the 3<sup>rd</sup> post-operative day and the number of plasma cells and eosinophils of the control group were more than those of the bubaline fibrin glue group on the 14<sup>th</sup> post-operative day. .... 38

**Figure 29.** The intensity of scarring of the control (**a**) and the bubaline fibrin glue groups (**b**) on the 7<sup>th</sup> post-operative day which were compared by color intensity and arrangement of collagen fibers (40x, Masson's trichrome stain)..... 38

**Figure 30.** The intensity of the scarring on the 3<sup>rd</sup>, 7<sup>th</sup> and 14<sup>th</sup> post-operative days in comparison between the control and the bubaline fibrin glue groups. The intensity of the scarring of the bubaline fibrin glue group was steadily increased, while the intensity of the control group slightly dropped on the 7<sup>th</sup> post-operative day. .... 40

**Figure 31.** The picture represents the graph rejection phases which presented by three phases; early ischemic phase, specific intense immune phase and late ischemic phase which occurred within 12<sup>th</sup> post-operative day (Zweifach et al., 2014). .... 44



## CHAPTER I

### INTRODUCTION

#### 1.1 Important and Rationale

In severe skin losing injury cases such as burn injury and large skin defect due to surgery or marked skin trauma, skin transplantation or grafting is the principle choice for treatment over 3000 years. The first use of the skin graft was reported in India in ancient Sanskrit texts around 2500-3000 BC. The gluteal skin transplant was used to treat the amputated nose (Mobley et al., 2002). Since then, the skin graft has been using. There are many types of skin graft which are developed for several trauma conditions, for example split thickness skin graft, split thickness mesh graft, full thickness mesh graft, full thickness unmeshed graft, strip graft, stamp graft, paw and pad graft, mucosal graft, and pinch and punch graft. These skin grafts are used for varied wound conditions (Tobias and Johnston, 2013). One of those is the pinch and punch graft which is a round small skin piece placed on the granulation wound bed with ordinal spacing between the graft pieces. The graft harvesting can be cut (pinch) or punched by a disposable keys dermal biopsy punch (punch graft). The pinch and punch grafting is indicated for the treatment of granulating wound, small wound on the limbs, low-grade infection wound and irregular surface wound.

The causes of skin grafting failure vary, but the common causes are hematoma and/or seroma underneath the graft, movement of the graft, and the defect at wound bed. The hematoma and/or seroma disturb adhesion between the graft and the wound bed, and prevent nourishment of the graft. Movement of the graft plays one of the major causes of the graft failure due to the breaking of the delicate connective tissue between the graft and the wound bed. The defects of the wound bed are poor vascularity, and infection, especially the bacteria that stimulates inflammatory mechanism and release of the enzyme and/or inflammatory substances breaking the connective tissue between the graft and the wound bed (Teh, 1979). For an increasing



successful outcome of skin graft surgery, the fibrin glue has been produced and developed to use as one of the currently tissue adhesive for skin graft surgery. The fibrin glue is the natural biological substance that helps the normal coagulation mechanism and adhesion between the tissues. After the injury, fibrins and fibronectins, from the circulation, rapidly deposit in the wound. A few days later, incoming fibroblasts, macrophages and migrating keratinocytes deposit in the fibronectins (Clark, 1993b). The preparation methods of fibrinogen rich plasma and thrombin can be done using cryoprecipitation or chemical precipitation but Thorn et al described that the preparation by cryoprecipitation can preserve platelet derived growth factor and transforming growth factor beta which enhance wound healing (Thorn et al., 2004).



Sources of fibrinogen rich plasma were derived from human, bovine, equine, ovine, porcine or bubaline. In the case of bubaline, it is shown that bubaline fibrinogen has higher efficacy for sciatic nerve repair in rat than that of the bovine, equine and commercial human fibrinogen (Tisseel™, Baxter) (Viterbo et al., 1994). In addition to a Thomazini-Santos et al. study showed that bubaline fibrinogen from cryoprecipitate fibrinogen preparation had the highest fibrinogen level and efficacy compared with the bovine, equine, and ovine fibrinogen. Average levels of fibrinogen were 664 mg/dl in bubaline, 375.5 mg/dl in human, 267 mg/dl in ovine, 240 mg/dl in equine, and 218.33 mg/dl in bovine (Thomazini-Santos et al., 1998). The adhesive strength could be increased by increasing the fibrinogen concentration level (Saltz et al., 1991; Sierra et al., 1992). Nevertheless, there are a few studies on the bubaline fibrin glue for instant, in 1994 a study showed the efficacy of thrombin-like from snake venom combined with bubaline fibrinogen that were used in rat colonic anastomosis without suturing and another study in 2000 described using the thrombin-liked enzyme from snake venom merged with the cryoprecipitated bubaline fibrinogen in ovine cesarean operation (Chalhoub et al., 2000; Leite et al., 2000).

## **1.2 Objectives of Study**

The objectives of the study are to evaluate the efficiency of bubaline fibrin glue on pinch and punch skin grafting surgery in porcine.

### 1.3 Research Frame

This study was designed to apply the bubaline fibrin glue as a tissue adhesive to pinch and punch skin grafting in a porcine, which was prepared as the experimental model. The bubaline fibrin glue was extracted from the fresh bubaline blood by using cryoprecipitation and cryocentrifugation method. The bubaline fibrin glue was applied in the pinch and punch skin graft, then evaluated the remaining of survival graft pieces and histological data on the 3<sup>rd</sup>, 7<sup>th</sup> and 14<sup>th</sup> post-operative days.

### 1.4 Advantage of Study

The study was benefit directly to the support and activation of producing and using the bubaline fibrin glue in pinch and punch skin graft surgery in porcine but it may apply in the other species, for example canine and feline, which need continuing study in the future. Consequently, this study may promote the production of the buffalo for medical and veterinary profession other than milk and meat production; this would bring about more buffalo farming because the population of Thai buffaloes decreases 18% per year and only 1.3 million left in 2013 compared with 3.3 million in 1996 as a result of the diminution of the rice fields, the replacement of buffalo by machineries, and the industry immigration to the rural areas, and much more (Uriyapongson, 2013).

## CHAPTER II

### REVIEW OF LITERATURES

#### 2.1 Fibrin glue history

The first evidence of the fibrin glue or fibrin sealant used as a hemostatic agent in military human was reported by Bergel in 1909 (Bergel, 1909). In 1940, bovine thrombin and fibrinogen were applied to cure the injured nerve in animal models (Young and Medawar, 1940). The preliminary report of using the fibrin glue in skin grafting by Cronkite et al. and Tidrick et al. was reported in 1944 (Cronkite et al., 1944; Tidrick and Warner, 1944). They combined human fibrinogen and rabbit thrombin to make as a sealing agent in skin grafting, after that the fibrin glue has been widely developed and used in human medicine. The early commercial fibrin glue was developed in combination between human fibrinogen and human thrombin, and has been used in Europe since 1972 (Spotnitz, 2010). From the beginning, the application of the fibrin glue needs hemostat, sealing agent, and drugs or other bioactive delivered agents (Mintz et al., 2001). Since 1944, the fibrin glue has been continuously developed and used for skin grafting to reduce skin grafting failure because the important characteristic of the fibrin glue is not only tissue adhesive but also hemostatic. However, the clinical application of the combination between human fibrinogen and bovine thrombin was reported in 1985 (Dresdale et al., 1985). Because of fibrin glue efficacy, the combination of fibrinogen and thrombin was used as a hemostatic agent over a century (Bergel, 1909). Since then, the fibrin glue has been used as the hemostatic agent in many procedures and conditions; for instance, vascular anastomosis, burn wound, anal fistula repair, endonasal operation, periodontal flap surgery, ocular surgery, hepatobiliary and pancreatic surgery, splenic rupture, and tears of many visceral organs (Martinowitz and Spotnitz, 1997; Vaiman et al., 2002; Gerber and Finn, 2005; Jathal et al., 2008; Branski et al., 2011; Park et al., 2011; Ardakani et al., 2012; Simo et al., 2012).

However, the U.S. Food and Drug Administration (FDA) delayed the approval until 1998 due to the concern about the viral transmitted disease (Hile, 1978). The approved indications of the fibrinogen by FDA are haemostasis in specific surgery, the colonostomy sealing and attachment of the graft in the burned wound (Spotnitz and Burks, 2008). However, the characteristics of the fibrin glue that can be used without FDA approval are sealant, adhesive, tissue engineering, drug delivery, fistula closure (Chung et al., 2009), adhesion prevention (Ruggiero et al., 2008), anastomosis construction, endothelization, seroma reduction, drain removal, meshes fixation (Fortelny et al., 2008), and stem cell implantation (Berruyer et al., 1993).

## 2.2 Sources of fibrin glue

The fibrin glue components are combination of concentrated fibrinogen and thrombin with calcium and factor XIII results in a coagulum, the final stage of coagulation products. The fibrinogen for clinical use can be collected from the patient (autologous), another animal of the same species (homologous), and animal with different species (heterologous). The autologous fibrinogen has the advantage of the decreased chance of transmitted disease, but it is not possible in patient with bleeding or hematologic disorders. The heterologous fibrinogen rich plasma can be used if the patient species has poor plasma fibrinogen concentration level, but cross-linked species transmission disease should be considered for example the bovine spongiform encephalopathy (Joch, 2003).

Thrombin can be autologous, homologous and heterologous similar to the fibrinogen but there are risks associated with using bovine thrombin combined with human fibrinogen. The development of anti-bovine factor V during the first use may cross-react with patient factor V, and anaphylaxis to the bovine thrombin subsequently occur. The use of autologous thrombin could be safer and less side effects (Zehnder and Leung, 1990; Bänninger et al., 1993; Berruyer et al., 1993; Israels and Israels, 1994; Leroy-Matheron et al., 1999).

The fibrinogen from human and bovine thrombin is commercially available, for example, Tissucol™ (Baxter), Tisseel™ (Baxter), Evicel™ (Johnson and Johnson), Beriplast™ (ZLB Behring), Quixil™ (Johnson and Johnson), and Tachosil™ (Nycomed), which are pooled cryoprecipitate human fibrinogen and fibronectin combined with factor XIII prepared for mixing with bovine or human thrombin and calcium. Sources of fibrinogen rich plasma were derived from bovine, equine, ovine, porcine or bubaline. In the case of bubaline, it is shown that bubaline fibrinogen has higher efficacy for sciatic nerve repair in rat than that of the bovine, equine and commercial human fibrinogen (Tisseel™, Baxter) (Viterbo et al., 1994).

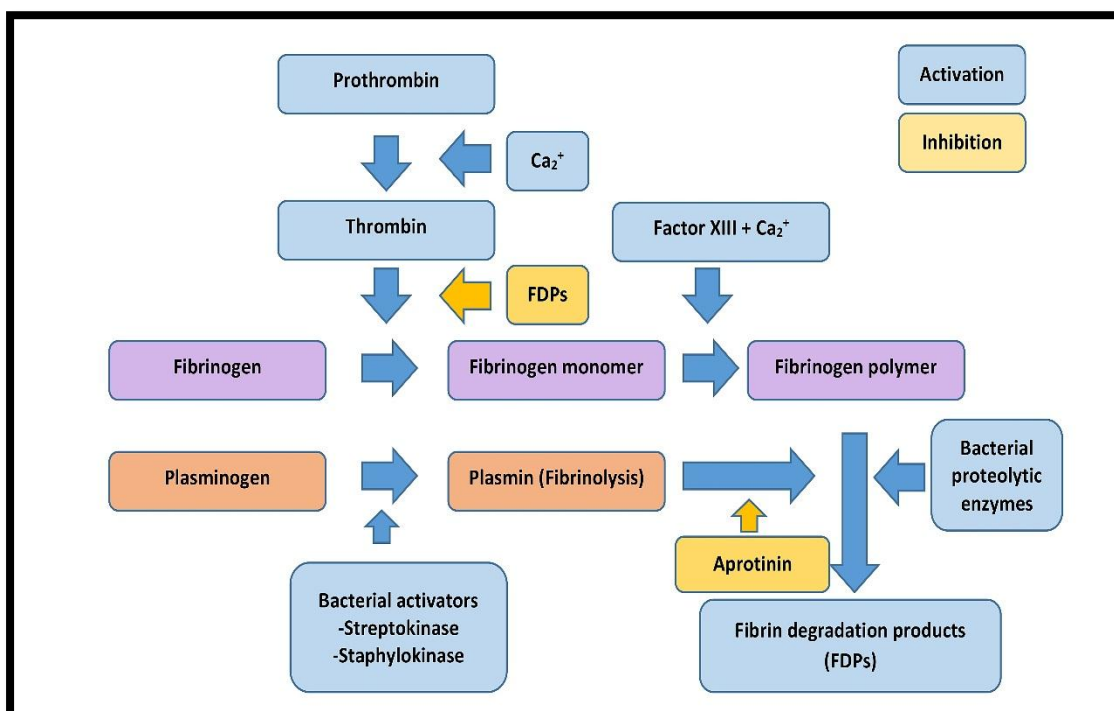
In 1998, Thomazini-Santos et al. showed that bubaline fibrinogen from cryoprecipitate fibrinogen preparation had the highest fibrinogen level and efficacy compared with the bovine, equine, and ovine fibrinogen. Average levels of fibrinogen were 664 mg/dl in bubaline, 375.5 mg/dl in human, 267 mg/dl in ovine, 240 mg/dl in equine, and 218.33 mg/dl in bovine (Thomazini-Santos et al., 1998). However, there are a few studies on the bubaline fibrin glue. In 2000, Leite et al. showed the efficacy of thrombin-like from snake venom combined with bubaline fibrinogen that were used in rat colonic anastomosis without suturing (Leite et al., 2000). In addition to Chalhoub et al. that used the thrombin-liked enzyme from snake venom merged with the cryoprecipitated bubaline fibrinogen in ovine cesarean operation (Chalhoub et al., 2000).

### **2.3 Fibrin glue pathophysiology**

After the injury, fibrin and fibronectin, from the circulation, rapidly deposit in the wound. A few days later, incoming fibroblast, macrophage and migrating keratinocyte deposit in the fibronectin.

Fibroblasts produce type I collagen and other matrix molecules which deposit in the local surroundings, then fibroblasts hold fibrins and fibronectins in the matrix in the wound after that, keratinocytes at the wound activate integrin receptors for fibronectin and prepare the wound surface receptors for their migration across the

matrix. Fibronectins bind specifically to fibrins, which are covalently cross-linked to the fibrin alpha chain by activating factor XIIIa (Hsieh and Chen, 1983; Toda et al., 1987; Clark, 1990; Matsuka et al., 1997). The mechanism of fibrin glue mimics natural coagulation pathway to form a fibrin clot. The clot can be degraded by natural enzymes found in high concentration in the inflamed tissue (Figure 1) (Radosevich et al., 1997; Dunn and Goa, 1999).



**Figure 1.** Factors of fibrin deposition and breakdown. Thrombin breaks down the fibrinogen to fibrin monomer. The fibrin monomer is driven by factor XIII and calcium to polymerization process. Fibrin polymers form a stable structure that simplifies the growth of collagen-producing fibroblasts. The fibrin polymers can be broken down to fibrin degradation products (FDP) by plasmin, and plasmin can be inhibited by aprotinin (Currie et al., 2001).

## 2.4 Engraftment process

The harvested skin is instantly deteriorated after being separated from the donor site. The regeneration is merely begun when the grafts obtain nutrient supply

from recipient bed. The regeneration rate must be dominated over the degeneration rate to survive the graft especially on seventh and eighth postoperative day.

To understand the engraftment process. The harvest skin is instantly deteriorated after being separated from the donor site. The regeneration is merely begun when the grafts obtain nutrient supply from recipient bed. The regeneration rate must be dominated over the degeneration rate to survive the graft, especially on 7<sup>th</sup> and 8<sup>th</sup> post-operative day (Davis and Traut, 1925; Pope, 1988). There are four phases of graft healing, including adherence phase, plasmatic imbibition phase, inosculation phase and vascular ingrowth phase (Figure 2) (Tobias and Johnston, 2013).

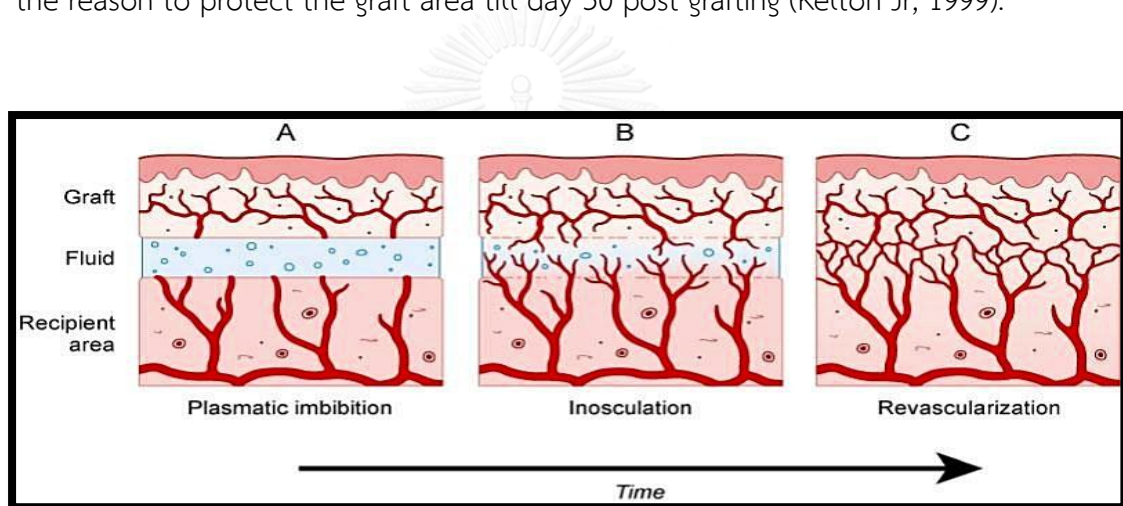
**Adherence phase** is the phase that starts rapidly post grafting with fibrin strands linking between collagens and elastins. The fibrin polymerization strands are strongest in eight hours post grafting. Three days later, the fibroblasts, leukocytes and phagocytes infiltrated through the fibrin networks and change fibrinous network to fibrous adhesion. The changing process is complete on the 10<sup>th</sup> post operation day (Tavis et al., 1976; Swaim, 1980; Swaim, 1990; Grabb and Smith, 1991).

**Plasmatic imbibition phase** is the phase of fluid accumulation. Immediately after the graft is harvested, the vessels constrict and dilate again after placement on the recipient bed. Serum, erythrocytes and neutrophils are accumulated between the graft and bed, and then absorbed into the graft vessel by capillary force as a result of nourishing and dilated vessel of the graft. Hemoglobins and its fragment products cause cyanotic presentation on the graft. Before active function of venous drainage and lymphatic system on the 8<sup>th</sup> day post grafting, the fluid is drained through the interstitial space slowly and brings about the edematous appearance on the 2<sup>nd</sup> -3<sup>rd</sup> day post grafting (Converse et al., 1957; Birch et al., 1969; Converse, 1977).

**Inosculation phase** is an anastomosis phase. This phase is shown obviously between the 2<sup>nd</sup> -3<sup>rd</sup> day post grafting. The capillaries from the recipient bed grow and connect the graft end vessels by the assistance of fibrin scaffolds. The flow rate of the

anastomosis vessels is normal on the 5<sup>th</sup> to 6<sup>th</sup> day post grafting (Birch et al., 1969; Converse et al., 1975; Pavletic, 2011).

**Vascular ingrowth phase** is a revascularization phase. The vessels continue to grow from the platform to the dermis or preexisting graft vessels. Recently formed vessels are tortuous and unsystematic dilated. The appearances of the graft may be light reddish by day 3-4 post grafting, pink or reddish by day 7-8 post grafting, and returns normal pale pink color by day 14 if the graft survives (Tobias and Johnston, 2013). Reinnervation of full-thickness skin graft begin about day 21 post grafting. That is the reason to protect the graft area till day 30 post grafting (Kelton Jr, 1999).



**Figure 2.** The picture represents the engraftment process by time including plasmatic imbibition phase (A): serum with nutrients accumulated between graft and bed, inosculation phase (B): the new capillaries between graft and bed pushed through fibrin networks and vascular ingrowth phase (C): the graft survived by disorganized capillaries which connected between graft and bed (Tobias and Johnston, 2013).

## 2.5 Pinch and punch skin grafting

Pinch and punch grafts are categorized into island grafts which are placed on a granulation tissue. The graft will be placed below the wound surface level to shield the graft from external force such as rubbing (Tobias and Johnston, 2013). The



indications for using this graft are granulating wounds, wounds at the limb, contaminated wounds, low grade infection wounds, and wounds with irregular surface.

The reliability of pinch and punch grafts are high because of the encircle granulation tissue. Similar to the island graft, the pinch and punch graft has a poor cosmetic appearance and thin epithelial covering of new skin layer after healing. Moreover, it has a weak point of excessive bleeding of the graft bed causing the graft floating out of the recipient site and delayed graft revascularization. However, there are many patients in veterinary medicine that require the most successful grafting technique.(Tobias and Johnston, 2013)

## **2.6 The common causes of graft failure**

The three major causes of graft failure are separation of the graft from the bed, graft movement and infection. All of these three causes are break the fibrin network between grafts and wound bed, resulting in revascularization and nourishment graft failure. The graft separation is due to fluid accumulation such as hematoma, seroma or exudation. The infection is injurious to graft survival, not only by exudates but also bacterial enzymes. Beta-hemolytic streptococci and *Pseudomonas spp.* are virulent bacteria because they generate plasmin and proteolytic enzymes that break fibrin polymers to fibrin degradation products (FDP). Moreover, *Pseudomonas spp.* produces elastase to degrade elastin that attaches to fibrins (Ünal et al., 2005; Pavletic, 2011).

## **2.7 The advantages of fibrin glue in skin grafting**

### **Haemostasis**

In 1984, Ihara and others applied the fibrin glue in burn patient for hemostasis and fixation of transplanted skin. The result found reduction in blood loss, and the blood transfusion volume both peri-operation and post-operation (Ihara et al., 1984). A multicenter study by McGill et al. (1997) on skin grafting in 95 burn patients found 34 patients receiving fibrin glue had estimated blood loss/graft ratio of 0.5 +/- 0.3 ml/cm<sup>2</sup> compared with the 0.98 +/- 2.4 ml/cm<sup>2</sup> of control patient (McGill et al., 1997).

### Graft adherences and take

In 1983, Vibe and Pless used fibrin glue to adhere split thickness skin graft with a success rate of 88%. The success rate was decreased to 44% in the group without fibrin glue in the mobile muscle or nearly skin fold area (the area that is difficult to place the graft) (Vibe and Pless, 1983). Seven years later, Stuart et.al applied the fibrin glue to split thickness skin graft in 26 patient hands and the result found the success 99 % graft take (Stuart et al., 1990). Most of the education about burn was experimented on rats, which inflicted with deep partial thickness burns, which the experiment demonstrated progressive deterioration from partial thickness burn wound to deeper wound because of fibrinolysis within 3 days post injury (Fang et al., 1997). Fibrinolysis was activated at 2 hours, post injury and inhibited by 24 hours till day 10 post injury (last experimental day). So the fibrin glue may have a prolonged effect on the burn wound as mentioned above (Fang et al., 1997).

### Antibacterial activity

An experiment in the split thickness skin graft infected by *Staphylococcus aureus* more than  $10^5$  bacteria/gram tissue found that the fibrin glue group had the ability of restoring graft attaches to the normal levels (Jabs Jr et al., 1992). Another success report of Vedung and Hedlund in 1993 used fibrin glue with skin grafting on mildly infected burn wounds in the axillas, perineum, and the gluteal folds. The advantages outcome may be due to the enhancement of the phagocytic activity in fibrin and/or a saturation of the bacterial proteolytic enzymes by the exogenous fibrin. The growth of bacteria is sluggish in a clot of fibrin glue (Vedung and Hedlund, 1993).

### 2.8 Animal model

The perfect skin grafting experimental animal species is porcine because it is commonly used as the wound healing study model in medical experiments because it has suitable properties such as the mimic physiological function or disease, availability, easy handling, long survival for functioning, fit with commonly used animal housing, and a suitable size for multiple sample. The porcine skin is hairless and has tight attachment between skin and subcutaneous similar to human. In addition,

cutaneous blood supply and wound healing characteristics are similar, though the porcine skin is thicker and less vascularity than the human skin (Sullivan et al., 2001). For all of these reasons, the porcine is the suitable model for plastic surgery and wound healing study.



## CHAPTER III

### MATERIALS AND METHODS

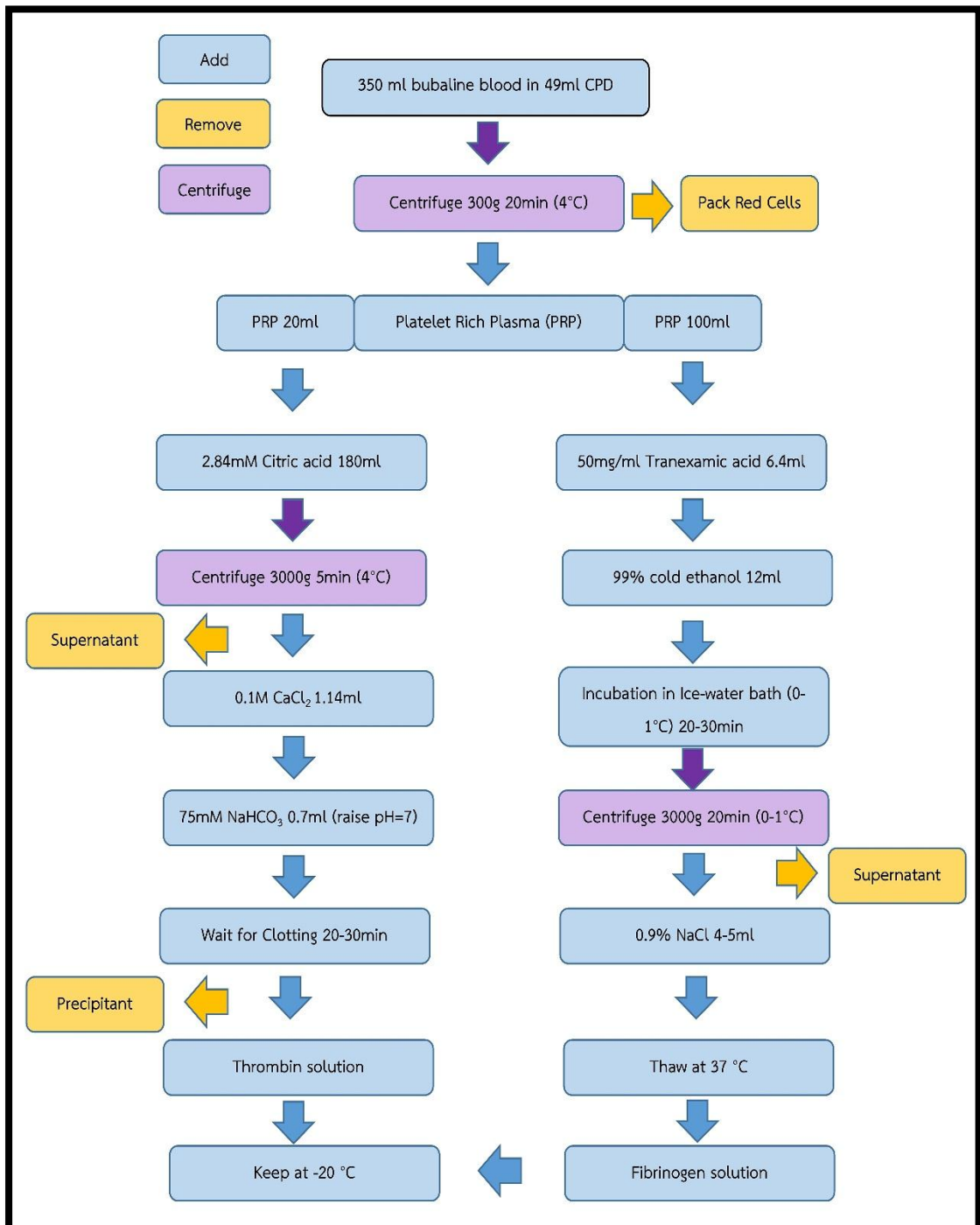
#### 3.1 Bubaline fibrin glue preparation

The preparation methods of fibrinogen rich plasma and thrombin have been continuously developed from the beginning and one of the most effective cryoprecipitation methods was described by Thorn et al (2004). In this research the procedure was modified from the original method of Thorn et al. (2004). Fresh bubaline blood in anticoagulant was centrifuged and the plasma supernatant was separated, cryoprecipitated and centrifuged at 0-1°C to concentrate plasma fibrinogen level. Thrombin and calcium were added to the fibrinogen rich plasma to form fibrin polymers on the wound bed. (Thorn et al., 2004). The 350 ml blood was drawn from a buffalo jugular vein, kept in 49 ml of anticoagulant citrate phosphate dextrose adenine solution (CPD) [of citric acid (hydrous) U.S.P. 160 mg, of sodium citrate (hydrous) U.S.P. 1.29 g, of monobasic sodium phosphate (hydrous) U.S.P. 109 mg and of dextrose (anhydrous) 1.42 g and of adenine 13.5 mg], and then centrifuged at 300 g for 20 minutes at 4°C to separate platelets rich plasma from the whole blood (Figure 3) (Thorn et al., 2004).

To prepare the thrombin, 20 g of platelet rich plasma (approximately 20 ml) was used and added with 180 ml of 2.84 mM citric acid. The mixture was cryocentrifuged at 3000 g for 5 minutes (4°C), then the supernatant was discarded and the precipitate was mixed with 1.14 ml of calcium chloride (CaCl<sub>2</sub>) [0.1mol/L]. The mixture was titrated to adjust pH to 7 by adding 0.7ml of 75 mM sodium bicarbonate (NaHCO<sub>3</sub>), then waited for the clot formation 20-30 minute before the liquid thrombin solution was removed from the clot. The thrombin solution was kept at -20°C to maintain the efficiency up to one month (Saxena et al., 2003).

To prepare the fibrinogen rich solution, 100 ml of platelet rich plasma was mixed with 6.4 ml of tranexamic acid (50 mg/ml) and 12 ml of 99% cold ethanol to give a final concentration of approximately 10%, then incubated in ice-water bath (0-1°C) for 20-30 minutes for extracting the fibrinogen, then separated by cryocentrifugation at 3000 g (0-1°C) for 20 minutes; after that the supernatant was discarded. The fibrinogen rich solution was added by of 0.9% sodium chloride (NaCl) 4-5 ml to increase solution volume, finally the fibrinogen solution was thawed at 37 °c, and then kept at -20°C.

The bubaline fibrin glue was formed when mixing the fibrinogen and thrombin solution in 2:1 ratio (volume/volume). From the process, 350 ml of bubaline blood gave approximately 9.5 ml of bubaline fibrin glue (8 ml fibrinogen solution and 1.5 ml of thrombin solution) (Choi et al., 2006). According to a study (Saxena et al., 2003), a 100 cm<sup>2</sup> wound under the surface of skin graft or flap needs 10 ml of the mixed components. Finally, fibrinogen and thrombin solution was verified the sterilization by the results of bacterial culture and antibiotic sensitivity.



**Figure 3.** The bubaline fibrin glue extraction procedure by cryoprecipitation and cryocentrifugation which was modified from the method of Thorn et al. (2004). The bubaline blood was drawn from a buffalo and kept in the anticoagulant after that all of the steps of centrifugation and precipitation were done at low temperature to separate thrombin and fibrinogen from platelet rich plasma.

## **3.2 Bubaline fibrin glue application**

### **3.2.1 Animal**

A healthy female three-breed crossed finishing pig, weighing approximately 30-40 kilograms was used in this experiment. The physical examination, complete blood count (CBC), and blood chemistry (SGPT, ALP, creatinine and blood urea nitrogen) were done before the experiment. Study protocol was reviewed and approved by Chulalongkorn University Animal Care and Use Committee (CU-ACUC) No. 1431082

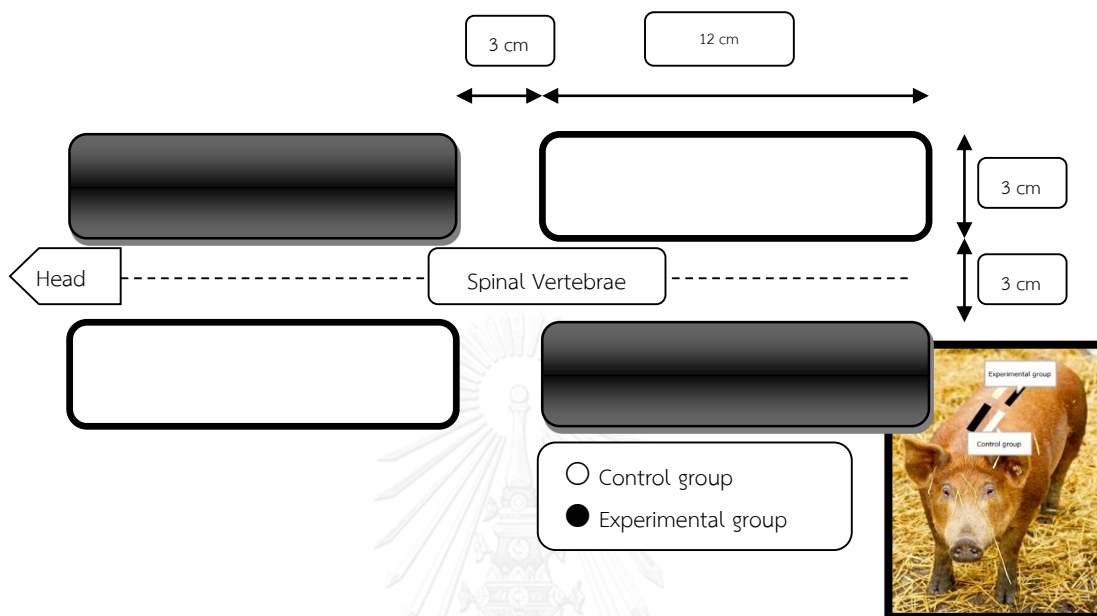
### **3.2.2 Anesthesia and surgical preparation**

The pig was withdrawn the food and water for 8 hours and 3 hours, respectively, before it was premedicated with xylazine HCl (0.5-1.5 mg/kg IM), morphine sulphate (0.5 mg/kg IM) combined with a mixture of tiletamine and zolazepam (Zoletil™, Virbac animal health Inc., France) (1-2 mg of tiletamine/kg IM) (Henrikson et al., 1994). Anesthesia was induced with propofol (3-6 mg/kg IV) and maintained with isoflurane 1-3% in oxygen after intubation. Either cephalic vein or marginal ear vein was used for the crystalloid fluid (10ml/kg/hr) administration during anesthesia. During recovery period, the pig was place on the soft floor and kept warm with warm air blowing machine. For preventing infection, the pig received enrofloxacin (Baytril™, Bayer health care, pharmaceuticals, Germany) 5 mg/kg (SC) preoperative by 7 days post-operatively. To relieve post-operative pain, morphine sulphate 0.5mg/kg was given give IM, twice a day for 7 days post operation and tramadol HCl 4 mg/kg IM, twice daily until the end of the experiment (Swindle, 2007). The pig's hairs were clipped by hair clipper using a 40S (0.25mm) blade, then the skin was scrubbed alcohol for three times with 1% chlorhexidine solution, 10% povidone iodine and 70% isopropyl before surgery.

### **3.2.3 Surgical procedures**

The skin graft preparation, was consisted of two operation steps. The first operation was done for creating the granulation wound. According to a wound reepithelization rate study, in the pig wound model is 0.4 mm/day (Laplante et al.,

2001). Two parallel 3 x 12 cm square areas with full skin depth wounds were created at the dorsal loin on both sides. The space between each wound was 3 cm. Entirely, there were four wounds on a pig (Figure 4). The second operation was skin grafting.

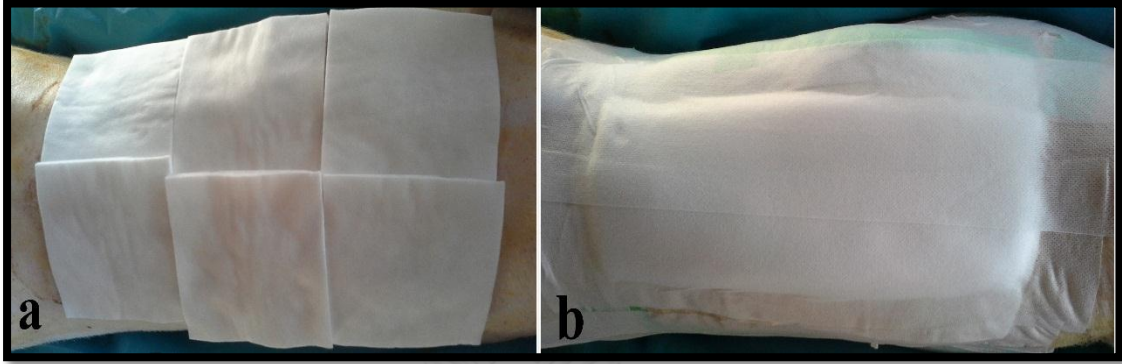


**Figure 4.** Size and location of the control and the experimental wounds on the loin area of a pig. There were two of 3x12 cm<sup>2</sup> wounds on each side of the spinal vertebrae.

The wounds were dressed by a layer of soft, hydrophilic polyurethane foam bonded to a semipermeable polyurethane film (Allevyn gentle™, Smith & Nephew healthcare limited, United Kingdom) as a contact and an intermediate layer; covered with the polyethylene terephthalate, which was bonded with an absorbent layer consisting of a mixture of cotton and polyacrylonitrile fibers covered by a layer of an aperture non-woven cellulose fabric (Melolin™, Smith & Nephew Healthcare Limited, United Kingdom) as a secondary layer; then cover with a highly conformable non-woven retention bandage coated with a hypoallergenic acrylic adhesive (Primafix™, Smith & Nephew Healthcare Limited, United Kingdom) finally, water-proofed with a water resistant, transparent, adhesive film (Opsite™, Smith & Nephew healthcare limited, United Kingdom), an outer protective layer (Figure 5). The wounds were examined on the 5<sup>th</sup> post-operative day and swabbed for bacterial culture and

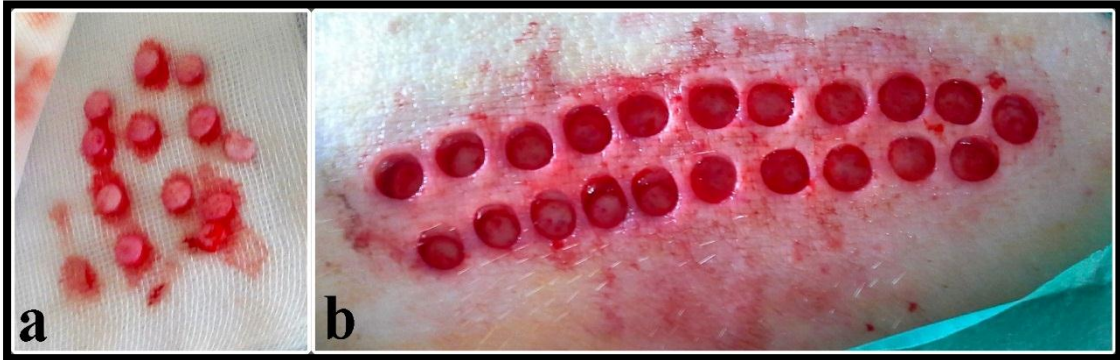

antibiotic sensitivity. The pig's health was re-evaluated by physical examination and blood analysis (complete blood counts and blood chemistry) afterwards. The wounds were left for the granulation tissue to naturally develop.



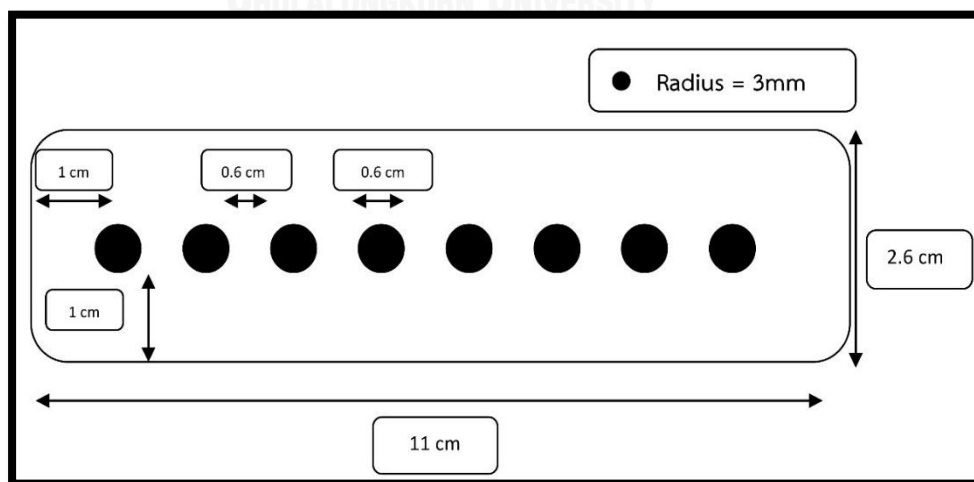
**Figure 5.** Wound dressing on the pig. The wounds were covered by the polyethylene terephthalate, which was bonded with an absorbent layer consisting of a mixture of cotton and polyacrylonitrile fibers covered by a layer of an aperture non-woven cellulose fabric to protect the primary layer from damage **(a)**; wounds were covered with a highly conformable non-woven retention bandage coated with a hypoallergenic acrylic adhesive **(b)**; water-proofed by a water resistant, transparent, adhesive film.

Five days later, the second operation was done for pinch and punch skin grafting. The pig was sedated and anesthetized according to the anesthesia protocol, then the dorsal neck area was prepared for the donor graft, after that the wounds were cleaned regarding to the aseptic protocol. Full thickness graft pieces were harvested by using a sterile 6 mm disposable dermal biopsy punch key. The graft pieces were taken without subcutaneous tissue (Figure 6). After graft pieces were harvested, the donor sites were sutured with the 2-0 nylon in the simple interrupted suture pattern.

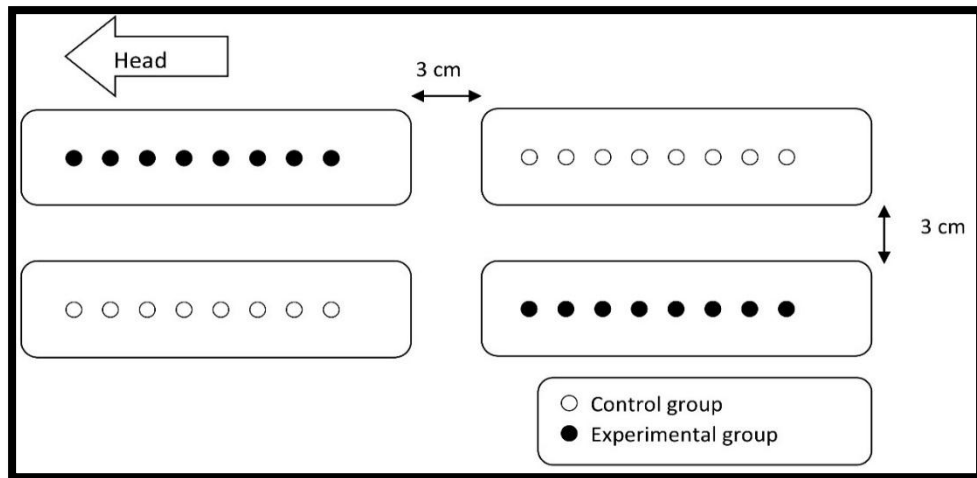


**Figure 6.** 6 mm skin graft pieces which were punched by a sterile 6 mm disposable dermal biopsy punch key (a) and the donor site at the dorsal neck area after the skin grafts were taken away (b).

The healthy granulation beds were cleaned by removing the debris, necrotic tissues and chronic or exuberant granulation tissues, and prepared for eight grafting units with 0.6 cm in diameter each (Figure 7). There were 8 grafting units per wound and a total of 32 grafting units (Figure 8). The left cranial and the right caudal grafts were the control groups not receiving the bubaline fibrin glue, and the right cranial and the left caudal graft the experimental group receiving the bubaline fibrin glue. To summarize, there were 16 pairs of grafting units, which were comparable between the control and the experimental groups.

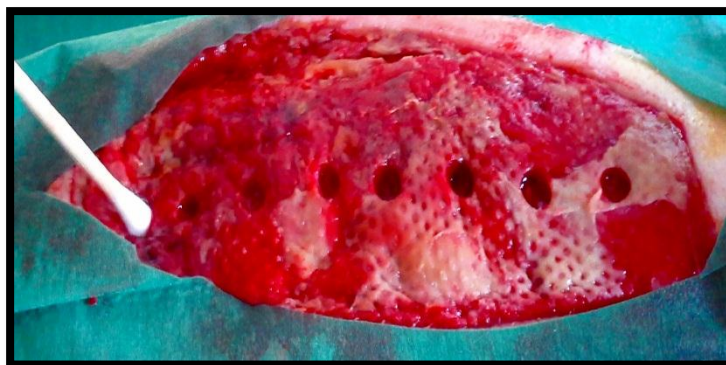


**Figure 7.** Eight 0.6 cm grafts and gap width between the grafts with 3mm of radius, 0.6 cm of gap width, and 1 cm away from the wound edges.

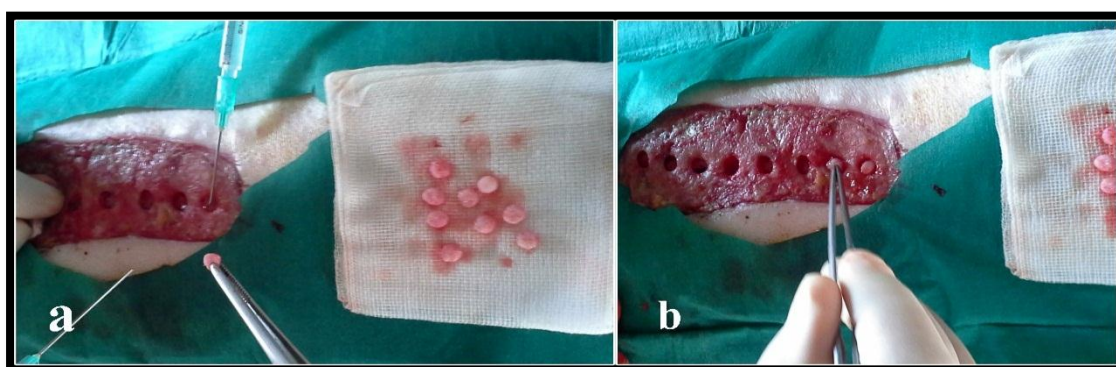


**Figure 8.** The total of 36 grafting units were separated into 16 grafting units of the control group and 16 grafting units of the experimental group. The left cranial and the right caudal graft were the control groups, and the right cranial and the left caudal graft were the experimental group.

The small round pits were made in the granulation tissue parallel to the wound's margin by using a sterile 6 mm disposable dermal biopsy punch key. The pit depth is about 2-4 mm and the length between the pits is 6 mm, then a small sharp tip scissors was used for removing the core of the granulation plug (Figure 9). Direct digital pressure was used to stop hemorrhage and a sterile cotton tip applicator was placed in the pit for 4-5 minutes. The experimental group's pits were instilled with 0.1-0.2 ml of the bubaline fibrin glue before a graft piece was placed. The mixture was thawed immediately before used and instilled in a wound by using 21 G sterile needles. Firstly, 2 drops of bubaline fibrinogen, then a drop of thrombin, after that each piece of the graft was held in the pit by a forceps for 1-2 minutes (Figure10).



**Figure 9.** Eight 6 mm diameter of pits with 6 mm apart were prepared for eight skin grafts.



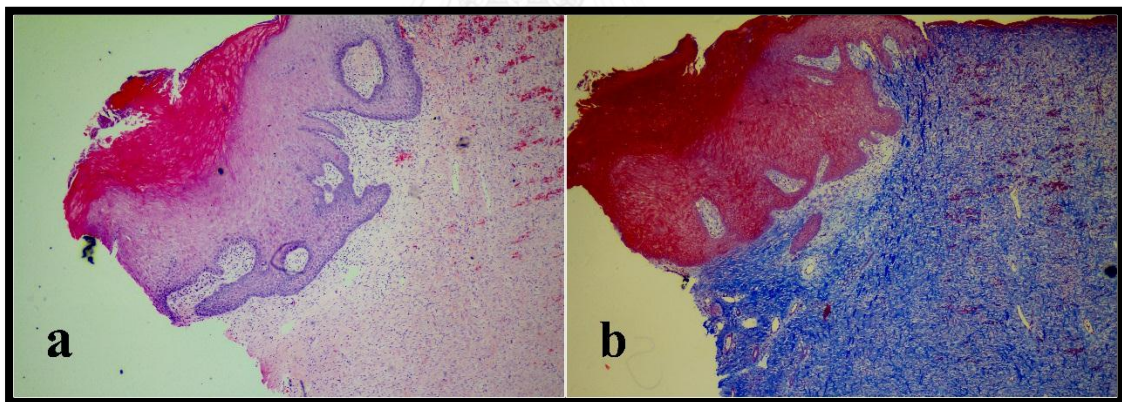
**Figure 10.** The application of 0.1-0.2 ml of bubaline fibrin glue in the pits of the experimental group (a), then a skin graft was placed in the pit and held by a forceps for 1-2 minutes (b).

The wounds were dressed by applying the amorphous hydrogel gel (Intrasite™ hydrogel wound Filler, Smith & Nephew Healthcare Limited, United Kingdom) on the graft; covered with the polyethylene terephthalate, which was bonded with an absorbent layer consisting of a mixture of cotton and polyacrylonitrile fibers covered by a layer of an aperture non-woven cellulose fabric; then adhered by a highly conformable non-woven retention bandage coated with a hypoallergenic acrylic adhesive; finally, protected by using a water resistant, transparent, adhesive film and conforming open mesh gauze as a tertiary layer. The pig was sedated on the 3<sup>rd</sup>, 7<sup>th</sup> and 14<sup>th</sup> days after the second-operation for wound dressing and evaluation. The pig

was fed with pig diet (CP-953, CPF public company limited, Thailand) and tap water ad libitum during the experimental period.

### 3.3 Variable evaluation

There were two variables to be evaluated in this experiment. The first variable was the remaining of the survival graft pieces in the control group (without bubaline fibrin glue) and the experimental group (with bubaline fibrin glue). The second variable was the histological finding of the skin grafting that were investigated in pair at the 3<sup>rd</sup>, 7<sup>th</sup> and 14<sup>th</sup> post-operative day by using a sterile 6 mm disposable dermal biopsy key to punch on the right half side of a pair of the graft piece, which chosen randomly. The samples were fixed in 10 % neutral buffered formalin, then routine histopathology was performed (Figure 11a) and Masson's trichrome was stained for collagen fibers (Figure 11b). Finally the samples were examined using a light microscope at 40x magnification.



**Figure 11.** Hematoxylin and eosin (H&E) staining for routine histopathology observation **(a)** and Masson's trichrome staining for highlight collagen fibers **(b)** (4x magnification).

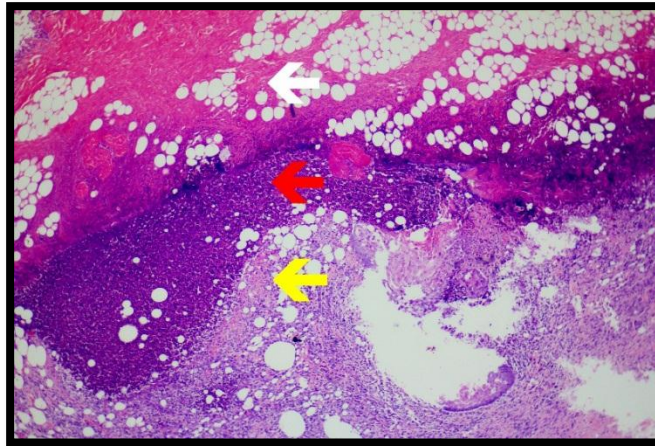
The histological observation was designed to grade skin graft rejection and healing. Skin graft rejection grading followed Bejarano et al. (2004) who established a grading system for rejection of full-thickness skin transplant (Table 1) (Bejarano et al., 2004).



**Table 1.** Grading system for rejection of full-thickness skin transplant which was modified from the system of Bejarano et al. (2004) by using histopathology features including perivascular infiltration, epidermal transformation and stromal changing.

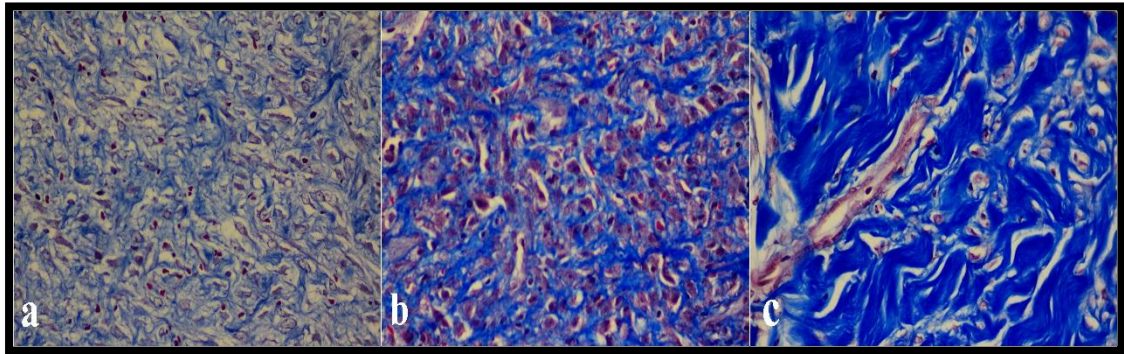
Grade	Criteria
<b>Grade 0</b> (no rejection)	Normal skin without perivascular infiltrates
<b>Grade I</b> (indeterminate rejection)	1-10% of vessels have infiltrated of small lymphocytes; no eosinophil, large lymphocytes, spongiosis, epidermal or stromal inflammation.
<b>Grade II</b> (mild rejection)	11-50% of vessels have been infiltrated of small lymphocytes; variable eosinophils or mild spongiosis and no epidermal or stromal infiltrates or large lymphocytes.
<b>Grade III</b> (moderate rejection)	More than 51% of vessels have been infiltrated of small lymphocytes; variable epidermal and stromal inflammation, at most mild spongiosis, possible endothelial plumping, eosinophils and large lymphocytes.
<b>Grade IV</b> (severe rejection)	More than 51% of vessels have been infiltrated of small lymphocytes, also dyskeratosis; The epidermis has heavier lymphocytic infiltrates and moderate to severe spongiosis; stroma shows infiltrates extending into the base of the epidermis; also endothelial plumping, eosinophils and large lymphocytes; separation of epidermis from dermis.

Healing of the skin graft was interpreted by angiogenesis, fibroblastic proliferation, intensity of inflammation and intensity of scarring. The angiogenesis was interpreted by interconnected of capillary sprouts and formation of new microvessels which infiltrated at surrounding tissues adjacent to the junction between the graft and the bed area. It was quantified by averaging of 20 areas just below the necrotic area by using 40x magnification (Figure 12) (Vajkoczy et al., 1995).



**Figure 12.** Epidermis of the graft piece (the white arrow) with the necrotic area (red arrow) and the granulation area (yellow arrow) that was selected for the quantification of vessels, cells and fibers (4x magnification, H&E stain).

The fibroblastic proliferation was quantified by counting a number of fibroblasts which infiltrated at surrounding tissues adjacent to the graft-bed area. It was quantified by averaging of 20 areas at 40x magnification in each group (Werner et al., 2007). The intensity of the inflammation was graded by counting predominant inflammatory cell types (Pinna et al., 2011). After that, the inflammation was graded as follows: Grade 0: no inflammatory cells, Grade I: one to 10 cells were observed, Grade II: 11 to 20 cells were observed, and Grade III: over 20 cells were observed. Finally, the intensity of scarring was analyzed by modification of Pinna's criteria which was approximated by the color intensity and arrangement of the collagen infiltrated in the surrounding tissues adjacent to the graft-bed area, then assessed qualitatively by averaging of 12 areas by using 40x magnification in each group (Pinna et al., 2011). The grading was described as Grade 0: No collagen fibers, Grade I: small amount of collagen fibers was seen by coarse arrangement and pale blue stain, Grade II: short to medium continuous arrangement of collagen bands around the graft with blue stain, and Grade III: long collagen fibers around the graft with dark blue stain (Figure 13).



Grade I (mild)

Grade II (moderate)

Grade III (intense)

**Figure 13.** Scarring grading using color intensity and arrangement of the collagen in the graft-bed area; Grade I (unsystematic arrangement with pale blue staining of the collagen networks) **(a)**, Grade II (moderate connection of the collagen bundles with blue staining) **(b)**, and Grade III (continuously and regularly arrangement of the collagen fibers with dark blue staining) **(c)** (40x magnification, Masson's trichrome stain).

For each variable on the 3<sup>rd</sup>, 7<sup>th</sup> and 14<sup>th</sup> post-operative day, the remained survival graft pieces and histological findings of both control and bubaline fibrin glue groups were calculated for a central tendency (mean), standard variation (SD) then, compared between the two groups by inferential statistically differences using Wilcoxon signed rank test ( $p < 0.05$ ) by using SPSS for Windows program (version 13.0, IBM, USA).



## CHAPTER IV

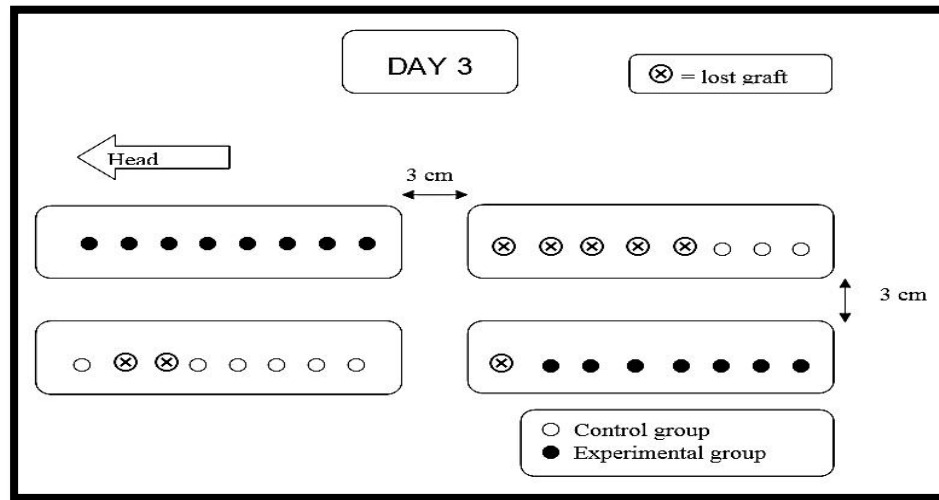
### RESULTS

#### 4.1 Bubaline fibrin glue and bacterial culture

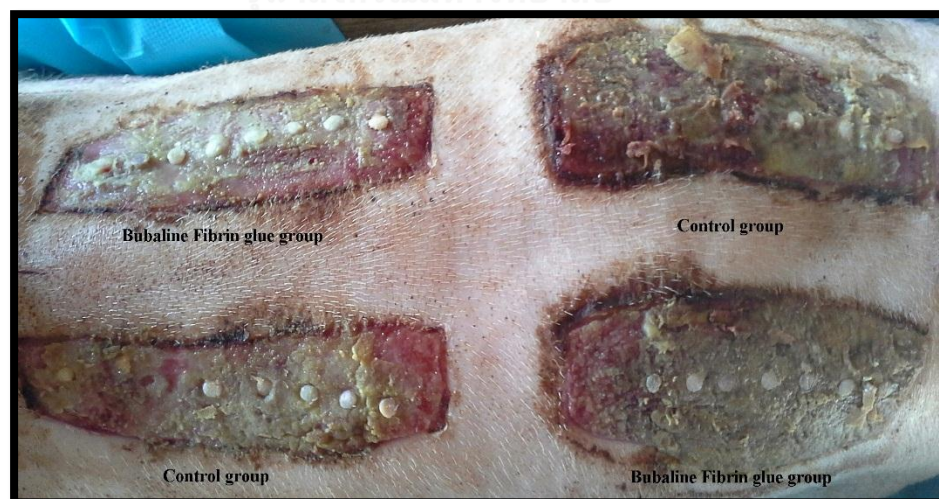The concentration of fibrinogen from fresh bubaline blood was 464 mg/dl. The concentration of the fibrinogen rich in the extract from the cryoprecipitate and centrifuged method was 1620 mg/dl. The bacterial culture of the extract found was no bacterial growth. While the result of bacterial culture from the wounds found numerous *Klebsiella pneumoniae* and *Escherichia coli*, which were resistant to enrofloxacin.

#### 4.2 The remaining of the survival graft pieces

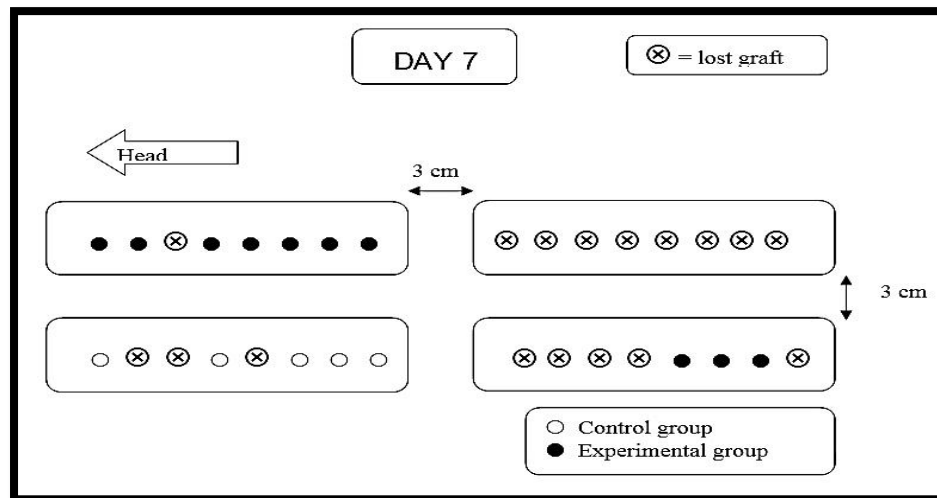
After the surgery, the remaining of skin graft pieces can be visualized only on the 3<sup>rd</sup> and 7<sup>th</sup> post-operative days (Figure 14, 15, 16 and 17) because at the 14<sup>th</sup> post-operative day most of the skin graft pieces were covered by the abundant of granulation tissue (Figure 18). The patterns of the result of the remaining grafts were described as positive difference pair, the skin graft remained in the bubaline fibrin glue group disappeared from the control group, negative difference pair, the skin graft in the control group disappeared from the bubaline fibrin glue group and no difference, either the grafts remained or disappeared in both groups.



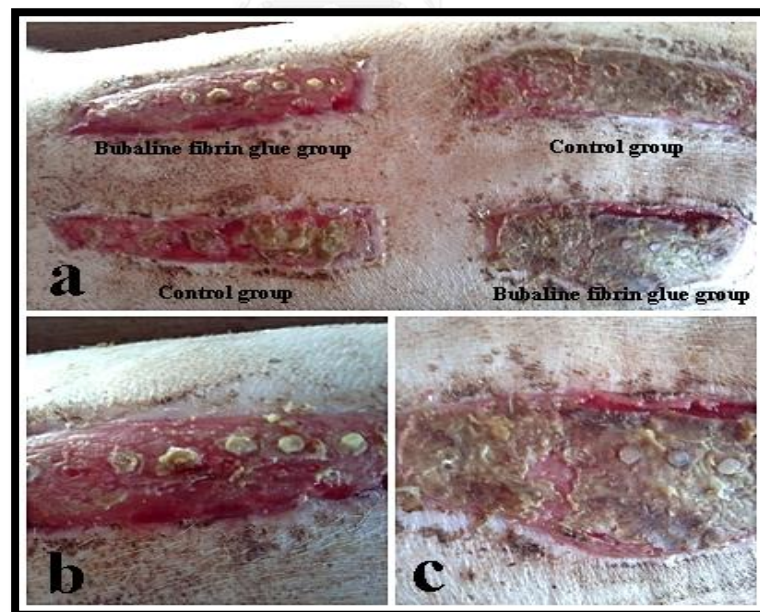
**Figure 14.** The remaining grafts on the 3<sup>rd</sup> post-operative day in comparison between the experimental group and the control group. There were six positive difference pairs (The skin graft remained in the bubaline fibrin glue group remained but disappeared from the control group) and no negative difference pair (The skin graft remained in the control group remained but disappeared from the bubaline fibrin glue group)



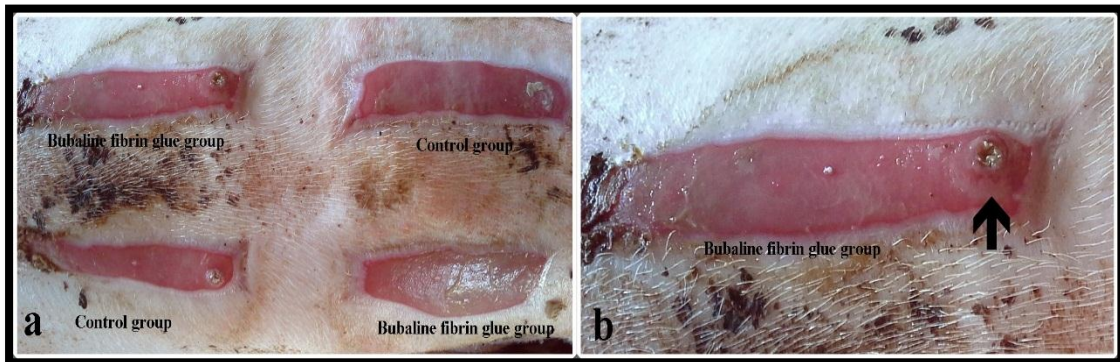
**Figure 15.** The remaining grafts on the 3<sup>rd</sup> post-operative day were partially covered by debris and dry exudate.



**Figure 16.** The remaining grafts on the 7<sup>th</sup> post-operative day in comparison between the experimental group and the control group. There were five positive difference pairs (The skin graft remained in the bubaline fibrin glue group remained but disappeared from the control group) and no negative difference pair (The skin graft remained in the control group remained but disappeared from the bubaline fibrin glue group)



**Figure 17.** The remaining grafts on the 7<sup>th</sup> post-operative day were almost covered with dry exudate at the caudal part (a). However, the survived grafts can be visualized in the enlarged picture of the bubaline fibrin glue group at the right cranial wound (b) and the left caudal wound (c).



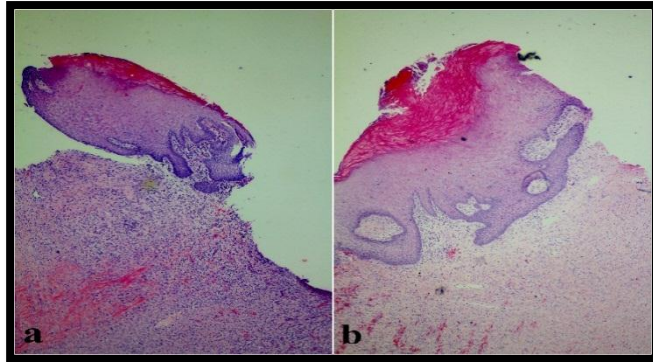
**Figure 18.** The wounds on the 14<sup>th</sup> post-operative day. All of the skin grafts were covered by abundant granulation tissue (a); the enlarged picture of the left cranial wound of the experimental group showed trace of the wound that was not healed after sampling for histological examination (black arrow) (b).

Graft loss and remain were in pair between the left and the right sides. The bubaline fibrin glue group had significantly more survived graft pieces than the control group on the 3<sup>rd</sup> post-operative day ( $p < 0.05$ ) and on the 7<sup>th</sup> post-operative day ( $p < 0.05$ ) by using the Wilcoxon signed rank test (Table 2).

However, to collect the samples for the histological study on the 14<sup>th</sup> post-operative day was done by calculated the distance between grafts and wound edges. The evidence was the histological section showed the epithelial layer of the graft adhered to the bed (Figure 19).

**Table 2.** The results of remaining grafts in the bubaline fibrin glue group and the control group represented as remained graft and Wilcoxon Signed Rank Test.

		Remained grafts		Wilcoxon Signed Rank Test			
		Pieces	%	Positive rank	Negative rank	Ties	p-value
<b>Day</b>	Fibrin glue	15	93.75				
<b>3</b>	Control	9	56.25	6	0	10	0.031
<b>Day</b>	Fibrin glue	10	62.5				
<b>7</b>	Control	5	31.25	5	0	11	0.025



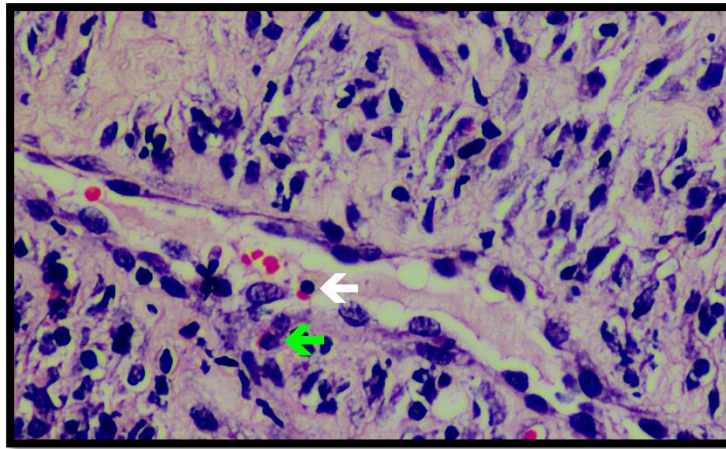
**Figure 19.** The histological tissues were biopsied on the 14<sup>th</sup> post-operative day from the control group **(a)** and the bubaline fibrin glue group **(b)**. In both pictures, the epidermal layer of the graft was adhered to granulation tissue of the bed (4x magnification, H&E stain).

### 4.3 Histology

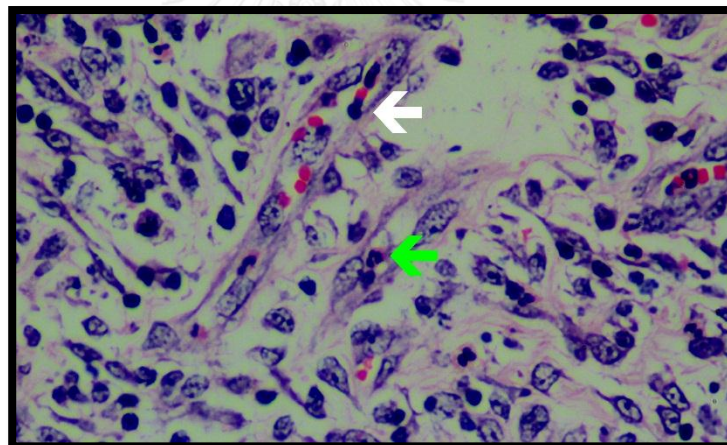
#### 4.3.1 Skin graft rejection

The histological grading for skin graft rejection followed Bejarano et al. (2004) criteria indicated no (grade 0) or indeterminate (grade I) rejection of both control and bubaline fibrin glue groups on the 3<sup>rd</sup>, 7<sup>th</sup> and 14<sup>th</sup> post-operative days, There were only 0-2% of vessels have been infiltrated with small lymphocytes and 2-14 eosinophils per 40x magnification screen but spongiosis and basal vacuolar changing were not found (Figure 20 and 21). No statistically significant difference ( $p>0.05$ ) by the Wilcoxon signed rank test was observed.





**Figure 20.** Histological finding on the 3<sup>rd</sup> post-operative day of the control group represents a vessel was infiltrated by a small lymphocyte (white arrow) and an eosinophil (green arrow) indicating indeterminate rejection (grade I) (40x magnification, H&E stain).



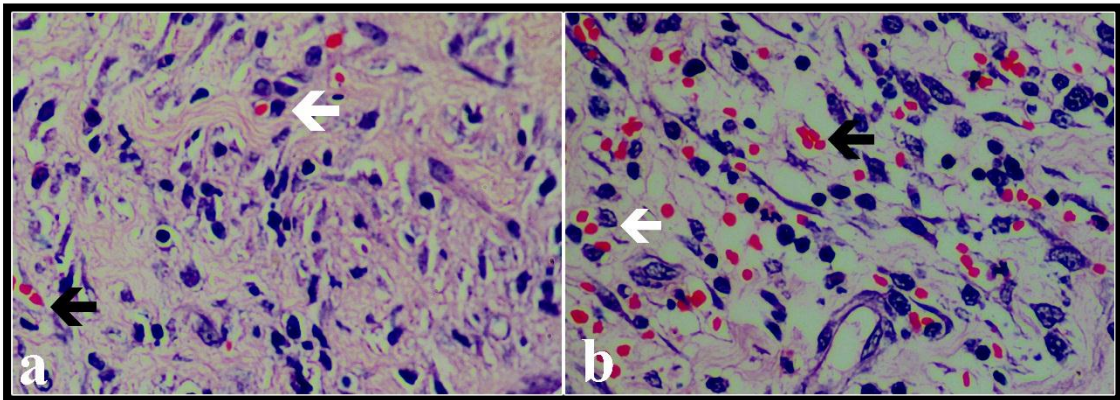
**Figure 21.** Histological finding of the 3<sup>rd</sup> post-operative day of the bubaline fibrin glue group represents a vessel was infiltrated by a small lymphocyte (white arrow) and an eosinophil (green arrow) was seen that indicated indeterminate rejection (grade I) (40x magnification, H&E stain).

#### 4.3.2 Skin graft healing

The healing of skin graft in both groups was compared by angiogenesis, fibroblastic proliferation, intensity of inflammation and intensity of scarring.

#### 4.3.2.1. The angiogenesis

The angiogenesis was evaluated by counting the number of new microvessels in 20 areas of H&E stain by using 40x magnification (Figure 22).

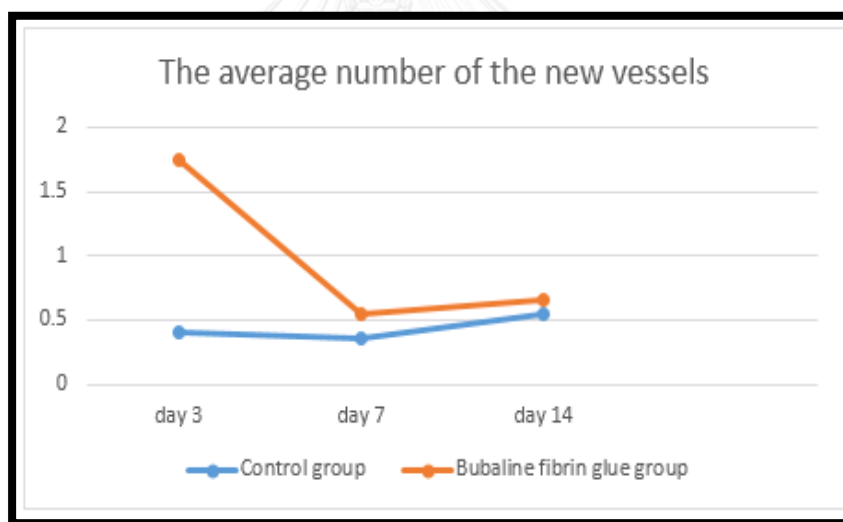


**Figure 22.** Angiogenesis of the control group (a) and the bubaline fibrin glue group (b) on the 3<sup>rd</sup> post-operative day presented new microvessels (white arrow) with oval endothelial cells and old microvessels with spindle endothelial cells (black arrow) (40x magnification, H&E stain).

It was found that there was a statistically significant difference of the number of new microvessels between the control and the bubaline fibrin glue groups on the 3<sup>rd</sup> post-operative day ( $p < 0.05$ ) but there were no statistically significant differences of the number of new microvessels between the control and the bubaline fibrin glue group on the 7<sup>th</sup> and the 14<sup>th</sup> post-operative days ( $p > 0.05$ ) by using pair-t test. The average number of new microvessels was high in the bubaline fibrin glue group on the 3<sup>rd</sup> post-operative day, then rapidly decreased to the comparable number of the control group on the 7<sup>th</sup> and the 14<sup>th</sup> post-operative days (Table 3) (Figure 23).

**Table 3.** The number of new microvessels were presented as mean, standard deviation (SD) and p-value (paired-t test). There was statistically significant difference between the control group and the bubaline fibrin glue group on the 3<sup>rd</sup> post-operative day ( $p < 0.05$ )

Histological criteria		3 <sup>rd</sup> post-operative day		7 <sup>th</sup> post-operative day		14 <sup>th</sup> post-operative day	
		Control	Fibrin glue	Control	Fibrin glue	Control	Fibrin glue
The number of new microvessels (Pair-T test)	Mean	0.40	1.75	0.35	0.55	0.55	0.65
	SD	0.598	1.517	0.587	0.759	0.826	0.745
	p-value	0.003		0.330		0.733	

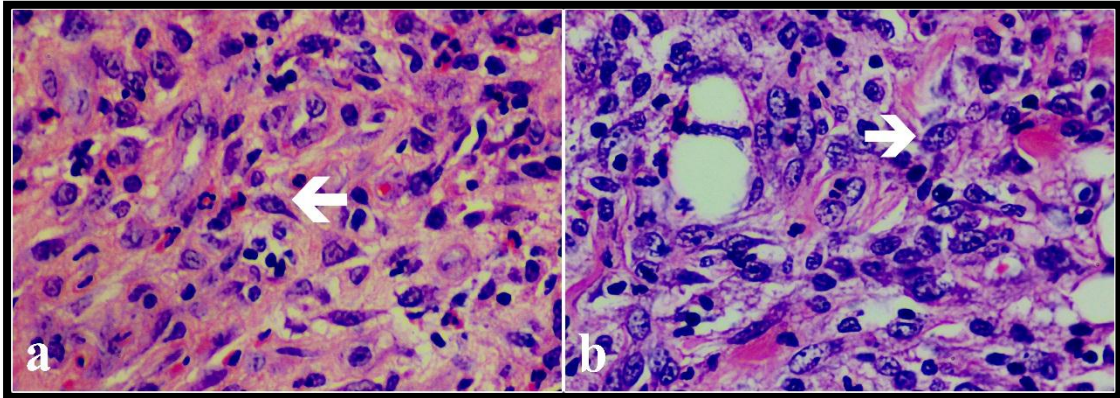


**Figure 23.** The average number of new microvessels on the 3<sup>rd</sup>, 7<sup>th</sup> and 14<sup>th</sup> post-operative days in comparison between the control and the bubaline fibrin glue groups. The average number of new microvessels on the 3<sup>rd</sup> post-operative day of the bubaline fibrin glue group was noticeably more than that of the control group, but rapidly decreased to the comparable levels of the control group at the 7<sup>th</sup> and 14<sup>th</sup> post-operative days.



#### 4.3.2.2. The number of fibroblasts

The number of fibroblasts were counted in 20 areas of H&E stain just below the necrotic area using 40x magnification (Figure 24).

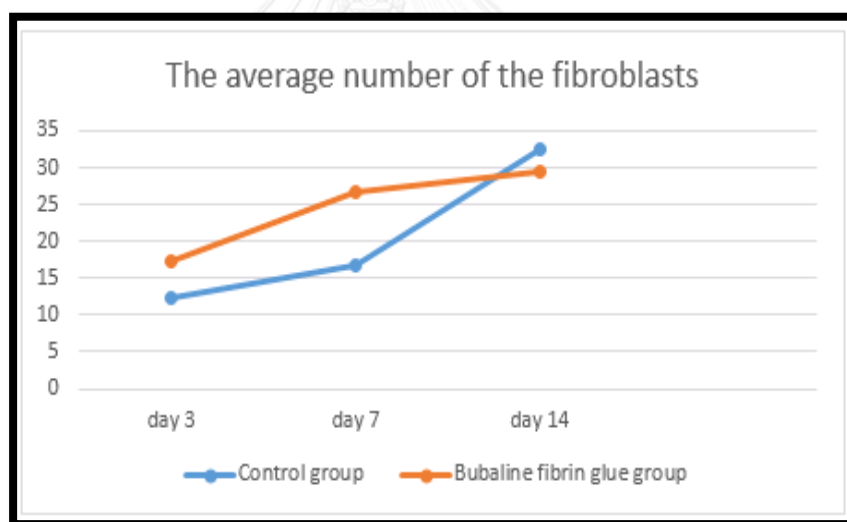


**Figure 24.** Fibroblasts surrounded by extracellular matrix (white arrows) in the control group (a) and the bubaline fibrin glue group (b) on the 7<sup>th</sup> post-operative day (40x magnification, H&E stain).

There were no statistically significant differences of the number of fibroblasts between the control and the bubaline fibrin glue groups on the 3<sup>rd</sup>, 7<sup>th</sup> and 14<sup>th</sup> post-operative days using pair-t test. The average number of fibroblasts was steadily increased in both groups on the 3<sup>rd</sup>, 7<sup>th</sup> and 14<sup>th</sup> post-operative days but the increase in the bubaline fibrin glue group was slightly more than control group on the 3<sup>rd</sup> and 7<sup>th</sup> post-operative days (Table 4) (Figure 25).

**Table 4.** The number of fibroblasts were presented as mean, standard deviation (SD) and p-value (paired-t test). There were no statistically significant differences between the control group and the bubaline fibrin glue group on the 3<sup>rd</sup>, 7<sup>th</sup> and 14<sup>th</sup> post-operative days ( $p>0.05$ )

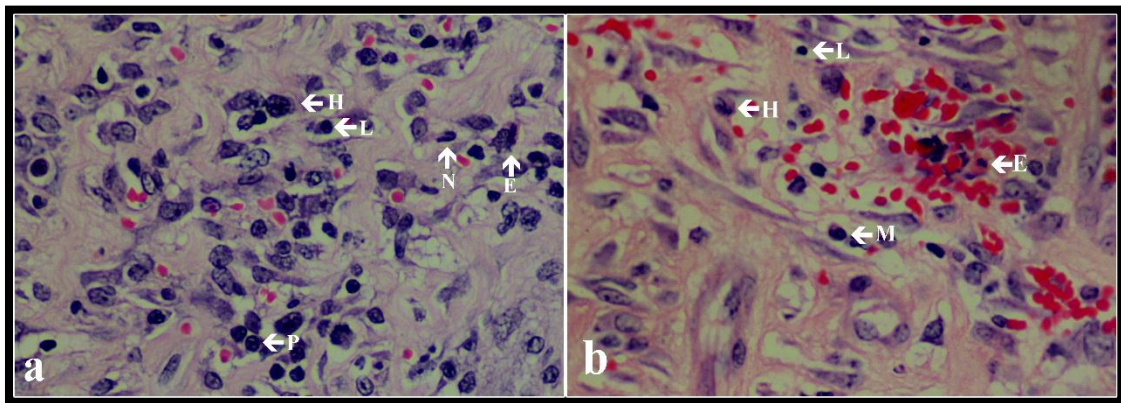
Histological criteria		3 <sup>rd</sup> post-operative day		7 <sup>th</sup> post-operative day		14 <sup>th</sup> post-operative day	
		Control	Fibrin glue	Control	Fibrin glue	Control	Fibrin glue
The number of fibroblasts (Pair-T test)	Mean	12.30	17.40	16.85	26.70	32.50	29.55
	SD	10.398	14.489	16.468	19.709	19.343	15.264
	p-value	0.261		0.130		0.536	



**Figure 25.** The average number of fibroblasts on the 3<sup>rd</sup>, 7<sup>th</sup> and 14<sup>th</sup> post-operative days in comparison between the control and the bubaline fibrin glue groups. The average number of fibroblasts of the bubaline fibrin glue group was slightly more than that of the control group on the 3<sup>rd</sup> and 7<sup>th</sup> post-operative days, then was comparable to the level of the control group on the 14<sup>th</sup> post-operative day.

#### 4.3.2.3. The intensity of the inflammation

The intensity of the inflammation was evaluated and graded by counting the predominant inflammatory cells in 20 areas of H&E stain just below the necrotic area (40x magnification) (Figure 26).

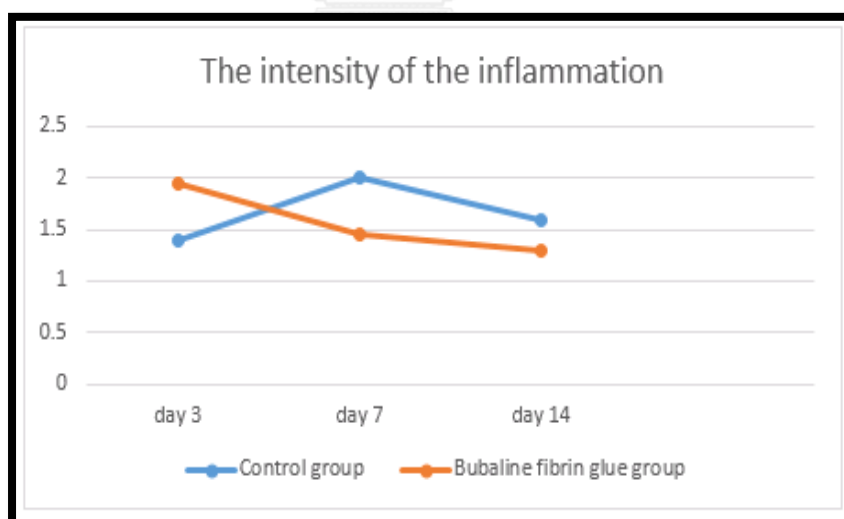


**Figure 26.** The predominant inflammatory cells including neutrophil (N), mast cell (M), lymphocyte (L), plasma cell (P), histiocyte (H), and eosinophil (E) on the 3<sup>rd</sup> (a) and the 7<sup>th</sup> post-operative days (b) in the bubaline fibrin glue group (40x magnification, H&E stain).

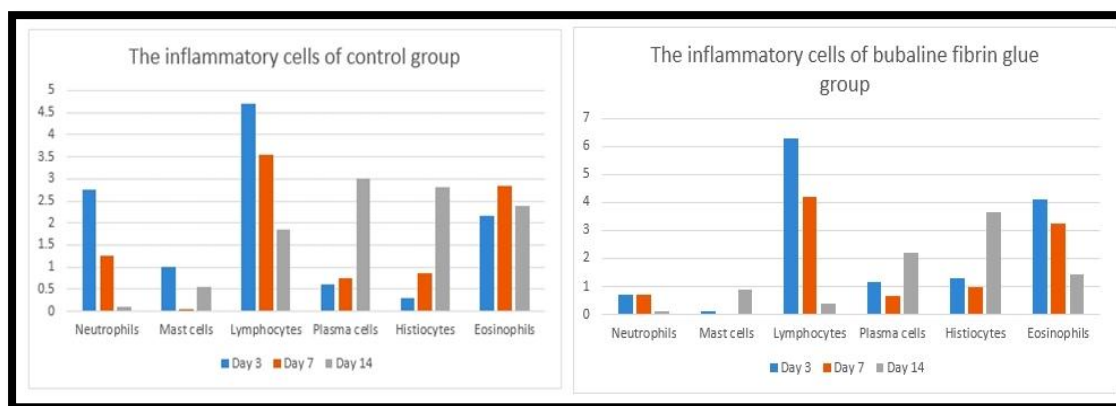
There was statistically significant difference of inflammatory grades between the control and the bubaline fibrin glue groups on the 7<sup>th</sup> post-operative day ( $p < 0.05$ ) but not on the 3<sup>rd</sup> and 14<sup>th</sup> post-operative days ( $p > 0.05$ ), using the Wilcoxon Signed Rank Test. The intensity of the inflammation level increased on the 7<sup>th</sup> post-operative day in the control group in contrast to the bubaline fibrin glue group of which the intensity of the inflammation continuously decreased (Table 5) (Figure 27). Varied types of inflammatory cell types were presented in the figure 28. The number of neutrophils in the control group was more than that of the bubaline fibrin glue group on the 3<sup>rd</sup> and 7<sup>th</sup> post-operative days. While the higher levels of plasma cells and eosinophils were seen on the 14<sup>th</sup> post-operative day.

**Table 5.** The intensity of inflammation was presented as mean, negative rank, positive rank, ties and p-value (Wilcoxon Signed Ranks Test). There was statistically significant difference ( $p < 0.05$ ) between the control group and the bubaline fibrin glue group on the 7<sup>th</sup> post-operative day.

Histology criteria		3 <sup>rd</sup> post-operative day		7 <sup>th</sup> post-operative day		14 <sup>th</sup> post-operative day	
		Control	Fibrin glue	Control	Fibrin glue	Control	Fibrin glue
The intensity of inflammation (Wilcoxon Signed Ranks Test)	Mean	1.40	1.95	2.00	1.45	1.60	1.30
	Negative rank <sup>a</sup>		4	9		10	
	Positive rank <sup>b</sup>		12	3		4	
	Ties <sup>c</sup>		4	8		6	
	p-value		0.052	0.029		0.186	



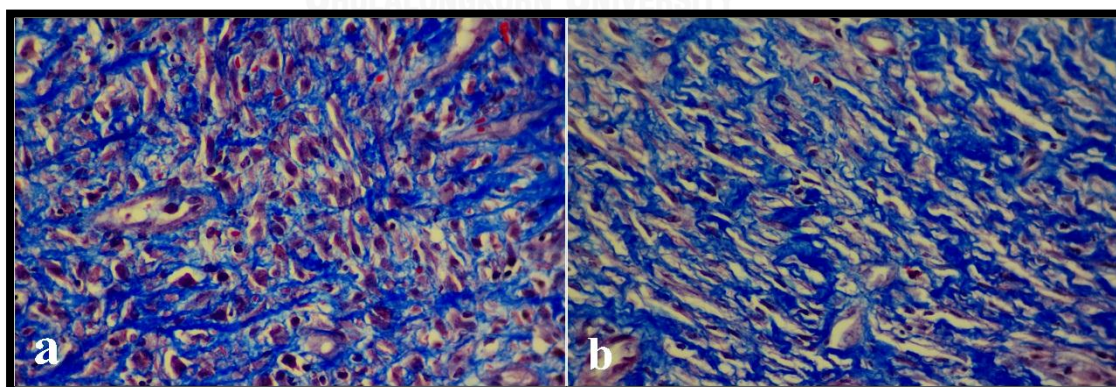
**Figure 27.** The intensity of the inflammation on the 3<sup>rd</sup>, 7<sup>th</sup> and 14<sup>th</sup> post-operative days in comparison between the control and the bubaline fibrin glue groups. The intensity of the inflammation of the bubaline fibrin glue group was dropped, opposition to the intensity of the inflammation of the control group, on the 3<sup>rd</sup> post-operative day, and continued decreasing until the 14<sup>th</sup> post-operative day.



**Figure 28.** The number of each type of the inflammatory cells types on the 3<sup>rd</sup>, 7<sup>th</sup> and 14<sup>th</sup> post-operative days in comparison between the control and the bubaline fibrin glue groups. The number of neutrophils of the control group was more than that of the bubaline fibrin glue group on the 3<sup>rd</sup> post-operative day and the number of plasma cells and eosinophils of the control group were more than those of the bubaline fibrin glue group on the 14<sup>th</sup> post-operative day.

#### 4.3.2.4. The intensity of scarring

The intensity of scarring was evaluated by grading the color intensity and arrangement of collagen fibers in 12 areas stained by Masson's trichrome just below the necrotic area using 40x magnification (Figure 29).



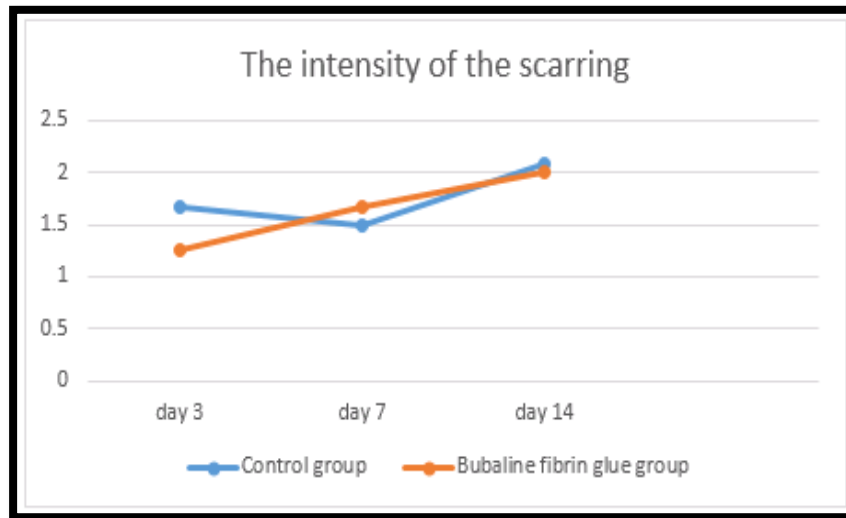
**Figure 29.** The intensity of scarring of the control (a) and the bubaline fibrin glue groups (b) on the 7<sup>th</sup> post-operative day which were compared by color intensity and arrangement of collagen fibers (40x, Masson's trichrome stain)

There were no statistically significant differences ( $p>0.05$ ) of the number of inflammatory grades between the control and the bubaline fibrin glue groups on the 3<sup>rd</sup>, 7<sup>th</sup> and 14<sup>th</sup> post-operative days by using the Wilcoxon Signed Rank Test. However, the intensity of the scarring level continuously increased in the bubaline fibrin glue group but decreased in the control group on the 7<sup>th</sup> post-operative day (Table 6) (Figure 30).

**Table 6.** The intensity of inflammation was presented as mean, negative rank, positive rank, ties, and p-value (Wilcoxon Signed Ranks Test). There were no statistically significant difference ( $p>0.05$ ) between the control group and the bubaline fibrin glue group on the 3<sup>rd</sup>, 7<sup>th</sup> and 14<sup>th</sup> post-operative days.

Histology criteria		3 <sup>rd</sup> post-operative day		7 <sup>th</sup> post-operative day		14 <sup>th</sup> post-operative day	
		Control	Fibrin glue	Control	Fibrin glue	Control	Fibrin glue
The intensity of scarring (Wilcoxon Signed Ranks Test)	Mean	1.67	1.25	1.50	1.67	2.08	2.00
	Negative rank <sup>a</sup>		1		6		3
	Positive rank <sup>b</sup>		2		2		4
	Ties <sup>c</sup>		9		4		5
	p-value		0.564		0.157		0.705





**Figure 30.** The intensity of the scarring on the 3<sup>rd</sup>, 7<sup>th</sup> and 14<sup>th</sup> post-operative days in comparison between the control and the bubaline fibrin glue groups. The intensity of the scarring of the bubaline fibrin glue group was steadily increased, while the intensity of the control group slightly dropped on the 7<sup>th</sup> post-operative day.

## CHAPTER IV

### CONCLUSION, DISCUSSION, COMMENT

#### Conclusion

In conclusion, from the past till now, fibrin glue is one of the best options for increase success of skin grafting surgery, especially in this study that represents the achievement of using bubaline fibrin glue in pinch and punch skin grafting in porcine. The bubaline fibrin glue which was extracted from bubaline blood by using cryocentrifugation and cryoprecipitation achieve in high concentration of fibrinogen that relate to graft survival and promote clinical outcomes of skin grafting. In this study, application of bubaline fibrin glue to pinch and punch skin graft may reduce hematoma and/or seroma, movement of graft and bacterial activity result in graft survived. Other than an increasing of graft survival chance, bubaline fibrin glue can promote the angiogenesis, which play the significant process of graft existence. On the other hand, bubaline fibrin glue may support neither an increasing of fibroblasts, collagen fibers nor reducing inflammatory intensity, but bubaline fibrin glue plays an advantage in supporting of skin graft healing, especially in the early phases of engraftment, which are consist of adhesion phase, plasmatic imbibition phase and inosculation phase. Despite, the bubaline fibrin glue may not distinctly represent the efficacy on skin graft healing, the remaining of skin grafts and the high quantity of neovascularization indicated that the bubaline fibrin glue gave the advantage survival opportunity to pinch and punch skin grafting.

#### Discussion

Naturally, fibrinogen from plasma accumulated on the wound surface or between grafts and beds in the healing process and become fibrin polymer or scaffold by activation of the thrombin. The fibrin polymers are important to the collagen producing fibroblast, adhesion of graft and bed during adherence, plasmatic imbibition



and inoculation phase and enhance phagocytosis of cellular immunity (Wood Jr, 1960; Saltz et al., 1989). Some of the multi donor human commercial fibrin glue for instant TISEEL™, (Baxter) contains 670-1060 mg/dl of fibrinogen, Evicel™ (Johnson and Johnson) contains 550-850 mg/dl of fibrinogen and Quixil™ (Johnson and Johnson) contains 400-600 mg/dl of fibrinogen (Food and Administration; Furst et al., 2007). These concentration of fibrinogen less than the concentration of bubaline fibrinogen, which was extracted from bubaline blood by cryoprecipitation and cryocentrifuged method which concentration was 1620 mg/dl. More fibrinogen concentration can have more significant efficacy on fibrin glue because the quality and tensile strength of fibrin scaffold were rely on source and concentration of fibrinogen (Hom, 2009). Although, in a study demonstrated that the concentration of fibrinogen cannot indicate the successfulness of the skin grafting better than the thin and thick of skin graft, which was described in 2000 by O'Grady et al. who compared low concentrations of fibrinogen (300mg/dl) and high concentration of fibrinogen (600mg/dl) (O'Grady et al., 2000). Nevertheless, the graft survival rate of bubaline fibrin glue group in this study can be indicated that the high fibrinogen concentration of bubaline fibrin glue related to the survival of the skin graft.

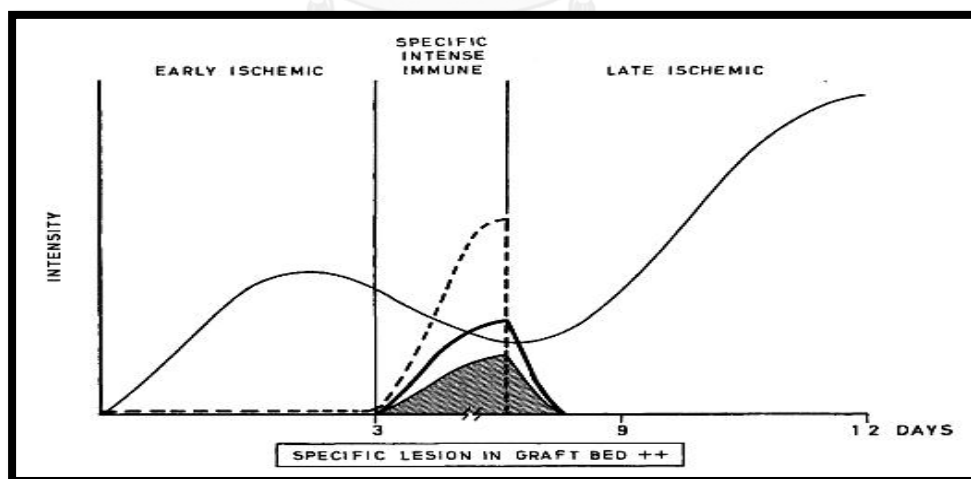
The bubaline fibrin glue may help graft surviving even the wounds were infected by two numerous bacterial species (*Klebsiella pneumoniae* and *Escherichia coli*) which were resisted to the antibiotic therapy (enrofloxacin). The infected graft which has more than  $10^5$  bacteria per gram of tissue was highly associated with graft failure, but fibrin glue may have the capability for increasing graft survival rate in *Staphylococcus aureus* infected situation in rats (Jabs Jr et al., 1992). In addition a study that represents the extravascular fibrinogen can stimulate macrophage chemokine secretion (MCP-1) from activated or differentiated human monocytes which may promote immunity at the infected area (Smiley et al., 2001). Not only the fibrin glue can protect the graft from infection by itself, but also the fibrin glue can deliver antibiotics to the site of infection which showed in several studies for example, in a study, sisomicin was consolidated to fibrin glue can promote the resistant of infected vascular grafts and in 2004 a study showed that fibrin glue as an amikacin carrier

prevented infection of polyurethane graft in subcutaneous (Yamamura et al., 1995; Nishimoto et al., 2004).

The accomplishment of graft remaining in bubaline fibrin glue applied group which was statistically significant difference from the control group on 3<sup>rd</sup> and 7<sup>th</sup> postoperative day ( $p < 0.05$ ) because it may benefit from its characteristics for instant, hemostasis, graft adhesion and antibacterial property (Currie et al., 2001). The fibrin glue can reduce hematoma and/or seroma because fibrin polymers help capturing platelets in the normal coagulation mechanism. The fibrin polymers connected between graft and bed reduce movement of graft that protect fragile connective tissues which are important structures for re-vascularization moreover, the fibrin glue can promote phagocytosis that against especially the bacteria which can release of the enzyme and/or inflammatory substances (Smiley et al., 2001). However, almost of the graft pieces were covered by overgranulation tissue on 14<sup>th</sup> post-operative day may because the wounds were in healing phase, which the granulation tissue was continuously produced. The granulation tissue naturally develop on the 4<sup>th</sup> through 12<sup>th</sup> post-operative day (Tobias and Johnston, 2013). Another possibility was the wounds were infected by a lot of bacteria that stimulate dermal granulation tissues producing because of the prolongation of inflammatory phase and proliferative phase of healing which were normally overlapping in time (Bailey et al., 1975; Clark, 1993a) Moreover, a hypothesis of overgranulation tissue origination was because over saturated interstitial tissue (edema) from leaking of fast growing of immature capillaries and excessive exudate absorption of the old bandages that bring about large amount of non-absorbable fluid volume remained between interstitial spaces (Vandeputte and Hoekstra, 2006).

From the result of graft rejection grading, it was found no (grade 0) or indeterminate (grade I) for rejection in both groups because the grafts were harvested from the same patient (autograft) that indicated slight graft rejection chance compared with the other graft types. However, the autograft can be rejected as a result of other factors for example; in 1973 Smith et al. reported autograft rejection in burn wound

which was infected by *Streptococcus agalactiae* and in 1969, Cochrum et al. reported autograft rejection in kidney by passive transfer of immune plasma (Cochrum et al., 1969; Smith et al., 1973). In this study, a minor observation with the inflammatory cells found that an increasing of the numbers of plasma cells and gradually decrease in the number of eosinophils in the control group on 14<sup>th</sup> post-operative day may predict the indeterminate delayed graft rejection. The graft rejection in human was described in three phases, early ischemic, specific intense immune and late ischemic (Figure 31.). The phase of specific intense immune occurs during 3<sup>rd</sup> to 9<sup>th</sup> post-operative day indicated by the presentation of eosinophils, lymphocytes, mononuclear cells and plasma cells after the white graft phenomenon, which was mild ischemic damage, nonspecific inflammation and collapse of capillaries (Zweifach et al., 2014). The delayed graft rejection was described in a study in 2015 that the less number of T-lymphocytes caused delayed graft rejection (Vågesjö et al., 2014). The delayed graft rejection may be related to healing time that the healing process in porcine may increase to 4-6 weeks relate to wound size and tissue damage (Middelkoop et al., 2004).



**Figure 31.** The picture represents the graft rejection phases which presented by three phases; early ischemic phase, specific intense immune phase and late ischemic phase which occurred within 12<sup>th</sup> post-operative day (Zweifach et al., 2014).

The source of fibrinogen from different species (the bubaline fibrinogen applied to the porcine skin graft) was not obviously seen a pathological evidence or tissue antagonism. There were several accomplish studies of using fibrinogen from the different species, for example the study of using human fibrinogen in canine periodontal flap surgery, intratemporal anastomosis of the facial nerve in felines by using human fibrin glue and the study of using human fibrinogen in cervical nerve root repairing in ovine without tissue rejection (Bento and Miniti, 1989; Hems and Glasby, 1992; Warrer and Karring, 1992).

From the study, the statistical significant difference of the high level of average new vessels of bubaline fibrin glue group compared with the control group on 3<sup>rd</sup> post-operative day ( $p < 0.05$ ), which related to the significant survival of grafts because a great number of new vessels not only provided nutrients but also transported the immune cells to the healing area. The angiogenesis play as an important mechanism of inosculation and vascular ingrowth phase that indicates the survival of grafts. The vessel maturation start within 48 hours after a first neovessel occurred under control by cytokines and the process will be completed by day 7<sup>th</sup> – 8<sup>th</sup> post-operative day (Tobias and Johnston, 2013). The fibrin glue demonstrates a promotion in neovascularization which was reported by Christman et al. They injected a commercial fibrin glue into infarcted myocardium then they found the fibrin glue not only preserve myoblast but also promote incoming of arteriole (Christman et al., 2004). In additional to the fibrin fragment E which was degraded from fibrin represents the promotion of propagation, emigration and transformation of human dermal vascular endothelial cell (Bootle-Wilbraham et al., 2001).

The number of fibroblasts, average inflammatory cells and collagen intensity were approximately in the line with the natural wound healing and no statistical significant difference between the bubaline fibrin glue group and the control group ( $p > 0.05$ ) except the intensity of the inflammatory on 7<sup>th</sup> post-operative day. Stages of healing of skin graft were described with some similarity to general wound healing. Fibroblasts, leukocytes and phagocytes begin migration to fibrin scaffold during first 72

hours post-grafting then, inflammatory cells were continuing decrease conversely to fibroblasts which produce collagen fibers during the healing process were increased to strengthen graft and bed until the reunion of fibrous by 10<sup>th</sup> post-operative day (Tobias and Johnston, 2013). Collagen fibers and fibroblasts were steadily continue accumulated in granulation tissues then transformed to scars and restore 20% of strength in three weeks (Epstein et al., 1999). The number of fibroblasts was not significant difference but from the graph, the number of fibroblasts in bubaline fibrin glue group was slightly more than control group on 3<sup>rd</sup> and 7<sup>th</sup> post-operative day that may lead to grafts survival especially in adherence phase of engraftment process. The significant difference of the intensity of inflammation on 7<sup>th</sup> day post-operative may be due to prolong inflammation indicated by the number of neutrophils in the control group.

#### **Comment**

The limitation of the study was shown by abundant of granulation tissue on the 14<sup>th</sup> post-operative day. The indication of pinch and punch skin graft in the patient was non or delay epithelialization wounds, which the epithelialization phase cannot naturally complete because of complications or the wound was too large. The study was done on the healthy pig, which was during the normal healing time and the skin grafting was needless. Moreover, the contamination of numerous bacteria indicated that the sterilization was not good enough and may lead to the failure of the study.



## REFERENCES



- Ardakani MR, Hormozi AK, Ardakani JR, Davarpanahjazi AH and Moghadam AS. 2012. Introduction of a potent single-donor fibrin glue for vascular anastomosis: An animal study. *Journal of research in medical sciences: the official journal of Isfahan University of Medical Sciences*. 17(5): 461.
- Bailey A, Sims T, Le Lous M and Bazin S. 1975. Collagen polymorphism in experimental granulation tissue. *Biochemical and biophysical research communications*. 66(4): 1160-1165.
- Bänninger H, Hardegger T, Tobler A, Barth A, Schupbach P, Reinhart W, Lammle B and Furlan M. 1993. Fibrin glue in surgery: frequent development of inhibitors of bovine thrombin and human factor V. *British journal of haematology*. 85(3): 528-532.
- Bejarano PA, Levi D, Nassiri M, Vincek V, Garcia M, Weppler D, Selvaggi G, Kato T and Tzakis A. 2004. The pathology of full-thickness cadaver skin transplant for large abdominal defects: a proposed grading system for skin allograft acute rejection. *The American journal of surgical pathology*. 28(5): 670-675.
- Bento RF and Miniti A. 1989. Comparison between Fibrin Tissue Adhesive, Epineural Suture and Natural Union in Intratemporal Facial Nerve of Cats: Part I. *Acta Otolaryngologica*. 108(S465): 1-18.
- Bergel S. 1909. Ueber wirkungen des fibrins. *DMW-Deutsche Medizinische Wochenschrift*. 35(15): 663-665.
- Berruyer M, Amiral J, Ffrench P, Belleville J, Bastien O, Clerc J, Kassir A, Estanove S and Dechavanne M. 1993. Immunization by bovine thrombin used with fibrin glue during cardiovascular operations. Development of thrombin and factor V inhibitors. *The Journal of thoracic and cardiovascular surgery*. 105(5): 892-897.
- Birch J, Brånemark P-I and Lundskog J. 1969. The vascularization of a free full thickness skin graft: II. A microangiographic study. *Scandinavian Journal of Plastic and Reconstructive Surgery and Hand Surgery*. 3(1): 11-17.
- Bootle-Wilbraham C, Tazzyman S, Thompson W, Stirk C and Lewis C. 2001. Fibrin fragment E stimulates the proliferation, migration and differentiation of human microvascular endothelial cells in vitro. *Angiogenesis*. 4(4): 269-275.



- Branski LK, Mittermayr R, Herndon DN, Jeschke MG, Hofmann M, Masters OE, Norbury WB, Traber DL, Tangl S and Redl H. 2011. Fibrin sealant improves graft adherence in a porcine full-thickness burn wound model. *Burns : journal of the International Society for Burn Injuries*. 37(8): 1360-1366.
- Chalhoub M, Prestes N, Lopes M, Rocha N, Thomazini-Santos I and Mendes-Giannini M. 2000. The use of snake venom derived fibrin glue in hysterorrhaphy of ovine caesarean surgery. *Journal of Venomous Animals and Toxins*. 6(2): 220-237.
- Choi B-H, Zhu S-J, Jung J-H, Lee S-H and Huh J-Y. 2006. The use of autologous fibrin glue for closing sinus membrane perforations during sinus lifts. *Oral Surgery, Oral Medicine, Oral Pathology, Oral Radiology, and Endodontology*. 101(2): 150-154.
- Christman KL, Vardanian AJ, Fang Q, Sievers RE, Fok HH and Lee RJ. 2004. Injectable fibrin scaffold improves cell transplant survival, reduces infarct expansion, and induces neovasculature formation in ischemic myocardium. *Journal of the American College of Cardiology*. 44(3): 654-660.
- Chung W, Kazemi P, Ko D, Sun C, Brown CJ, Raval M and Phang T. 2009. Anal fistula plug and fibrin glue versus conventional treatment in repair of complex anal fistulas. *The American Journal of Surgery*. 197(5): 604-608.
- Clark RA. 1990. Fibronectin matrix deposition and fibronectin receptor expression in healing and normal skin. *Journal of Investigative Dermatology*. 94: 128s-134s.
- Clark RA. 1993a. Biology of dermal wound repair. *Dermatologic clinics*. 11(4): 647-666.
- Clark RA. 1993b. Regulation of fibroplasia in cutaneous wound repair. *The American journal of the medical sciences*. 306(1): 42-48.
- Cochrum K, Davis W, Kountz S and Fudenberg H. 1969. Renal autograft rejection initiated by passive transfer of immune plasma. *Transplantation proceedings*:301-304.
- Converse J, Ballantyne Jr D, Rogers B and Raisbeck A. 1957. Plasmatic circulation in skin grafts. *Transplantation bulletin*. 4(4): 154.
- Converse JM. 1977. *Reconstructive plastic surgery: principles and procedures in correction, reconstruction, and transplantation*. Vol. 1. In: Saunders.

- Converse JM, Smahel J, Ballantyne DL and Harper AD. 1975. Inosculation of vessels of skin graft and host bed: a fortuitous encounter. *British journal of plastic surgery*. 28(4): 274-282.
- Cronkite EP, Lozner EL and Deaver JM. 1944. Use of Thrombin and Fibrinogen in Skin Grafting: Preliminary Report. *Journal of the American Medical Association*. 124(14): 976-978.
- Currie LJ, Sharpe JR and Martin R. 2001. The use of fibrin glue in skin grafts and tissue-engineered skin replacements. *Plastic and reconstructive surgery*. 108: 1713-1726.
- Davis JS and Traut HF. 1925. Origin and development of the blood supply of whole-thickness skin grafts: an experimental study. *Annals of surgery*. 82(6): 871.
- Dresdale A, Rose E, Jeevanandam V, Reemtsma K, Bowman F and Malm J. 1985. Preparation of fibrin glue from single-donor fresh-frozen plasma. *Surgery*. 97(6): 750-755.
- Dunn CJ and Goa KL. 1999. Fibrin sealant. *Drugs*. 58(5): 863-886.
- Epstein FH, Singer AJ and Clark RA. 1999. Cutaneous wound healing. *New England journal of medicine*. 341(10): 738-746.
- Fang P, Ding R and Kong L. 1997. [The changes of fibrinolysis in plasma and wounds in rats inflicted with deep partial thickness burns]. *Zhonghua zheng xing shao shang wai ke za zhi= Zhonghua zheng xing shao shang waikf [ie waike] zazhi= Chinese journal of plastic surgery and burns/[Chung-hua cheng hsing shao shang wai k'o tsa chih pien chi wei yuan hui pien chi]*. 13(4): 259-263.
- Food U and Administration D. Highlights of Prescribing Information. TISSEEL [Fibrin Sealant].
- Fortelny R, Schwab R, Glaser K, Puchner K, May C, König F, Redl H and Petter-Puchner A. 2008. The assessment of quality of life in a trial on lightweight mesh fixation with fibrin sealant in transabdominal preperitoneal hernia repair. *Hernia : the journal of hernias and abdominal wall surgery*. 12(5): 499-505.
- Furst W, Banerjee A and Redl H. 2007. Comparison of structure, strength and cytocompatibility of a fibrin matrix supplemented either with tranexamic acid

- or aprotinin. *Journal of Biomedical Materials Research Part B: Applied Biomaterials*. 82(1): 109-114.
- Gerber SB and Finn KV. 2005. *Using SPSS for Windows: Data analysis and graphics*. In: Springer Science & Business Media.
- Grabb W and Smith J. 1991. Reconstruction of the eyelids and eyebrows and correction of ptosis of the eyelid. *Plastic surgery*, 4th ed. Boston: Little, Brown. 425-462.
- Hems T and Glasby M. 1992. Repair of cervical nerve roots proximal to the root ganglia. An experimental study in sheep. *Journal of Bone & Joint Surgery, British Volume*. 74(6): 918-922.
- Henrikson H, Jensen-Waern M and Nyman G. 1994. Anaesthetics for general anaesthesia in growing pigs. *Acta Veterinaria Scandinavica*. 36(4): 401-411.
- Hile J. 1978. Fibrinogen (human): revocation of licenses. *Fed Regist*. 43: 1131-1132.
- Hom DB. 2009. Essential tissue healing of the face and neck. In: PMPH-USA.
- Hsieh P and Chen LB. 1983. Behavior of cells seeded in isolated fibronectin matrices. *The Journal of cell biology*. 96(5): 1208-1217.
- Ihara N, Suzuki K, Tanaka H, Nakamura Y, Tanabe J, Fukuda A, Fujii C, Kohama A, Hamanaka T and Tani T. 1984. Application of fibrin glue to burns: Its haemostatic and skin transplant fixation effects in the excised wound. *Burns : journal of the International Society for Burn Injuries*. 10(6): 396-404.
- Israels SJ and Israels ED. 1994. Development of antibodies to bovine and human factor V in two children after exposure to topical bovine thrombin. *Journal of Pediatric Hematology/Oncology*. 16(3): 249-254.
- Jabs Jr AD, Wider TM, DeBellis J and Hugo NE. 1992. The effect of fibrin glue on skin grafts in infected sites. *Plastic and reconstructive surgery*. 89(2): 268-271.
- Jathal B, Trivedi A and Bhavsar N. 2008. Use of fibrin glue in periodontal flap surgery. *Journal of Indian Society of Periodontology*. 12(1): 21.
- Joch C. 2003. The safety of fibrin sealants. *Cardiovascular surgery*. 11: 23-28.
- Kelton Jr PL. 1999. Skin grafts and skin substitutes. *Selected Readings in Plastic Surgery*. 9(1): 1-24.

- Laplante AF, Germain L, Auger FA and Moulin V. 2001. Mechanisms of wound reepithelialization: hints from a tissue-engineered reconstructed skin to long-standing questions. *The FASEB Journal*. 15(13): 2377-2389.
- Leite C, Naresse L, Arantes H, Lopes A, Thomazini-Santos I, Giannini M, Mercadante M, Barraviera B and Kobayasi S. 2000. An evaluation by rat colon anastomosis of the efficacy of fibrin glue derived from snake venom. *Journal of Venomous Animals and Toxins*. 6(2): 180-193.
- Leroy-Matheron C, Mallat A, Duvoux C, Métreau JM, Cherqui D, Dhumeaux D and Gouault-Heilmann M. 1999. Inhibitor against coagulation factor V after liver transplantation: Possible role of the FK506 immunosuppressive drug. *Transplantation*. 68(7): 1054-1056.
- Martinowitz U and Spotnitz W. 1997. Fibrin tissue adhesives. *Thrombosis and haemostasis*. 78(1): 661-666.
- Matsuka YV, Migliorini MM and Ingham KC. 1997. Cross-linking of fibronectin to C-terminal fragments of the fibrinogen  $\alpha$ -chain by factor XIIIa. *Journal of protein chemistry*. 16(8): 739-745.
- McGill V, Kowal-Vern A, Lee M, Greenhalgh D, Gomperts E, Bray G and Gamelli R. 1997. Use of fibrin sealant in thermal injury. *Journal of Burn Care & Research*. 18(5): 429-434.
- Middelkoop E, Van Den Bogaerdt A, Lamme E, Hoekstra M, Brandsma K and Ulrich M. 2004. Porcine wound models for skin substitution and burn treatment. *Biomaterials*. 25(9): 1559-1567.
- Mintz PD, Mayers L, Avery N, Flanagan HL, Burks SG and Spotnitz WD. 2001. Fibrin sealant: clinical use and the development of the University of Virginia Tissue Adhesive Center. *Annals of Clinical & Laboratory Science*. 31(1): 108-118.
- Mobley SR, Hilinski J and Toriumi DM. 2002. Surgical tissue adhesives. *Facial plastic surgery clinics of North America*. 10(2): 147-154.
- Nishimoto K, Yamamura K, Fukase F, Kobayashi M, Nishikimi N and Komori K. 2004. Subcutaneous tissue release of amikacin from a fibrin glue/polyurethane graft. *Journal of infection and chemotherapy*. 10(2): 101-104.

- O'Grady KM, Agrawal A, Bhattacharyya TK, Shah A and Toriumi DM. 2000. An evaluation of fibrin tissue adhesive concentration and application thickness on skin graft survival. *The Laryngoscope*. 110(11): 1931-1935.
- Park HC, Champakalakshmi R, Panengad PP, Raghunath M and Mehta JS. 2011. Tissue adhesives in ocular surgery.
- Pavletic MM. 2011. Atlas of small animal wound management and reconstructive surgery. In: John Wiley & Sons.
- Pinna BdR, Stavale JN, Pontes PAdL and Brasil OdoCd. 2011. Histological analysis of autologous fascia graft implantation into the rabbit voice muscle. *Brazilian journal of otorhinolaryngology*. 77(2): 185-190.
- Pope E. 1988. Skin grafting in small animal surgery. I. The normal healing process. *The Compendium on continuing education for the practicing veterinarian (USA)*.
- Radosevich M, Goubran H and Burnouf T. 1997. Fibrin sealant: scientific rationale, production methods, properties, and current clinical use. *Vox sanguinis*. 72(3): 133-143.
- Ruggiero R, Procaccini E, Gili S, Cremone C, Docimo G, Decimo G, Iovino F, Docimo L, Decimo L and Sparavigna L. 2008. Fibrin glue to reduce seroma after axillary lymphadenectomy for breast cancer. *Minerva chirurgica*. 63(3): 249-254.
- Saltz R, Dimick A, Harris C, Grotting JC, Psillakis J and Vasconez LO. 1989. Application of autologous fibrin glue in burn wounds. *Journal of Burn Care & Research*. 10(6): 504-507.
- Saltz R, Sierra D, Feldman D, Saltz MB, Dimick A and Vasconez LO. 1991. Experimental and clinical applications of fibrin glue. *Plastic and reconstructive surgery*. 88(6): 1005-1015.
- Saxena S, Jain P and Shukla J. 2003. Preparation of two component Fibrin Glue and its clinical evaluation in skin grafts and flaps.
- Sierra DH, Feldman DS, Saltz R and Huang S. 1992. A method to determine shear adhesive strength of fibrin sealants. *Journal of Applied Biomaterials*. 3(2): 147-151.
- Simo K, Hanna E, Imagawa D and Iannitti D. 2012. Hemostatic agents in hepatobiliary and pancreas surgery: a review of the literature and critical evaluation of a

- novel carrier-bound fibrin sealant (TachoSil). *International Scholarly Research Notices*. 2012.
- Smiley ST, King JA and Hancock WW. 2001. Fibrinogen stimulates macrophage chemokine secretion through toll-like receptor 4. *The Journal of Immunology*. 167(5): 2887-2894.
- Smith RF, Dayton SL and Chipps DD. 1973. Autograft rejection in acutely burned patients: relation to colonization by *Streptococcus agalactiae*. *Applied microbiology*. 25(3): 493-495.
- Spotnitz WD. 2010. Fibrin sealant: past, present, and future: a brief review. *World journal of surgery*. 34(4): 632-634.
- Spotnitz WD and Burks S. 2008. Hemostats, sealants, and adhesives: components of the surgical toolbox. *Transfusion*. 48(7): 1502-1516.
- Stuart J, Morgan RF and Kenney JG. 1990. Single-donor fibrin glue for hand burns. *Annals of plastic surgery*. 24(6): 524-527.
- Sullivan TP, Eaglstein WH, Davis SC and Mertz P. 2001. The pig as a model for human wound healing. *Wound repair and regeneration*. 9(2): 66-76.
- Swaim SF. 1980. Surgery of traumatized skin: management and reconstruction in the dog and cat. In: WB Saunders.
- Swaim SF. 1990. Skin grafts. *The Veterinary clinics of North America. Small animal practice*. 20(1): 147-175.
- Swindle MM. 2007. Swine in the laboratory: surgery, anesthesia, imaging, and experimental techniques. In: CRC Press.
- Tavis MJ, Thornton JW, Harney JH, Woodroof EA and Bartlett RH. 1976. Graft adherence to de-epithelialized surfaces: a comparative study. *Annals of surgery*. 184(5): 594.
- Teh BT. 1979. Why Do Skin Grafts Fail? *Plastic and reconstructive surgery*. 63(3): 323-332.
- Thomazini-Santos I, Giannini M, Toscano E, Machado P, Lima C and Barraviera B. 1998. The evaluation of clotting time in bovine thrombin, Reptilase®, and thrombin-like fraction of *Crotalus durissus terrificus* venom using bovine, equine, ovine,

- bubaline and human cryprecipitates. *Journal of Venomous Animals and Toxins*. 4(2): 120-136.
- Thorn J, Sørensen H, Weis-Fogh U and Andersen M. 2004. Autologous fibrin glue with growth factors in reconstructive maxillofacial surgery. *International journal of oral and maxillofacial surgery*. 33(1): 95-100.
- Tidrick R and Warner E. 1944. Fibrin fixation of skin transplants. *Surgery*. 15(Jan.): 90.
- Tobias KM and Johnston SA. 2013. *Veterinary Surgery: Small Animal: 2-Volume Set*. In: Elsevier Health Sciences.
- Toda K-I, Tuan T-L, Brown PJ and Grinnell F. 1987. Fibronectin receptors of human keratinocytes and their expression during cell culture. *The Journal of cell biology*. 105(6): 3097-3104.
- Ünal S, Ersoz G, Demirkan F, Arslan E, Tütüncü N and Sari A. 2005. Analysis of skin-graft loss due to infection: infection-related graft loss. *Annals of plastic surgery*. 55(1): 102-106.
- Uriyapongson S. 2013. Buffalo and Buffalo Meat in Thailand. *Buffalo Bulletin*. 32: 329-332.
- Vågesjö E, Christoffersson G, Waldén TB, Carlsson P-O, Essand M, Korsgren O and Phillipson M. 2014. Immunological shielding by induced recruitment of regulatory T lymphocytes delays rejection of islets transplanted to muscle. *Cell transplantation*.
- Vaiman M, Eviatar E and Segal S. 2002. The use of fibrin glue as hemostatic in endonasal operations: a prospective, randomized study. *Rhinology*. 40(4): 185-188.
- Vajkoczy P, Menger MD, Simpson E and Messmer K. 1995. Angiogenesis and vascularization of murine pancreatic islet isografts. *Transplantation*. 60(2): 123-126.
- Vandeputte J and Hoekstra H. 2006. Observed hypergranulation may be related to oedema of granulation tissue.
- Vedung S and Hedlund A. 1993. Fibrin glue: its use for skin grafting of contaminated burn wounds in areas difficult to immobilize. *Journal of Burn Care & Research*. 14(3): 356-358.

- Vibe P and Pless J. 1983. A new method of skin graft adhesion. *Scandinavian Journal of Plastic and Reconstructive Surgery and Hand Surgery*. 17(3): 263-264.
- Viterbo F, Iuan F, Thomazini I, Mendes-giannini M, Ferrari N, Palhares A, Barraviera B and Rosa G. 1994. Reparação de nervo periférico com cola de fibrina feita com veneno de cobra e fibrinogênio de búfalo, cavalo, boi e humano. Trabalho experimental em ratos. Congresso sobre cirurgia experimental relacionado a cirurgia plastica
- Warrer K and Karring T. 1992. Effect of Tisseel® on healing after periodontal flap surgery. *Journal of clinical periodontology*. 19(7): 449-454.
- Werner S, Krieg T and Smola H. 2007. Keratinocyte–fibroblast interactions in wound healing. *Journal of Investigative Dermatology*. 127(5): 998-1008.
- Wood Jr WB. 1960. Phagocytosis, with particular reference to encapsulated bacteria. *Bacteriological reviews*. 24(1): 41.
- Yamamura K, Sakurai T, Yano K, Osada T and Nabeshima T. 1995. Prevention of vascular graft infection by sisomicin incorporated into fibrin glue. *Microbiology and immunology*. 39(11): 895-896.
- Young J and Medawar P. 1940. Fibrin suture of peripheral nerves: measurement of the rate of regeneration. *The Lancet*. 236(6101): 126-128.
- Zehnder JL and Leung LL. 1990. Development of antibodies to thrombin and factor V with recurrent bleeding in a patient exposed to topical bovine thrombin. *Blood*. 76(10): 2011-2016.
- Zweifach BW, Grant L and McCluskey RT. 2014. The inflammatory process. In: Academic Press.



APPENDIX



## VITA

Krittee Dejyong born in July, 19 1985 in Bangkok, Thailand. He is the elder brother of Dejyong's family. In April 2009, he graduated bachelor degree in Veterinary Science with second class honor from Faculty of Veterinary, Chulalongkorn University, and then he worked as a veterinarian at Sriwara Animal Hospital, Bangkok, Thailand. In 2013, he began to study in the master degree of veterinary surgery, Faculty of Veterinary Science, Chulalongkorn University. Currently, he is studying accompany to work as a part-time veterinarian at Sriwara Animal Hospital, Bangkok, Thailand.



