

CHAPTER V

DISCUSSION AND CONCLUSION

The purpose of this study was to investigate the wound healing effects of the extracts from *Centella asiatica* (CA) on healing of incision wound and burn wound. The results of this study showed that the extracts from CA could facilitate the wound healing process during the experimental period of seven and fourteen days in both incision wound and second-degree burn wound. The results agreed with those which previously claimed that CA could facilitate wound healing.

1. Effects of *Centella asiatica* on incision wound

In this study, four different extracts from CA, hexane, ethyl acetate, methanol and water extracts, were applied for treatment of wound on the skin of rats *in vivo*. The tensile strength was tested on day 7 post wounding. The tensile strength of all animals in the extract-treated groups was significantly increased compared to those in Tween 20-treated group (Table 4.1, Figure 4.5). The present finding is in accordance with those of previous studies reporting that crude ethanolic extract from CA increased the tensile strength in incision wound by increasing collagen concentration and stabilization of the fibres (Suguna et al., 1996; Sunikumar et al., 1998). Asiaticoside isolated from CA revealed wound healing activity by increasing tensile strength and collagen content (Shukla et al., 1999). Furthermore, triterpenoids obtained from CA increased the collagen synthesis both *in vivo* (Maquart et al., 1999) and *in vitro* (Bonte et al., 1994). According to TLC technique it was shown that ethyl acetate and methanol extract were composed of triterpenoid: asiatic acid and asiaticoside, respectively (Figures 4.2, 4.3). It is well known that collagen is the major protein component of wound connective tissue and the chemical composition of collagen is responsible for its biological function of being the bonding component which hold tissues together and serve the strength for wound (Icono et al., 1998). Thus, the healing activity of the extracts from CA characterized by increased tensile strength of incision wound may be due to an increase in collagen synthesis.

Interestingly, the result of present study demonstrated that the tensile strength of the animals in NSS-treated group was not significantly different from those in the extract-treated

groups (Table 4.1). This result might be explained that NSS, the most commonly used solution in clinical practice for wound irrigation, preserves physiological condition and does not contain any surfactants. In 1994, Kerstein described that moisture could help wound healing by facilitating recruitment of vital host defenses and the necessary cell population, such as the macrophage, that can promote wound healing. Similar result was found by Ladin (1998) who showed that the wound which kept moist could heal better than those exposed to the air. Furthermore, the incision causes death of a limited number of epithelial cells and connective tissue cells as well as disruption of epithelial basement membrane continuity (Cotran et al., 1994). Most incised wound can be closed within 6-12 hours providing that they are not contaminated (Leaper and Gottrup, 1998). Thus, those previous finding may explain the results that healing activity of the extracts from CA was comparable to NSS.

2. Effects of *Centella asiatica* on burn wound

Loss of cells and tissues in the burn wound was more extensive than those in incision wound. The reparative process namely healing by second intention is more complicated than incision wound (Cotran et al., 1994).

Efficacy of CA extracts on burn wound was assessed by gross pathology evaluation (wound lesion and degree of wound healing) as well as histopathological observation. The gross wound lesions and degree of wound healing were evaluated on day 3, 7, 10 and 14 post burning. On day 3 post burning, all wounds in untreated, NSS- and Tween 20-treated groups became swelling and bruised (Figure 4.6A-C) and degree of wound healing among these groups were not significantly different (Figure 4.10). It is indicated that all wounds in the first phase of wound healing process are during inflammatory phase. In contrast, most wounds in the extract-treated groups showed mild swelling and dry wound surface (Figure 4.6D-G). This indicated that the extract from CA could reduce inflammatory process by its anti-inflammatory activity (Chen et al., 1999; Somchit et al., 2004). These findings are supported by previous study that CA glycoside revealed vasodilating effect, which increase blood flow to wound site, thus promoting healing of wound (Dhorranintra and Sangsirinavin, 1982). In addition, most wounds in the extract treated groups began slightly contracting from the wound edge (Figure 4.6D-G). Similar results were found with regards to degree of wound healing. The degree of wound healing in ethyl acetate-treated group was significantly higher than those in Tween 20-treated group (Figure 4.10, Table 4.2), which indicated that the extract from CA could facilitate collagen synthesis (Bonte et al.,

1993; Maquart et al., 1999; Lu et al., 2004) and accelerated the healing process to the second phase, the proliferative phase.

On day 7 post burning, all wounds in untreated, NSS- and Tween 20- treated groups showed dark red color and the wound sizes remain as it was at the beginning (Figure 4.7A-C). The degree of wound healing among these groups were not significantly different (Table 4.2), which indicated that all wounds were progressively inflamed and delayed to enter to the second phase of wound healing. Most of wounds treated with the extract showed wound contraction, smaller in size and hair growth appeared. These results indicated that all wounds in extract-treated groups were in the second phase of wound healing process, proliferative phase. Similar results were observed in the degree of wound healing of ethyl acetate-treated group which was higher than those in Tween 20-treated group (Figure 4.11, Table 4.2). TLC technique showed that asiatic acid was the constituent in ethyl acetate extract (Figure 4.2). Many reports showed that asiatic acid could increase collagen synthesis which is important in healing process (Bonte et al, 1993; Maquart et al., 1999). Therefore, it was possible that the ethyl acetate extract promoted the wound healing process by increasing collagen synthesis.

On day 10 post burning, all wounds in untreated, NSS- and Tween 20- treated groups showed moderate exudation. No hair growth. Wound surface was covered by scab (Figure 4.8A-C). The degree of wound healing among these groups were not significantly different (Table 4.2). These finding indicated that all wounds were delayed in the healing process. In contrast, all wounds in the extract-treated groups showed dry wound surface, progressive wound contraction and reduction in wound sizes, and increased hair growth (Figure 4.8D-G), indicating that healing process of all wounds continuously progressed. The degree of wound healing in hexane and ethyl acetate extract-treated groups were significantly higher than those in Tween 20-treated group (Figure 4.12, Table 4.2). TLC technique showed that hexane extract contained β -sitosterol (Figure 4.1) and ethyl acetate extract contained asiatic acid (Figure 4.2) as described above. Some studies reported that β -sitosterol showed a potent angiogenic activity, which is essential for wound healing (Moon et al., 1999; Choi et al., 2002). Thus, healing activity of hexane extract may be partly due to angiogenic activity.

On day 14 post burning, at the end of the experiment, histopathological evaluation was performed. All wounds in untreated, NSS- and Tween 20-treated groups showed moderate exudation and scabs started separating from the wound surface. The wound sizes were slightly decreased compared to the beginning (Figure 4.9A-C). The degree of wound healing among these

groups was not significantly different (Table 4.2). Upon histopathological observation, the untreated group showed prominent fibrinoid necrosis, incomplete epithelialization, less skin appendages, and exudates covering the wound surface (Figure 4.14B). The wounds in NSS- and Tween 20-treated groups were similar to those found in untreated group. Moreover, the wound treated with Tween 20 demonstrated generalized edema (Figure 4.14D). These results indicated that all wounds in these groups were still in the second phase of wound healing process, proliferative phase, indicating a delay in wound healing. The wounds in the extract-treated groups showed remarkable decrease in wound size and continuous growth of the hair at the wound site (Figure 4.9D-G). The degree of wound healing in all extract-treated groups was significantly higher than those in Tween 20-treated group (Figure 4.13, Table 4.2). In histopathological observation, the wound in all extract-treated groups showed fully developed epithelialization, keratinization and skin appendages can be observed (Figure 4.15B-E). These findings indicated that the extract could accelerate wound healing and promote wound healing process. The results of the present study offer a support for the notion that CA could promote the wound healing by inducing collagen synthesis (Bonte et al., 1993; Suguna et al., 1996; Sunikumar et al., 1998; Maquart, et al., 1999; Shukla et al., 1999; Lu et al., 2004), and promoting angiogenesis which was an important part of the wound healing (Cheng et al., 2004). Furthermore, the extract may possess inhibitory effect on inflammation, which may also contribute to the enhancement of wound healing (Chen et al., 1999; Cheng et al., 2004; Somchit et al., 2004).

The observation that the healing activity of each extract from CA in incision wound was comparable to NSS could be accounted by the fact that incision wound had minimal cell loss and tissue injury could be closed within 6-12 hours if they were not contaminated (Leaper and Gottrup, 1998). In burn wound, the hexane and ethyl acetate extract showed wound healing activity on day 3 and 10 of the experiments indicating that active components from these fractions might act in early stage of wound healing process: inflammatory and proliferative phase. These findings were supported by the studies of Chen et al. (1999) and Somchit et al. (2004) which indicated that the extract from CA could reduce inflammatory process by its anti-inflammatory activity. Previous study revealed that CA glycoside exerted vasodilating effect, resulting in an increase in blood flow to wound site and promotion of wound healing (Dhorranintra and Sangsirinavin, 1982). The finding that activity of methanol and water extract were observed in day 14 of the experiment suggested that active components from these fractions might be active in the late stage of wound healing process, the proliferative and remodeling phase. In proliferative

phase, the formation of granulation tissue in the wound was beginning. Collagen and revascularization which play the major roles (Regan and Barbul, 2000) could be facilitated by asiaticoside and β -sitosterol contained in methanol and hexane extracts, respectively. Though by TLC technique there was no compound found in water extract, the wound healing activity of this extract was also demonstrated on day 14 of the experiment. It could be possible that there were some other ingredients in water extract which could not be determined by TLC technique and might be active in the late stage of wound healing process. Although TLC is the most widely used method to find out any substances because of its simplicity of performance, it still has limited ability to detect some substances which could not be separated. The overall results from this study offer a proposed mechanism of actions of CA extracts during the phases of burn wound healing as shown in figure 4.16.

Besides those findings mentioned, growth factors are interesting to bring into the explanation of wound healing activity of CA extracts. As we know, growth factors are biological substances that exert their influence by stimulating cellular growth and proliferation. In an ideal wound healing situation, new tissue growth would replace damaged tissue resulting from a wound with no functional or cosmetic impairment. In other words, the newly grown tissue would work as well as the previous tissue that was damaged. The wound healing activity of CA extracts might be related with these growth factors like EGF, FGF-10, and VEGF. Thus, it is suggested for further study on the effects of CA extracts on growth factors in order to clarify the mechanism of CA extracts action on wound healing. Furthermore, microcirculatory studies are also suggested to investigate the antiinflammatory activity of ethyl acetate extract of CA which was revealed during the early phase of burn wound healing.

In conclusion, the present studies demonstrate wound healing effect of CA extracts in both incision and burn wounds. Though all types of extraction tested (HE, EE, ME and WE) exerted wound healing activity, it was apparent that asiatic acid which was the major component in EE seemed to be the most active compound in wound healing. In the future, it might be beneficial to do further investigation for its mechanism and active ingredients of each extract using other more sensitive techniques.

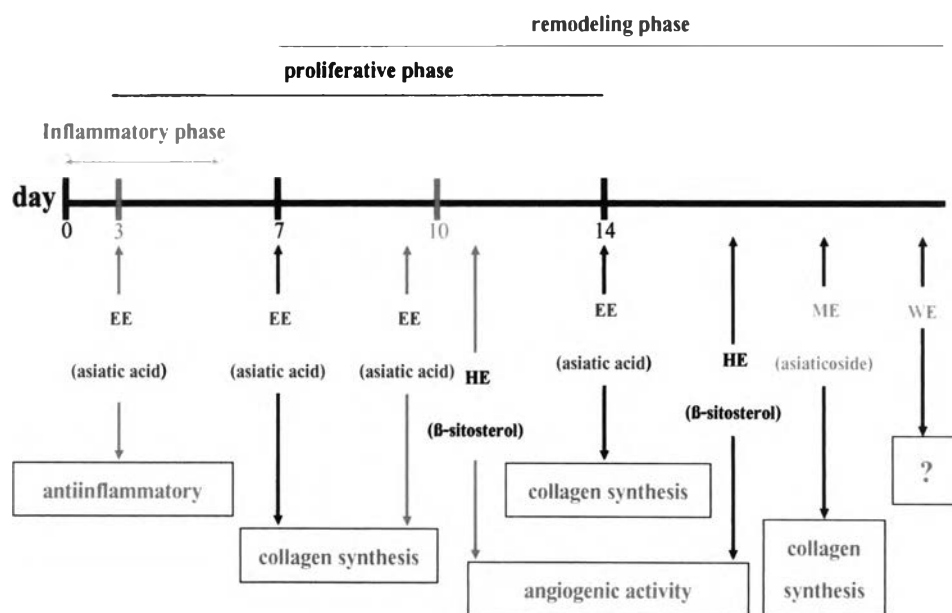


Figure 4.16 Proposed mechanism of action of CA extracts during the phases of burn wound healing.